Clinical Evaluation of a Novel Combination of Sodium Hypochlorite/Amino Acid and Cross-linked Hyaluronic Acid Adjunctive to Non-surgical Periodontal Treatment: A Case Series

Egle Ramanauskaite[a] / Vita Machiulskiene[b] / Urte Marija Dvyliene[c] / Meizi Eliezer[d] / Anton Sculean[e]

Purpose: The adjunctive subgingival application of sodium hypochlorite/amino acid and a mixture of natural and cross-linked hyaluronic acid gels (high molecular weight) has been recently proposed as a novel modality to enhance the outcomes of non-surgical periodontal therapy. The aim of this prospective case series was to evaluate the clinical outcomes obtained following the subgingival application of a combination of sodium hypochlorite/amino acid and a mixture of natural and cross-linked hyaluronic acid (high molecular) gels in conjunction with non-surgical periodontal therapy.

Material and Methods: Twenty-one systemically healthy, non-smoking patients diagnosed with stage II-III, grade A/B periodontitis underwent full-mouth subgingival debridement (SD) performed with ultrasonic and hand instruments. All sites with probing depths (PD) ≥ 4 mm were treated with additional repeated (i.e., 2-3 times) instillation of sodium hypochlorite/amino acid gel in the periodontal pockets prior to and during SRP. Following mechanical debridement, a mixture of natural and cross-linked hyaluronic acid (high molecular) gel was applied in the pockets. The primary outcome variable was PD reduction; changes in clinical attachment level (CAL) and bleeding on probing (BOP) were the secondary outcomes. The clinical parameters were assessed at baseline, 3 and 6 months after therapy.

Results: Compared to baseline, a statistically significant mean reduction of PD values was obtained after 3 and 6 months, amounting to 2.6 ± 0.4 mm, and 2.9 ± 0.4 mm, respectively ($p < 0.001$). Mean CAL gain measured 2.3 ± 0.5 mm at 3 months and 2.6 ± 0.5 mm at 6 months in comparison to baseline ($p < 0.001$). Mean reduction of BOP values was 54.9 ± 16.9 % at 3 months and 65.6 ± 16.4 % at 6 months ($p < 0.001$). The number of moderate pockets (4-5 mm) decreased from 1808 at baseline to 274 at the 6-month evaluation, and the number of deep (≥ 6 mm) pockets dropped from 319 to 3, respectively.

Conclusion: The combination of sodium hypochlorite/amino acid and a mixture of natural and cross-linked hyaluronic acid (high molecular) adjunctive to subgingival debridement may represent a valuable approach to improve the outcomes of non-surgical periodontal treatment.

Key words: cross-linked hyaluronic acid, non-surgical periodontal therapy, periodontitis, sodium hypochlorite/amino acid.

Oral Health Prev Dent 2023; 21: 279–284.
doi: 10.3290/j.ohpd.b4347453

Submitted for publication: 13.03.23; accepted for publication: 14.07.23

[a] *PhD Student, Clinic of Dental and Oral Pathology, Lithuanian University of Health Sciences, Kaunas, Lithuania. Study design, data acquisition and interpretation, manuscript drafting and revision, gave final approval and agreed to be accountable for all aspects of the work.*

[b] *Professor, Clinic of Dental and Oral Pathology, Lithuanian University of Health Sciences, Kaunas, Lithuania. Manuscript drafting and revision, gave final approval and agreed to be accountable for all aspects of the work.*

[c] *Periodontist, Clinic of Dental and Oral Pathology, Lithuanian University of Health Sciences, Kaunas, Lithuania. Manuscript revision, gave final approval and agreed to be accountable for all aspects of the work.*

[d] *Periodontist, Tel Aviv University, Tel Aviv, Israel. Manuscript drafting and revision, gave final approval and agreed to be accountable for all aspects of the work.*

[e] *Professor, Department of Periodontology, University of Bern, Switzerland. Study conception, design and supervision, data interpretation, manuscript drafting and revision.*

Correspondence: *Egle Ramanauskaite, Clinic of Dental and Oral Pathology, Lithuanian University of Health Sciences, Eiveniu 2, 50103, Kaunas, Lithuania. Tel: +370-6714-9632; e-mail: egle.ramanauskaite@lsmuni.lt*

Periodontitis is a chronic, progressive disease, characterised by expansion of the polymicrobial biofilm at the gingival margin, with the formation of an inflammatory infiltrate that contributes to destruction of connective-tissue attachment to the tooth, alveolar bone resorption and eventually even tooth loss.[1,2,27]

Dental plaque biofilm represents an acquired tissue of bacterial origin that maintains the health of gingival tissues and facilitates interactions between microorganisms and the host.[4,10] In periodontitis, a disruption of the normal function of the healthy subgingival plaque biofilm is observed, with concomitant disruption of its functional properties, leading to excessive, deregulated inflammation and tissue destruction.[4,13]

Elimination of the biofilm is a key element for the successful treatment of periodontitis. Although thorough subgingival debridement is a cornerstone of periodontal therapy, its effective-

ness may be limited by several factors (e.g., deep periodontal pockets, intrabony defects, furcation involvement, operator's manual skills, the patient's smoking status, etc.). Therefore, the adjunctive application of antimicrobial chemotherapeutic agents to eliminate or inactivate the periodontal pathogenic microflora at sites where mechanical instrumentation is cumbersome is highly clinically relevant.[22]

It has been suggested that adjunctive aids may enhance the outcomes of mechanical debridement.[22,24,28] Recently, the novel concept of 'Clean and Seal' – based on adjunctive use of two components, i.e., sodium hypochlorite/amino acid (Perisolv, Regedent; Zürich, Switzerland) and a mixture of natural and cross-linked hyaluronic acid (high molecular) (Hyadent BG, Regedent) gels along with mechanical instrumentation – was introduced as an option for non-surgical periodontal therapy.

In fact, preclinical studies have shown that sodium hypochlorite/amino acid gel acts antiseptically in particular against gram-negative species associated with periodontitis and is able to alter biofilm matrices.[3] Moreover, hyaluronic acid demonstrated bacteriostatic effects on bacterial strains associated with periodontitis and was proven to be beneficial in minimising bacterial contamination of surgical wounds.[11]

Regarding the 'Clean and Seal' concept, the cleaning effect is achieved by the activity of the sodium hypochlorite/amino acid gel. Laboratory experiments have demonstrated that sodium hypochlorite/amino acid gel has a softening effect on the extracellular matrix of the biofilm[14] and therefore, during treatment, both mechanical and chemical reactions act in concert to disrupt the biofilm and remove granulation tissue.[23] It is noteworthy that this chemomechanical method has no detrimental effect on sound dentin and/or root cementum. The high pH of the product affects calculus and has a softening effect, which makes the cleaning process easier to perform.[23]

The sealing effect is obtained by subsequent application of a mixture of natural and cross-linked hyaluronic acid gel (high molecular). Hyaluronic acid is a major constituent of the extracellular matrix of the skin, joints, eye, and many other tissues and organs.[18] Numerous in-vitro studies have provided evidence that hyaluronic acid stimulates blood clot formation,[26] induces angiogenesis[6] and enhances osteogenesis.[5,15,25] In addition, hyaluronic acid was found to play a key role in each phase of wound healing by stimulating cell migration, differentiation, and proliferation.[18]

However, at present, clinical data validating the clinical efficacy of the aforementioned treatment concept in patients with untreated periodontitis is lacking. Therefore, the aim of this prospective case series was to evaluate in patients with untreated periodontitis the clinical outcomes obtained with subgingival application of sodium hypochlorite/amino acid and a mixture of natural and cross-linked hyaluronic acid (high molecular) in conjunction with non-surgical periodontal therapy.

MATERIALS AND METHODS

Subject Selection

A total of 21 systemically healthy patients were recruited from new referrals to the Department of Dental and Oral Pathology, Lithuanian University of Health Sciences. The inclusion criteria were: a clinical diagnosis of stage II-III periodontitis,[20] at least one pocket in each quadrant with pocket depth (PD) ≥ 5 mm; radiographic evidence of bone loss (> 2 mm from cemento-enamel junction [CEJ]); a minimum of 20 teeth (wisdom teeth excluded); no removable prosthesis. The exclusion criteria were: patients already included in other clinical trials; smokers; periodontal treatment during the last 12 months; antibiotic treatment 6 months prior to the start of the trial; antibiotic prophylaxis required for dental treatment; ongoing medication that may affect the clinical features of periodontitis; pregnancy/lactation.

Furthermore, patients were included in the study if they exhibited an adequate level of oral hygiene evidenced by full-mouth plaque score (FMPS) <25%[19] and full-mouth bleeding score (FMBS) <25%.[16] Written informed consent was obtained from all patients. Ethical approval was obtained from Kaunas Regional Biomedical Research Ethics Committee (2018-BE-2-87).

Treatment

Baseline periodontal measurements were obtained two weeks prior to treatment, which was followed by professional supragingival tooth cleaning and individual oral hygiene instructions for all of the included patients. Oral hygiene instructions were reinforced at each follow-up visit, but no further treatment was provided.

Two weeks later, under local anesthesia, all patients underwent full-mouth SD performed with ultrasonic (Satelec/Acteon suprasson newtron ultrasonic scaler; Merignac, France) and hand instruments (LM SharpDiamond 1/2, 7/8, 11/12, 13/14 SD mini Gracey and Gracey curettes). Subsequently, all teeth were polished using a low-abrasive paste (Lunos Super Soft, RDA<5, Dürr Dental; Bietigheim-Bissingen, Germany). Per patient, the average time needed for the treatment was 3 h. All teeth with probing depths (PD) ≥ 4 mm were treated with sodium hypochlorite/amino acid gel (Perisolv, Regedent) injected into the periodontal pockets 60 s prior to and during SD (2-3 times) (Fig 1). No additional rinsing with saline was performed. Mechanical debridement was followed by the subsequent application of a mixture of natural and cross-linked hyaluronic acid (high molecular) gel (Hyadent BG, Regedent) in periodontal pockets measuring ≥ 4 mm (Fig 2).

Periodontal treatment was performed by an experienced periodontist (E.R.).

All patients were advised to follow their regular home oral-hygiene regimen and to refrain using antiseptic mouthwashes during the entire study period.

Clinical Assessments

The following clinical parameters were assessed using a Williams periodontal probe to the nearest mm (LM 51 ES, LM-Dental; Parainen, Finland) at all teeth at six sites per tooth (i.e., mesio-buccal [mb], mid-buccal [b], disto-buccal [db], mesio-oral [mo], mid-oral [o] and disto-oral [do]) at baseline, 3 and 6 months post-treatment:

- Bleeding on probing (BOP) assessed through visual inspection 20 s after probing using a dichotomous scale (present/absent)

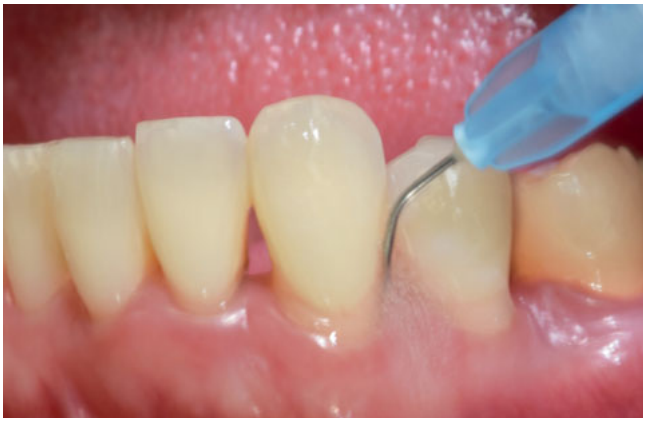

Fig 1 Application of sodium hypochlorite/amino acid gel to the periodontal pocket.

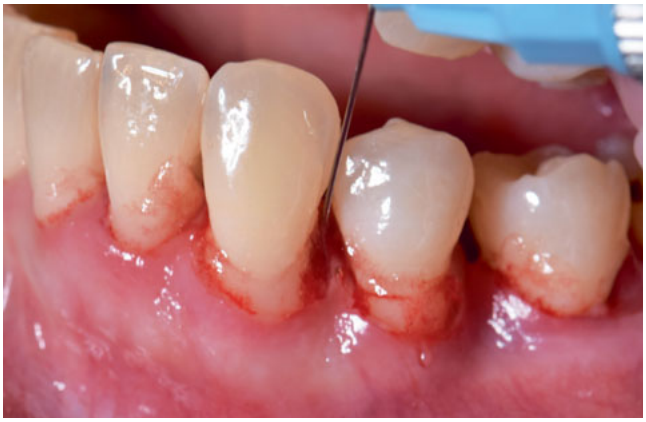

Fig 2 Application of a mixture of natural and cross-linked hyaluronic acid (high molecular) to the periodontal pocket.

- Probing depth (PD) measured in mm from the gingival margin to the bottom of the probed pocket
- Recession (REC) measured in mm from the gingival margin to the cemento-enamel junction or to the margin of a cervical restauration
- Clinical attachment level (CAL) calculated by adding PD and REC at each site

Clinical assessments were performed by a calibrated examiner (U.M.D.) who was not aware of the procedure to be performed. Before the beginning of the study, five patients not involved in the study, each diagnosed with periodontitis stages II–III,[20] were used to calibrate the examiner. The examiner was asked to evaluate PD, REC, CAL and BOP at 6 sites per tooth at 2 separate appointments, 48 h apart. Calibration was accepted if measurements at baseline and at 48 h were equal to the nearest mm at the >90% level.

Statistical Analysis

Statistical analysis was performed using IBM SPSS Statistics 27 software (IBM; Armonk, NY, USA). The primary outcome variable was the reduction of PD. The Shapiro-Wilk test was performed to assess whether clinical periodontal measures followed a normal distribution. Statistical analysis was based on the Wilcoxon signed-rank test to assess pre- and post-treatment comparisons. Statistical significance was set at $p < 0.05$.

RESULTS

This case series comprised a total of 21 healthy non-smoking patients, 15 females (71.4%) and 6 males (28.6%). The age of the included patients ranged from 33 to 75 years old, with a median age 50 years.

Descriptive statistics for PD, CAL, and BOP at baseline of the study are summarised in Table 1.

Compared to baseline, a statistically significant mean reduction of PD was obtained after 3 and 6 months, amounting to 2.6 ± 0.4 mm and 2.9 ± 0.4 mm, respectively ($p < 0.001$).

The difference in PD reduction between the 3- and 6-month follow-ups was 0.3 ± 0.3 mm, and was statistically significant ($p = 0.004$). Compared to baseline, mean CAL gain amounted to 2.3 ± 0.5 mm at 3 months, and 2.6 ± 0.5 mm at 6 months ($p < 0.001$). A statistically significant difference of CAL gain was measured between the 3- and 6-month follow-up visits (0.4 ± 0.4 mm, $p = 0.016$).

A statistically significant reduction of mean BOP values was noted after 3 and 6 months following treatment. In particular,

Table 1 Descriptive characteristics of sample population at the baseline

Patients (n)	21
Median age (range)	50 (33–75)
Gender, n (%) Males Females	 6 (28.6) 15 (71.4)
PD (mm) Mean ± SD	4.7 ± 0.2
CAL (mm) Mean ± SD	4.9 ± 0.5
BOP (%) Mean ± SD	83.2 ± 15.6

Table 2 Means (SD) of the differences (Δ) from baseline for probing depth (PD), clinical attachment level (CAL) and bleeding on probing (BOP)

	Month 3	Month 6	Δ 3 to 6 months
Δ PD (mm)	2.6 (0.4)	2.9 (0.4)	0.3 (0.4)
Δ CAL (mm)	2.3 (0.5)	2.6 (0.5)	0.4 (0.4)
Δ BOP (%)	54.9 (16.9)	65.6(16.4)	10.7 (11.9)
Statistically significant ($p < 0.001$).			

Table 3 Number of sites with shallow (1–3 mm), medium (4–5 mm) and deep (> 6 mm) pockets at different timepoints

	1–3 mm	4–5 mm	≥ 6 mm
Baseline	1603	1803	319
After 3 months	3224	414	9
After 6 months	3375	274	3

a mean reduction of BOP values compared to baseline reached 54.9 ± 16.9 % at 3 months and 65.6 ± 16.4 % at 6 months ($p < 0.001$). The BOP reduction between 3- and 6-month follow-ups amounted to 10.7 ± 11.9 % ($p < 0.001$).

Means (SD) of the differences vs baseline for PD, CAL and BOP are depicted in Table 2.

Furthermore, the frequency distribution of shallow (1-3 mm), medium (4-5 mm) and deep (> 6 mm) pockets at baseline, at 3 and at 6 months was analysed (Table 3). At baseline, study subjects exhibited 1803 sites with PD 4-5 mm, which decreased to 414 and 274 sites at the 3- and 6-month follow-ups, respectively. The number of sites ≥ 6 mm decreased from 319 at baseline to 9 at 3 months and to 3 at 6 months.

DISCUSSION

The present prospective case-series study investigated the clinical outcomes obtained with subgingival application of sodium hypochlorite/amino acid and a mixture of natural and cross-linked hyaluronic acid (high molecular) gels in conjunction with non-surgical periodontal therapy.

The findings suggest that the adjunctive application of a combination of sodium hypochlorite/amino acid and a mixture of natural and cross-linked hyaluronic acid (high molecular) gels to scaling and root planing in pockets exhibiting a PD ≥ 4 mm led to statistically significant improvements of the investigated clinical parameters. In particular, at 6 months after treatment, the mean PD reduction was 2.9 ± 0.4 mm ($p < 0.001$), while the mean CAL gain measured 2.6 ± 0.5 mm ($p < 0.001$). The mean BOP decreased from 83.2 ± 15.5% at baseline to 17.6 ± 11.5 % at the 6-month follow-up ($p < 0.001$). Interestingly, a statistically significant improvement in PD, CAL and BOP values was observed from the 3- to the 6-month follow-up, even though no further treatment was performed.

An important finding of the present study is the change in the total number of moderate (4-5 mm) and deep (≥ 6 mm) pockets. In particular, the total number of pockets of 4-5 mm was reduced from 1803 to 274 with the corresponding values of 319 and 3 in the deep-pocket (≥ 6 mm) category. As the ultimate goal of non-surgical periodontal therapy is to reduce/eliminate all sites > 4 mm, the 'Clean and Seal' technique seemed to be efficient in reducing further treatment need for the residual periodontal pockets.

Another important finding was the uneventful healing of soft tissues; none of the patients reported any adverse reactions or discomfort following therapy. These findings are important, since to the best of our knowledge, this is the first clinical study evaluating the effectiveness of sodium hypochlorite/amino acid and a mixture of natural and cross-linked hyaluronic acid (high molecular) gels in conjunction to SRP in patients with untreated periodontitis.

Justification for the adjunctive application of hyaluronic acid has been provided by several clinical studies.[7,12,21] Previous clinical data pointed to statistically significant reductions in PD[7,12,21] and BOP,[12,21] as well as CAL gains,[21] following adjunctive hyaluronic acid applications compared to subgingival debridement alone. In line with this, findings of one recent systematic review on non-surgical periodontal therapy pointed to a statistically significant reduction in PD (weighted mean difference (WMD): 0.36 mm; 95%CI: 0.54 to -0.19 mm; $p<0.0001$), BOP values (-15%; 95%CI: -22 to -8%; $p<0.0001$) and CAL gain (0.73 mm; 95% CI:

0.28 to 1.17 mm; p<0.0001) following adjunctive topical application of hyaluronic acid over SRP alone.[8]

Clinical effectiveness of the adjunctive use of sodium hypochlorite gel has been evaluated in several clinical studies reporting on non-surgical treatment of residual periodontal pockets (PD ≥5 mm),[17] non-surgical peri-implant mucositis[9] and peri-implantitis therapy.[23] In particular, while treating residual periodontal pockets, greater PD reduction in initially deep residual pockets (≥7 mm) was observed in the adjunctive sodium-hypochlorite gel group. Furthermore, following treatment, only one residual pocket of ≥ 7 mm was still detectable in a test group, whereas six compromised sites persisted in the control group.[17] Regarding non-surgical peri-mucositis therapy, the adjunctive application of sodium hypochlorite gel led to slightly better PD reduction compared to the control (i.e., mechanical debridement) – from 3.93 ± 1.09 mm to 3.04 ± 0.46 mm (p = 0.0001) and from 3.68 ± 0.85 mm to 3.07 ± 0.58 mm (p = 0.0001), respectively. However, no statistically significant difference was observed between the groups (p=0.53).[9] Similar results were observed when adding sodium hypochlorite gel adjunctively in non-surgical peri-implantitis therapy.[23] In particular, the reduction of BOP-positive sites in the test group changed from 0.97 (SD ± 0.12) to 0.38 (SD ± 0.46), and in the control group from 0.97 (SD ± 0.12) to 0.31 (SD ± 0.42), but there were no statistically significant differences between the study groups.

Despite the fact that no statistically significant improvements in PD and BOP could be obtained in the studies mentioned above,[9,17,23] the test groups always showed a tendency for greater clinical improvements than the controls (i.e., mechanical debridement), thus pointing to the beneficial effect of the adjunctive application of sodium hypochlorite.

When interpreting the results, it must be pointed out that the present case series only provides data from 21 consecutively treated patients without a control group (i.e., SD alone) and with a relatively short follow-up period (i.e., 3 and 6 months). However, despite these limitations, the excellent clinical outcomes coupled with the uneventful healing seem to suggest that this novel treatment concept may be of clinical relevance, thus warranting further investigations. Obviously, randomised controlled clinical trials are needed to validate this treatment concept for non-surgical periodontal therapy.

CONCLUSION

Within its limitations, the present case series has shown that a combination of sodium hypochlorite/amino acid and a mixture of natural and cross-linked hyaluronic acid (high molecular) adjunctive to subgingival mechanical debridement may represent a valuable approach to improve the outcomes of non-surgical periodontal treatment.

ACKNOWLEDGEMENTS

This work was funded by Regedent AG, Zürich Switzerland and Foundation of Science of Lituanian University of Health Sciences.

REFERENCES

1. Belibasakis GN, Belstrøm D, Eick S, Gursoy UK, Johansson A, Könönen E. Periodontal microbiology and microbial etiology of periodontal diseases: Historical concepts and contemporary perspectives. Periodontol 2000 2023 (20 Jan); 10.1111/prd.12473.
2. Borisy GG, Valm AM. Spatial scale in analysis of the dental plaque microbiome. Periodontol 2000 2021;86(1):97–112.
3. Costa FO, Takenaka-Martinez S, Cota LOM, Ferreira SD, Silva GLM, Costa JE. Peri-implant disease in subjects with and without preventive maintenance: a 5-year follow-up. J Clin Periodontol 2012;39(2):173–181.
4. Darveau RP, Curtis MA. Oral biofilms revisited: A novel host tissue of bacteriological origin. Periodontol 2000 2021;86(1):8–13.
5. de Brito Bezerra B, Mendes Brazão MA, de Campos MLG, Casati MZ, Sallum EA, Sallum AW. Association of hyaluronic acid with a collagen scaffold may improve bone healing in critical-size bone defects. Clin Oral Implants Res 2012;23(8):938–942.
6. Deed R, Rooney P, Kumar P, Norton JD, Smith J, Freemont AJ, et al. Early-response gene signalling is induced by angiogenic oligosaccharides of hyaluronan in endothelial cells. Inhibition by non-angiogenic, high-molecular-weight hyaluronan. Int J Cancer 1997;71(2):251–256.
7. Eick S, Renatus A, Heinicke M, Pfister W, Stratul SI, Jentsch H. Hyaluronic acid as an adjunct after scaling and root planing: a prospective randomized clinical trial. J Periodontol 2013;84(7):941–949.
8. Eliezer M, Imber JC, Sculean A, Pandis N, Teich S. Hyaluronic acid as adjunctive to non-surgical and surgical periodontal therapy: a systematic review and meta-analysis. Clin Oral Investig 2019;23(9):3423–3435.
9. Iorio-Siciliano V, Blasi A, Stratul SI, et al. Anti-infective therapy of peri-implant mucositis with adjunctive delivery of a sodium hypochlorite gel: a 6-month randomized triple-blind controlled clinical trial. Clin Oral Investig 2020; 24(6):1971–1979.
10. Jakubovics NS, Goodman SD, Mashburn-Warren L, Stafford GP, Cieplik F. The dental plaque biofilm matrix. Periodontol 2000 2021;86(1):32–56.
11. Jepsen S, Berglundh T, Genco R, Aass AM, Demirel K, Derks J, et al. Primary prevention of peri-implantitis: Managing peri-implant mucositis. J Clin Periodontol 2015;42:S152–S157.
12. Johannsen A, Tellefsen M, Wikesjö U, Johannsen G. Local delivery of hyaluronan as an adjunct to scaling and root planing in the treatment of chronic periodontitis. J Periodontol 2009;80(9):1493–1497.
13. Joseph S, Curtis MA. Microbial transitions from health to disease. Periodontol 2000 2021;86(1):201–209.
14. Jurczyk K, Nietzsche S, Ender C, Sculean A, Eick S. In-vitro activity of sodium-hypochlorite gel on bacteria associated with periodontitis. Clin Oral Investig 2016;20(8):2165–2173.
15. Kawano M, Ariyoshi W, Iwanaga K, Okinaga T, Habu M, Yoshioka I, et al. Mechanism involved in enhancement of osteoblast differentiation by hyaluronic acid. Biochem Biophys Res Commun 2011;405(4):575–580.
16. Lang NP, Joss A, Orsanic T, Gusberti FA, Siegrist BE. Bleeding on probing. A predictor for the progression of periodontal disease? J Clin Periodontol 1986; 13(6):590–596.
17. Megally A, Zekeridou A, Cancela J, Giannopoulou C, Mombelli A. Short ultrasonic debridement with adjunctive low-concentrated hypochlorite/amino acid gel during periodontal maintenance: randomized clinical trial of 12 months. Clin Oral Investig 2020;24(1):201–209.
18. Olczyk P, Komosińska-Vassev K, Winsz-Szczotka K, Kuźnik-Trocha K, Olczyk K. [Hyaluronan: structure, metabolism, functions, and role in wound healing]. Postepy Hig Med Dosw (Online) 2008;62:651–659.
19. O'Leary TJ, Drake RB, Naylor JE. The Plaque Control Record. J Periodontol 1972;43(1):38–38.
20. Papapanou PN, Sanz M, Buduneli N, Dietrich T, Feres M, Fine HD, et al. Periodontitis: Consensus report of workgroup 2 of the 2017 World Workshop on the Classification of Periodontal and Peri-Implant Diseases and Conditions. J Clin Periodontol 2018;45:S162–S170.
21. Polepalle T, Srinivas M, Swamy N, Aluru S, Chakrapani S, Chowdary B. Local delivery of hyaluronan 0.8% as an adjunct to scaling and root planing in the treatment of chronic periodontitis: A clinical and microbiological study. J Indian Soc Periodontol 2015;19(1):37.
22. Ramanauskaite E, Machiulskiene V. Antiseptics as adjuncts to scaling and root planing in the treatment of periodontitis: a systematic literature review. BMC Oral Health 2020;20(1):143.
23. Roos-Jansåker AM, Almhöjd US, Jansson H. Treatment of peri-implantitis: clinical outcome of chloramine as an adjunctive to non-surgical therapy, a randomized clinical trial. Clin Oral Implants Res 2017;28(1):43–48.
24. Salvi GE, Mombelli A, Mayfield L, Rutar A, Suvan J, Garrett S, et al. Local antimicrobial therapy after initial periodontal treatment. J Clin Periodontol 2002; 29(6):540–550.

25. Sasaki T. Stimulation of osteoinduction in bone wound healing by high-molecular hyaluronic acid. Bone 1995;16(1):9–15.
26. Scully MF, Kakkar Vv, Goodwin CA, O'Regan M. Inhibition of fibrinolytic activity by hyaluronan and its alcohol ester derivatives. Thromb Res 1995;78(3): 255–258.
27. Sedghi L, DiMassa V, Harrington A, Lynch Sv, Kapila YL. The oral microbiome: Role of key organisms and complex networks in oral health and disease. Periodontol 2000 2021;87(1):107–131.
28. Smiley CJ, Tracy SL, Abt E, Michalowicz BS, John MT, Gunsolley J, et al. Systematic review and meta-analysis on the nonsurgical treatment of chronic periodontitis by means of scaling and root planing with or without adjuncts. JADA 2015;146(7):508–524.e5.

Clinical Oral Investigations
https://doi.org/10.1007/s00784-023-05271-0

RESEARCH

Clinical evaluation of sodium hypochlorite/amino acids and cross-linked hyaluronic acid adjunctive to non-surgical periodontal treatment: a randomized controlled clinical trial

Egle Ramanauskaite[1] · Vita Machiulskiene[1] · Yoshinori Shirakata[2] · Urte Marija Dvyliene[1] · Irena Nedzelskiene[1] · Anton Sculean[3]

Received: 22 May 2023 / Accepted: 17 September 2023

Abstract

Objectives To compare the clinical outcomes obtained with either mechanical subgingival debridement in conjunction with a sodium hypochlorite and amino acids containing gel followed by subsequent application of a cross-linked hyaluronic acid gel (xHyA) gel, or with mechanical debridement alone.

Materials and Methods Fourty-eight patients diagnosed with stages II-III (Grades A/B) generalised periodontitis were randomly treated with either scaling and root planing (SRP) (control) or SRP plus adjunctive sodium hypochlorite/amino acid and xHyA gels (test). The primary outcome variable was reduction of probing depth (PD), while changes in clinical attachment level (CAL), bleeding on probing (BOP) and plaque index (PI) were secondary outcomes. The outcomes were assessed at baseline, at 3 and 6 months following therapy.

Results All patients completed the 6 months evaluation. At 6 months, the test group showed statistically significantly better results in terms of mean PD reduction (2.9 ± 0.4 vs 1.8 ± 0.6 mm, $p < 0.001$). Similarly, mean CAL gain was statistically higher in the test group compared to the control one (test: 2.6 ± 0.5 vs control: 1.6 ± 0.6 mm, $p < 0.001$). Mean BOP decreased from 81.8 ± 16.2% to 48.9 ± 14.5% in control ($p < 0.001$) and from 83.2 ± 15.5% to 17.6 ± 11.5% in test ($p < 0.001$) groups with a statistically significant difference favouring the test group ($p < 0.001$). Mean PI scores were reduced statistically significantly in both groups (from 38.8 ± 26% to 26.5 ± 20.5% in control (p = 0.039) and from 60.6 ± 10.9% to 12.7 ± 8.9% in test group ($p < 0.001$)), with a statistically significant difference between the groups ($p < 0.001$). The number of moderate pockets (4–6 mm) were reduced from 1518 (41.2%) to 803 (22.6%) in the control and from 1803 (48.6%) to 234 (7.7%) in the test group with a statistically significant difference between the groups ($p < 0.001$), while the number of deep pockets (≥ 7 mm) changed from 277 (7.6%) to 35 (1.0%) in the control and from 298 (8.7%) to 4 (0.1%) in test group ($p = 0.003$).

Conclusion Within their limits the present data indicate that: a) both treatments resulted in statistically significant improvements in all evaluated clinical parameters, and b) the adjunctive subgingival application of sodium hypochlorite/amino acid and xHyA to SRP yielded statistically significantly higher improvements compared to SRP alone.

Clinical relevance The combination of sodium hypochlorite/amino acid and xHyA gels to subgingival mechanical debridement appears to represent a valuable approach to additionally improve the outcomes of non-surgical periodontal treatment. Clinical Trial Registration Number NCT04662216 (ClinicalTrials.gov).

Keywords Periodontitis · Non-surgical periodontal therapy · Cross-linked hyaluronic acid · Sodium hypochlorite/amino acids

Introduction

Periodontitis is a chronic multifactorial inflammatory disease caused by dysbiotic dental plaque biofilms with the formation of an inflammatory infiltrate that contributes to destruction of connective tissue attachment to the tooth, alveolar bone resorption and may result in tooth loss [1–5]. In case of periodontitis a disruption of the normal function of the healthy subgingival plaque biofilm with concomitant disruption to its functional properties in relation to innate defense surveillance and tissue maintenance, leading to excessive, deregulated inflammation and tissue destruction is observed [6, 7].

Extended author information available on the last page of the article

Published online: 23 September 2023

Primary clinical features of periodontitis include the loss of periodontal tissue support, which manifests through clinical attachment loss and radiographically assessed alveolar bone loss with the presence of gingival bleeding and periodontal pockets [5]. The recently published clinical practice guidelines for treating stage I–III periodontitis concluded that cause-related therapy is aimed at reducing/eliminating the subgingival biofilm and calculus by means of subgingival instrumentation, which may include the adjunctive application of physical or chemical agents [8].

Recent systematic reviews have provided some evidence indicating that adjunctive aids, in conjunction with mechanical debridement, might enhance the outcomes of non-surgical periodontal therapy [9–12]. More recently, findings from *in vitro* experiments have shown, that a sodium hypochlorite gel has a softening effect on the extracellular biofilm matrix which in turn, may facilitate its mechanical removal. It has been shown that the effect of sodium hypochlorite/amino acid gel is due to its active part, the chloramine, which forms following the chlorine transfer of sodium hypochlorite to the amine functions of the added amino acids [13]. Amino acids act like a buffer and provide protection to soft tissues. The high pH (11) of this formulation has a softening effect on the calculus, which makes the cleaning process easier [14]. Therefore, it may be anticipated that during subgingival debridement treatment, both the mechanical and chemical components act synergistically to disrupt the hard and soft biofilm which in turn, may facilitate granulation tissue removal [13, 14]. In this respect, positive clinical effects of a sodium hypochlorite gel were reported in studies treating residual periodontal pockets [15, 16], peri-implant mucositis [17] and peri-implantitis [14].

HA is a naturally occurring biodegradable polymer that is responsible for several structural properties of tissues as a component of the extracellular matrix [18]. Several studies have provided evidence indicating that HA plays an important role in wound healing, supports scarless wound-healing, promotes angiogenesis and has a bacteriostatic effect in surgical wounds [19–22]. When used during periodontal surgery, HA has been shown to promote periodontal regeneration in intrabony, recession and furcation defects [23–25]. Clinical studies revealed that HA may represent a valuable constituent to mechanical debridement (i.e., scaling and root planing), thus resulting in statistically significant clinical improvements, evidenced by reduction in probing depth (PD), gain of clinical attachment (CAL) and improved bleeding on probing (BOP) values, compared to scaling and root planing alone [26–29].

Recently, a novel concept consisting of enhancing biofilm removal during nonsurgical therapy by means of a sodium hypochlorite/amino acids followed by application of a cross-linked hyaluronic acid gel (xHyA) gel was suggested as a novel strategy to improve the outcomes of nonsurgical periodontal therapy [30, 31]. Results from two case series have shown statistically significant clinical improvements compared to baseline following scaling and root planing in conjunction with sodium hypochlorite/amino acid and xHyA, thus suggesting that this strategy may represent a valuable novel strategy in non-surgical periodontal treatment.

However, to the best of our knowledge, at present no randomized controlled clinical trials have evaluated the potential clinical relevance of this novel concept as compared to mechanical debridement alone.

Therefore, the aim of this randomized controlled clinical study was to compare the clinical outcomes obtained with either mechanical subgingival debridement in conjunction with sodium hypochlorite/amino acid gel followed by subsequent application of xHyA, or with mechanical debridement alone.

Material and methods

Study design

This study was conducted as a 6-months prospective, examiner-blind, randomized controlled clinical trial with a parallel design. The study was performed according to CONSORT guidelines for randomized controlled clinical trials (http://www.consort-statement.org/) [32]. Ethical permission was issued by the Regional Biomedical Research Ethics Committee (No. BE-2–87). Prior to participation, all patients signed a written informed consent form. After signing the informed consent form, the patients were randomly assigned to the control or test groups (allocation ratio 1:1). The study was conducted between September 2019 and January 2022. In addition, the study protocol was registered at ClinicalTrials.gov, NCT04662216.

Study population

All patients included in the study were enrolled and treated at the Department of Dental and Oral Pathology at the Lithuanian University of Health Sciences in Kaunas, Lithuania.

Inclusion criteria:

- Males and females ≥ 18 years old.
- Periodontitis stages II–III, grades A/B, generalised [5].
- Good general health (i.e., absence of systemic diseases and no intake of medication which may affect periodontal health).
- Presence of at least 20 teeth (wisdom teeth excluded).
- Absence of removable dentures.
- Patients willing to provide written informed consent and willing to complete the 6-month study follow-up.

Exclusion criteria:

- Patients already included in other clinical trials.
- Smokers.
- Periodontal treatment during the last 12 months.
- Antibiotic treatment 3 months prior to the start of the trial.
- Antibiotic prophylaxis required for dental treatment.
- Ongoing medication that may affect the clinical features of periodontitis.
- Pregnant/lactating.
- Allergies to sodium hypochlorite

Sample size calculation

At the start of the study, a significance level of $\alpha = 0.05$, a relevant average difference in PD of 1 mm between study groups with a standard deviation of 1 mm and a power (1—α) of at least 0.8 were set to calculate the minimum number of necessary cases (at least 20 per group). Assuming any possible dropouts during the study period, the number of patients was increased to 24 in each group. A power calculation at the end of the study with the given number of cases yielded a power of 99.6%.

Periodontal treatment

Baseline periodontal measurements were obtained 2 weeks prior to the treatment, which was followed by professional supragingival tooth cleaning and individual oral hygiene instructions for all included patients. These treatments included manual toothbrushes and interdental brushes. All patients were provided the same type of toothpaste (Elmex Enamel Protection, Gaba GmbH, Germany) and tooth (CS 5460, Curaprox, Curaden, Switzerland) and interdental (TePe, Tepe Mundhygienprodukten, Sweden) brushes. Oral hygiene instructions were reinforced at each follow-up visit, but no further treatment was rendered.

Two weeks later, under local anaesthesia, subjects in the control group underwent full-mouth SRP performed with ultrasonic (Satelec/Acteon suprasson newtron ultrasonic scaler) and hand instruments (LM SharpDiamond 1/2, 7/8, 11/12, 13/14 SD mini Gracey and Gracey curettes, LM Dental™, Finland). Subsequently, all teeth were polished using a low-abrasive paste (Lunos Super Soft, RDA < 5, Dürr Dental, Germany). Mechanical debridement took on average 3.5 h per patient.

In the test group, full-mouth SRP was performed as follows: in all pockets with PD ≥ 4 mm a sodium hypochlorite/amino acid gel (Perisolv®, Regedent AG, Zürich, Switzerland) was instilled into the pockets and kept there for 60 s before subgingival instrumentation. Subgingival instrumentation was carried out with the same ultrasonic and hand instruments and the application of sodium hypochlorite/amino acid gel was repeated until the instrumentation was considered sufficient (i.e., for a total of 2–3 times) (Fig. 1). All treatments were performed with magnifying glasses (4.5X – Ergo Advanced, Univet, Rezzato BS, Italy) and sufficient instrumentation was attained when root surfaces exhibited smooth surfaces upon probing with an explorer probe (Explorer-Periodontal Probe 8-520B, LM Dental™, Finland). Following SRP, a mixture of natural and cross-linked hyaluronic acid (high molecular) gel (Hyadent® BG, Regedent AG, Zürich, Switzerland) was instilled in the pockets using a blunt needle (Fig. 2).

Clinical measurements

The following clinical parameters were assessed using a Williams periodontal probe to the nearest mm (LM 51 ES, LM-Dental™, Finland) on all teeth at 6 sites per tooth (i.e., mesio-buccal (mb), mid-buccal (b), disto-buccal (db), mesio-oral (mo), mid-oral (o) and disto-oral (do)) at baseline (T0), 3 months (T1) and 6 months (T2) following the treatment:

- Bleeding on probing (BOP), defined as the percentage of sites positive to bleeding within 10 s after probing (%). BOP was assessed for treated sites (PD ≥ 4 mm) and full mouth (FMBOP).
- Plaque index (PI), defined as the percentage of sites with visual plaque on the tooth surface (%). PI was assessed at treated sites (PD ≥ 4 mm) as well as the full mouth (FMPI).
- Probing depth (PD), measured in millimetres from the gingival margin to the bottom of the probed pocket.
- Recession (REC), measured in millimetres from the gingival margin to the cemento-enamel junction or to the margin of a cervical restoration.

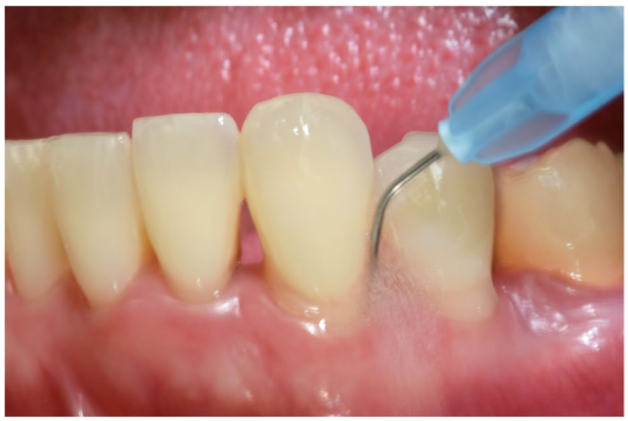

Fig. 1 Application of sodium hypochlorite/amino acid gel to the periodontal pocket

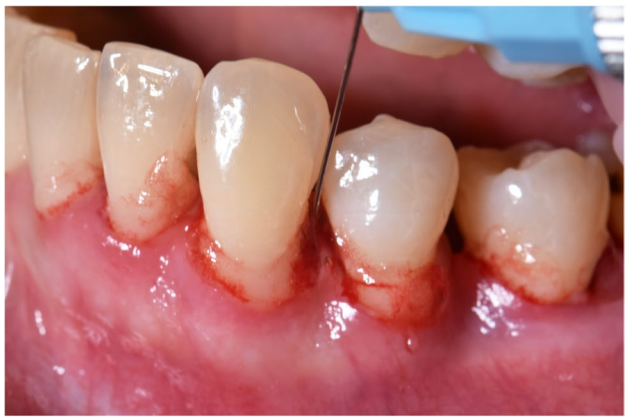

Fig. 2 Application of a mixture of natural and cross-linked hyaluronic acid (high molecular)to the periodontal pocket

- Clinical attachment level (CAL), calculated by adding PD and REC at each site.

At each visit, the clinical examiner had to record possible complications or adverse events related to the tested materials or study interventions, as well as those reported by study subjects.

Outcomes

For data analysis, PDs were subdivided into two categories: moderate (PD 4–6 mm) and deep (PD ≥ 7 mm). The primary outcome variable was the mean PD change from baseline to 6 months in moderate sites. Secondary outcome variables included PD change in deep pockets at 6 months, as well as CAL changes in moderate and deep sites. In addition, mean BOP and PI changes from baseline to 6 months in all treated sites (PD ≥ 4 mm) and the full mouth were evaluated.

Blinding

Clinical measurements and initial supragingival tooth cleaning were performed by a blinded calibrated examiner (U.M.D.), who was not aware in any of the cases of the type of treatment performed. All recordings were made without access to previous measurements to avoid bias.

To ensure blindness, the treatment procedures were performed by one experienced periodontist (E.R.).

The patients were not aware to which group they had been assigned. Periodontal treatment was performed in a sterile field (face drapes were used) to eliminate the possibility for patients to observe the procedure.

A third investigator (I.N.), unaware of the type of treatment performed, processed coded data for statistical analysis.

Randomization and allocation concealment

Forty-eight patients were randomized into two treatment groups. A computer-generated randomization table was created. Patients were assigned unique numbers from 1 to 48, and 2 sets of randomized numbers were generated (24 for control group subjects and 24 for test). Allocation concealment was performed using sealed envelopes to be opened before periodontal treatment. The generation of the random sequence allocation and the assignment of participants to interventions were performed by the investigator, distinct from the clinical examiner and the clinician who performed the treatment.

Calibration

Five patients, not related to the study, each diagnosed with periodontitis stages II–III [5], were used to calibrate the examiner (U.M.D.). The examiner was asked to evaluate PD, REC, CAL, BOP and PI at 6 sites per tooth on 2 separate appointments, 48 h apart. Calibration was accepted if measurements at baseline and at 48 h were equal to the millimetre at > 90% level. The examiner was not aware of the procedure to be performed.

Statistical analysis

Statistical analysis was performed with the IBM SPSS 27 software package (IBM Corp.). Data analysis was performed using the patient as the statistical unit. For all clinical parameters, mean values per subject and per visit were calculated. In particular, PD and CAL of moderate pockets at baseline and at 3- and 6-month follow-ups were obtained by averaging PDs and CALs in moderate sites for each patient at baseline, 3- and 6-month follow-ups. Similarly, per-patient PD and CAL of deep pockets at baseline (and at 3 and 6 months) were obtained by averaging PD and CAL values in deep sites for each patient at baseline, 3 and 6 months. Per-patient BOP and PI were obtained by calculating a percentage share of tooth sites with BOP and plaque for each patient by classifying pockets by baseline PD (all treated sites with PD ≥ 4 mm and the full mouth).

The Shapiro–Wilk test was performed to assess whether clinical periodontal measures followed a normal distribution. If data followed a normal distribution, a paired-samples *t* test was performed to evaluate before- and after-treatment comparisons within groups. If the data did not follow a normal distribution, the Wilcoxon signed rank test was performed on related samples to assess before- and after-treatment comparisons within the groups. The between-group comparisons of measures were obtained by either the independent-samples *t* test (if a parameter followed a normal distribution) or the Mann–Whitney test (if a specific measure followed a non-normal distribution). The significance level was set at 0.05.

Results

Participant flow

All 48 patients completed the study. Each treatment group (SRP or SRP + sodium hypochlorite/amino acid + xHyA) consisted of 24 randomly selected patients. A flowchart of the study is depicted in the CONSORT flow diagram (Fig. 3). In all subjects, healing was uneventful. No adverse effects of sodium hypochlorite/amino acid and xHyA were observed during the study period.

Baseline characteristics

Clinical and demographic baseline characteristics of the 48 participants are shown in Table 1. The baseline examination revealed that the two study groups showed similar characteristics for PD, CAL, bleeding (BOP and FMBOP) and plaque scores with no significant differences between the groups (except for PI and FMPI) (Table 1A). Furthermore, regarding the number of type of treated teeth, no statistically significant differences were observed between control and test groups (Table 1B).

Effect on clinical parameters

PD changes during the study period were analysed for different pocket categories: mean moderate (4–6 mm) and mean deep (PD ≥ 7 mm) pockets. Data is presented in Table 2.

In mean moderate pockets, the baseline values did not reveal a statistically significant difference between control and test groups (4.8 ± 0.2 and 4.7 ± 0.2, respectively, $p = 0.417$). Both groups showed statistically significant improvements at 3 and 6 months compared to baseline ($p < 0.001$); however, statistically significantly higher reductions were observed in favour for the test group at both points in time ($p < 0.001$) (Table 2). The change of PD between 3 and 6 months differed statistically significantly between groups in favour for the test group ($p = 0.002$) (Fig. 4).

Baseline PD values in mean deep pockets category were not statistically significantly different between control and test groups (8.0 ± 0.7 and 8.2 ± 0.9, respectively, $p = 0.443$). Both groups reached statistically significant improvements at 3 and 6 months compared to baseline ($p < 0.001$); however, PD reduction in the test group was statistically significantly higher compared to the control group at both follow-ups ($p < 0.001$) (Table 2). The change between 3 and 6 months did not differ between the groups ($p = 0.096$) (Fig. 5).

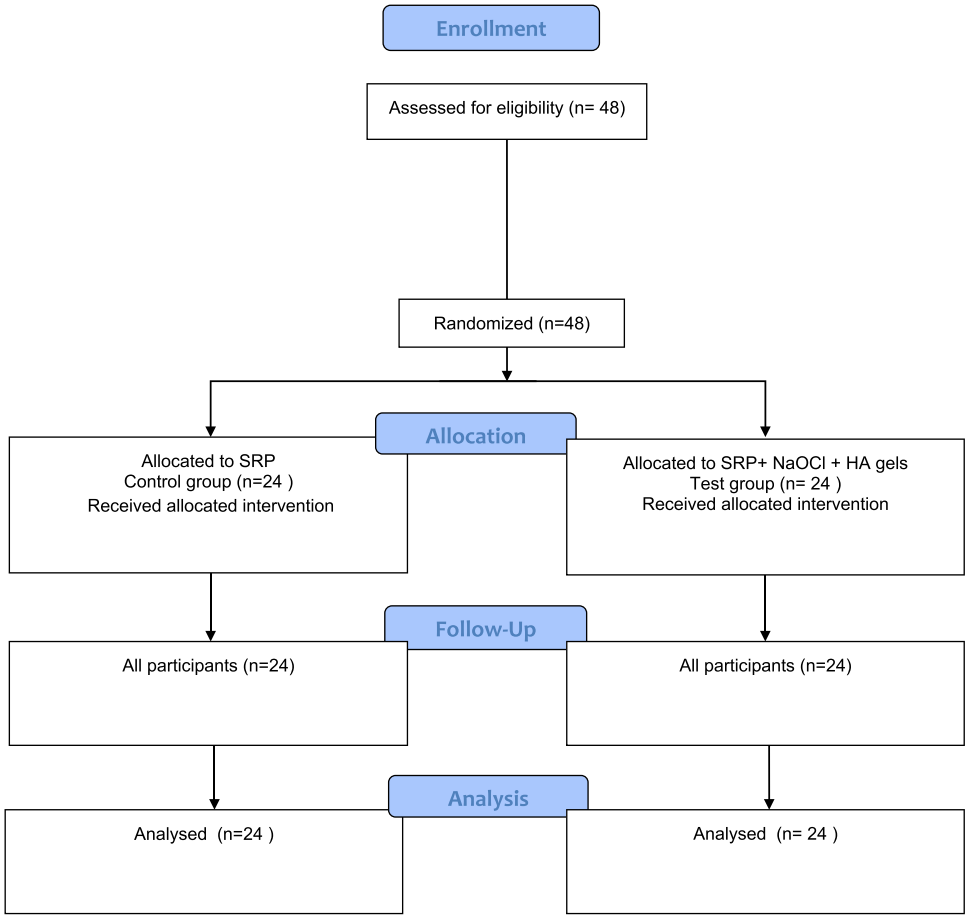

Fig. 3 CONSORT flow diagram of participant recruitment

Table 1 Clinical and demographic characteristics of sample population at the baseline

A. Characteristics of sample population at the baseline

	SRP ($N=24$)	SRP + NaOCl + HA ($N=24$)	*P* value
Age (years)	49.3 ± 11.2	47.3 ± 10.7	0.53[a], n.s
Gender, *n* (%)			
Males	7 (29.2)	6 (25)	0.745[b],
Females	17 (70.8)	18 (75)	n.s
Periodontitis stage, *n* (%)			
Stage II	16 (66.7)	17 (70.8)	0.134[b],
Stage III	8 (33.3)	7 (29.2)	n.s
Grade A	13 (54.2)	12 (50.0)	
Grade B	11 (45.8)	12 (50.0)	0.242[b], n.s
PD (mm)	5.3 ± 0.6	5.2 ± 0.4	0.592[c], n.s
CAL (mm)	5.5 ± 0.5	5.6 ± 0.6	0.546[c], n.s
PI (%)	38.8 ± 26	60.6 ± 10.9	**0.002[c]**
BOP (%)	81.8 ± 16.2	83.2 ± 15.5	0.687[c], n.s
FMPI (%)	35.7 ± 23.7	52.9 ± 11.4	**0.003[c]**
FMBOP (%)	68.9 ± 20.3	76.5 ± 18.2	0.184[c], n.s

B. Distribution of treated teeth

Treatment	Second Molars	First Molars	Second Premolars	First Premolars	Canines	Lateral Incisors	Central incisors
Control group (*n*)	88	84	89	91	94	94	95
Test group (*n*)	86	90	86	89	96	96	96
p	0.549	0.187	0.505	0.682	0.153	0.153	0.317

BOP – bleeding on probing; CAL – clinical attachment level; FMBOP – full-mouth bleeding on probing; FMPI – full-mouth plaque index; PD – probing depth; PI – plaque index

n.s. not significant

[a] Independent-samples *t* test

[b] Fisher's exact test for the 2 × 2 table, sex by group (SRP, SRP + NaOCl + xHyA)

[c] Mann–Whitney U test for two independent groups

Mann–Whitney U test for two independent groups

Table 2 PD (mean (SD)) at sites with moderate (4–6 mm) and deep (≥ 7 mm) pockets

	Control group ($n=24$)	Test group ($n=24$)	*p* value
Moderate pockets (4–6 mm)			
Baseline	4.8(0.2)	4.7(0.2)	0.417[a]
After 3 months	2.9(0.7)	2.2(0.4)	< 0.001[a]
Baseline vs. 3 months	< 0.001[b]	< 0.001[b]	< 0.001[a]
After 6 months	3.0(0.6)	1.8(0.4)	
Baseline vs. 6 months	< 0.001[b]	< 0.001[b]	
Deep pockets (≥ 7 mm)			
Baseline	8.0(0.7)	8.2(0.9)	0.443[a]
After 3 months	4.4(1.4)	2.9(1.1)	< 0.001 [a]
Baseline vs. 3 months	< 0.001[b]	< 0.001[b]	< 0.001
After 6 months	4.3(1.0)	2.4(1.0)	
Baseline vs. 6 months	< 0.001[b]	< 0.001[b]	

[a] Statistical analysis by Student's t test for two independent groups

[b] Paired Samples T Test for two dependent groups

CAL changes in mean moderate and mean deep pockets are reported in Table 3.

At baseline, in mean moderate pockets group, the CAL values were slightly higher in the control group (4.8 ± 0.3 mm) compared to the test group (4.6 ± 0.2 mm; $p = 0.026$). Both groups reached significant improvements at 3 and 6 months compared to baseline ($p < 0.001$); however, a statistically significant difference between groups was observed in favour of the test group at both points in time ($p < 0.001$) (Table 3). Mean CAL change between the 3- and 6-month follow-ups was statistically significantly different between the groups in favour for the test group ($p = 0.004$) (Fig. 6).

In mean deep pockets baseline, CAL values were not statistically significantly different and measured 7.9 ± 0.6 mm in the control group and 8.1 ± 0.7 mm in the test group ($p = 0.412$), respectively. Both groups reached statistically significant improvements at both follow-ups, compared to baseline ($p < 0.001$); however, statistically significantly

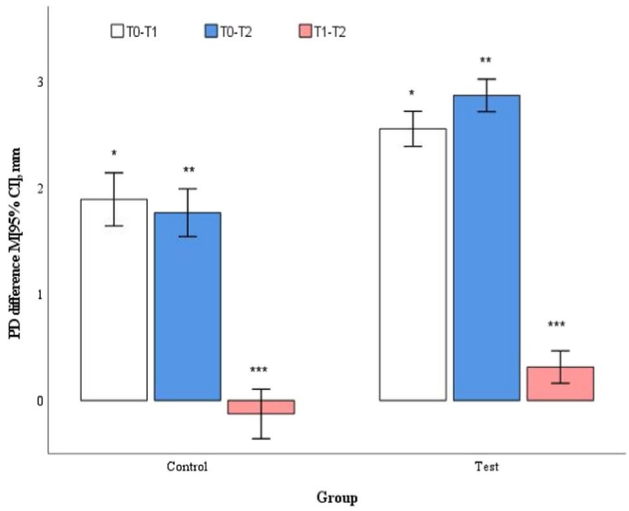

Fig. 4 Mean changes in PD in moderate pockets (4-6 mm) at different time points. $^{*,**}p<0.001$, $^{***}p=0.002$ by Student's t test for two independent groups. T0 – baseline; T1 – 3 months follow-up; T2 – 6 months follow-up

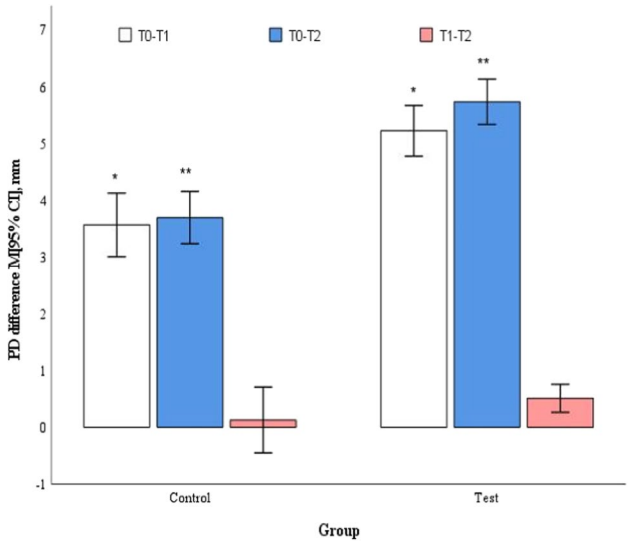

Fig. 5 Mean changes in PD in deep pockets (≥7 mm) at different study time points. $^{*,**}p<0.001$, by Student's t test for two independent groups. T0 – baseline; T1 – 3 months follow-up; T2 – 6 months follow-up

Table 3 CAL (mean ± SD) at sites with moderate (4–6 mm) and deep (≥7 mm) pockets

	Control group ($n=24$)	Test group ($n=24$)	p value
Moderate pockets (4–6 mm)			
Baseline	4.8(0.3)	4.6(0.2)	0.026[a]
After 3 months	3.1(0.8)	2.4(0.6)	<0.001[a]
Base vs. 3 months	<0.001[b]	<0.001[b]	<0.001[a]
After 6 months	3.1(0.7)	2.0(0.5)	
Base vs. 6 months	<0.001[b]	<0.001[b]	
Deep pockets (≥7 mm)			
Baseline	7.9(0.6)	8.1(0.7)	0.412[a]
After 3 months	4.5(1.2)	3.2(1.4)	0.002 [a]
Base vs. 3 months	<0.001[b]	<0.001[b]	<0.001 [a]
After 6 months	4.6(1.0)	2.8(1.3)	
Base vs. 6 months	<0.001[b]	<0.001[b]	

[a] Statistical analysis by Student's t test for two independent groups

[b] Paired Samples T Test for two dependent groups

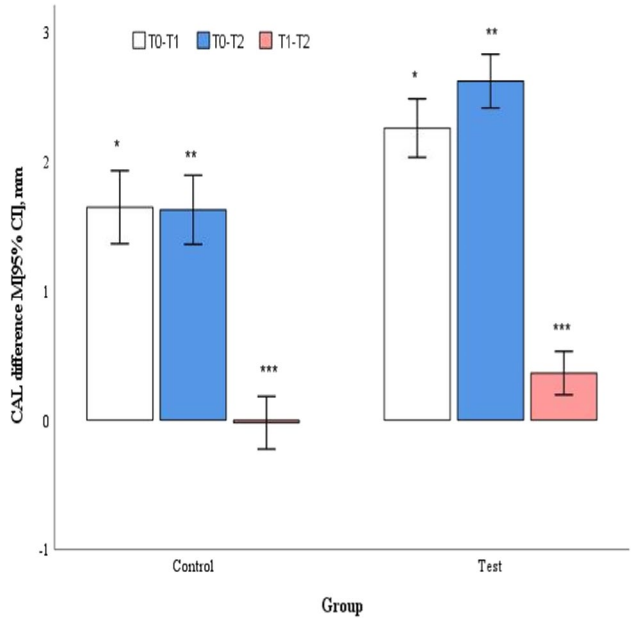

Fig. 6 Mean changes in CAL in moderate pockets (4-6 mm) at different study time points. $^{*,**}p<0.001$, $^{***}p=0.004$ by Student's t test for two independent groups. T0 – baseline; T1 – 3 months follow-up; T2 – 6 months follow-up

better improvements were achieved in favour for the test group ($p<0.001$) (Table 3). Mean CAL change between 3- and 6-month follow-up did not show a statistically significant difference between the groups ($p=0.077$) (Fig. 7).

BOP changes were evaluated for treated sites (PD ≥ 4 mm) and full mouth (FMBOP).

Regarding full-mouth measurements, baseline FMBOP values were similar in test (76.5 ± 18.2%) and control (68.9 ± 20.3%) groups ($p=0.184$). Both study groups reached significant improvements at 3 and 6 months compared to baseline ($p<0.001$). The difference between groups was not statistically significant at the 3-month follow-up ($p=0.06$) but reached a statistically significant difference in favour for the test group at the 6-month follow-up ($p<0.001$) (Table 4).

The analysis of treated pockets (PDs ≥ 4 mm) revealed no statistically significant difference in baseline BOP values between test and control groups ($p=0.687$). Although both

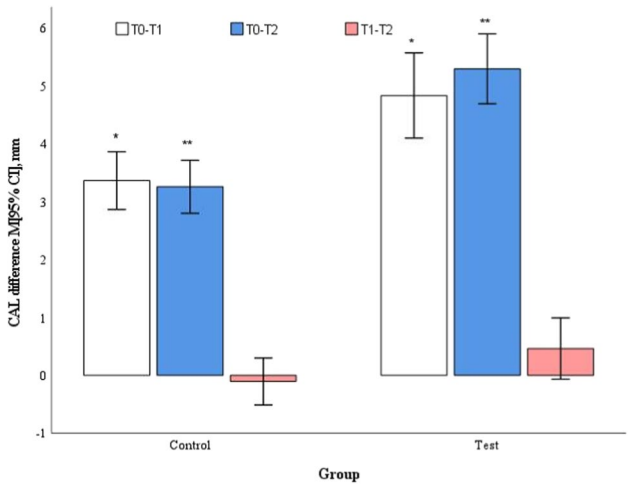

Fig. 7 Changes in CAL in deep pockets (≥7 mm) at different study time points. *$p=0.002$, **$p<0.001$, by Student's t test for two independent groups. T0 – baseline; T1 – 3 months follow-up; T2 – 6 months follow-up

groups showed statistically significant improvements at 3- and 6-month follow-ups compared to baseline ($p<0.001$), the reduction of BOP was statistically significantly better in the test group compared to the control group at both points in time ($p=0.018$ and $p<0.001$, respectively) (Table 4).

PI changes were evaluated for treated sites (PD ≥ 4 mm) and the full mouth (FMPI).

Baseline FMPI values were higher in the test group (52.9 ± 11.4%) than in the control one (35.7 ± 23.7%) ($p=0.003$). However, both groups showed significant improvements at 3- and 6-month follow-ups compared to baseline ($p<0.001$). The intergroup comparison revealed a statistically significant difference between groups in favour for the test group at 6 months ($p=0.006$) (Table 5).

A similar pattern was observed in the analysis for PI at treated pockets. In particular, higher PI (%) values were reported in the test group than the control group ($p=0.002$). Both study groups showed statistically significant improvements at 3- and 6-month evaluations, compared to baseline ($p<0.001$). No statistically significant difference was observed between groups at the 3-month evaluation ($p=0.714$), whereas at the 6-month examination, the reduction in PI was statistically significantly greater in the test group ($p=0.018$) (Table 5).

Analysis of frequency distributions of shallow, medium, and deep pockets

Additionally, the analysis of frequency distribution of shallow (1–3 mm), medium (4–6 mm) and deep (≥7 mm) sites at baseline, 3 and at 6 months was performed (Table 6). At baseline, subjects in the control group had 1518 (41.2%) sites with moderate pockets (4-6 mm) and test group 1803 (48.6%) sites, respectively. At 6 months this number reduced to 803 (22.6%) in control and 234 (7.7%) sites in the test

Table 4 BOP (%) at treated sites (PD ≥ 4 mm) and full mouth (mean ± SD)

	BOP		*P* value	FMBOP		*P* value
	Control ($n=24$)	Test ($n=24$)		Control ($n=24$)	Test ($n=24$)	
Baseline	81.8 ± 16.2	83.2 ± 15.5	0.687[a]	68.9 ± 20.3	76.5 ± 18.2	0.184[a]
After 3 months	39.1 ± 15.9	28.3 ± 14.6	**0.018**[a]	33.3 ± 13.7	25.9 ± 12.3	0.06[a]
Baseline vs 3 months	**< 0.001**[b]	**< 0.001**[b]		**< 0.001**[b]	**< 0.001**[b]	
After 6 months	48.9 ± 14.5	17.6 ± 11.5	**< 0.001**[a]	40.8 ± 13.8	15.6 ± 9.9	**< 0.001**[a]
Baseline vs 6 months	**< 0.001**[b]	**< 0.001**[b]		**< 0.001**[b]	**< 0.001**[b]	

[a] Statistical analysis by Student's t or Mann–Whitney test for two independent groups

[b] Wilcoxon Signed Ranks Test for two dependent groups

Table 5 PI (%) at treated sites (PD ≥ 4 mm) and full mouth (mean ± SD)

	PI		*P* value	FMPI		*P* value
	Control	Test		Control	Test	
Baseline	38.8 ± 26	60.6 ± 10.9	**0.002**[a]	35.7 ± 23.7	52.9 ± 11.4	**0.003**[a]
After 3 months	20.3 ± 16.7	18.8 ± 11.4	0.714[a]	19.3 ± 15.0	17.1 ± 9.7	0.893[a]
Baseline vs 3 months	**< 0.001**[b]	**< 0.001**[b]		**< 0.001**[b]	**< 0.001**[b]	
After 6 months	26.5 ± 20.5	12.7 ± 8.9	**0.018**[a]	23.5 ± 16.6	11.2 ± 7.9	**0.006**[a]
Baseline vs 6 months	**0.039**[b]	**< 0.001**[b]		**< 0.001**[b]	**< 0.001**[b]	

[a] Statistical analysis by Student's t or Mann–Whitney test for two independent groups

[b] Wilcoxon Signed Ranks Test for two dependent groups

group with a statistically significant difference between the groups ($p < 0.001$). Similarly, the number of deep pockets (≥ 7 mm) changed from 277 (7.6%) to 35 (1.0%) in control and from 298 (8.7%) to 4 (0.1%) in test at 6 months evaluation with a statistically significant difference between the groups ($p = 0.003$) (Table 6).

No sub-analysis between different tooth types was performed since the results are presented only for moderate (PD 4–6 mm) and deep sites (PD ≥ 7 mm) without including furcation involved teeth.

Discussion

The present randomized clinical trial has investigated the clinical outcomes obtained with the subgingival application of a combination of sodium hypochlorite/amino acid and xHyA gels in conjunction with non-surgical periodontal therapy in untreated periodontitis patients. The results have shown that in patients diagnosed with stages II–III periodontitis, SRP combined with sodium hypochlorite/amino acid and xHyA gels resulted in statistically significantly higher clinical improvements evidenced through PD reduction, CAL gain, and decrease of BOP and PI values as compared to SRP alone.

An interesting observation of the study is related to PD and CAL changes between 3 and 6 months in moderate pockets. In particular, no statistically significant change was observed in the control group between the 3- and 6-month follow-ups, whereas in the test group, the change reached statistical significance. This observation appears to indicate that the test group demonstrated gradual improvements from month 3 to month 6, even though no additional treatment was performed. This finding may bear clinical relevance since it may suggest that the clinical improvements following the adjunctive sodium hypochlorite/amino acid and xHyA to SRP occur over a longer period of time (e.g., up to 6 months). Additionally, this observation may also suggest that a period of 3 months following nonsurgical periodontal therapy might be too early for making a final decision on the need for additional therapy (e.g., periodontal surgery). A similar pattern supporting the gradual improvement, was also observed for FMBOP and FMPI, where no statistically significant differences were observed between the groups at the 3-month follow-up, while it reached statistical significance at 6 months in favour of the test group.

This observation might be explained by the mode of action of xHA. In particular, the high molecular weight cross-linked HA that was used in this clinical trial can maintain its stability for 4 to 6 weeks which in turn, may serve as explanation for its prolonged activity [33].

When interpreting the clinical outcomes, it must be emphasized that the goal of non-surgical periodontal treatment is PD ≤ 4 mm with negative BOP [34]. The results of the current study have shown that the need for further treatment appears to be smaller in the test group, as demonstrated by the analysis of the change of number of moderate (4–6 mm) and deep pockets (≥ 7 mm) over time. In detail, in the control group, the total number of pockets with PD 4–6 mm decreased from 1518 to 803 with the corresponding values of 1803 and 234 in the test group. Similarly, the number of deep sites reduced from 277 to 35 in control and from 298 to 4 in test group.

As stated by Salvi et al., generally, a PD reduction of approximately 1–1.5 mm in moderate pockets (4–6 mm) and 2–2.5 mm in deep pockets (≥ 6 mm) can be expected [35] following mechanical debridement. This occurs concomitantly with CAL gain of approximately 0.5 mm in moderate pockets at baseline and 1.5 mm in deeper sites [35]. Any additional pocket reduction or CAL gain would, therefore, represent a true clinical benefit of the adjunctive materials used. This observation was also confirmed in the present study where in moderately deep sites, the mean PD change from baseline to 6 months measured 1.7 mm in the control group and 2.9 mm in test group, respectively, with the corresponding values of 3.7 mm and 5.8 mm, at deep sites (PD ≥ 7 mm). In moderately deep pockets, the mean CAL gain from baseline to 6 months measured 1.6 mm in the control group and 2.6 mm in test group, while in deep pockets, the corresponding values measured 3.2 mm and 5.3 mm, respectively.

When interpreting the results, one may ask the question to what extent each of the used adjunctive materials contributed to the additional improvements observed in

Table 6 Number of sites with shallow (1–3 mm), medium (4–6 mm) and deep (≥ 7 mm) pockets in test and control groups at different study timepoints

	1–3 mm			4–6 mm			≥ 7 mm		
	Control	Test	*P* value	Control	Test	*P* value	Control	Test	*P* value
Baseline	1916 (51.2%)	1603 (42.7%)	**0.05***	1518 (41.2%)	1803 (48.6%)	**0.041***	277 (7.6%)	298 (8.7%)	0.52
After 3 months	2938 (78.6%)	3284 (88.2%)	**0.013***	728 (20.3%)	402 (11.5%)	**0.018***	39 (1.1%)	12 (0.3%)	0.053
After 6 months	2859 (76.4%)	3398 (92.2%)	**0.006***	803 (22.6%)	234 (7.7%)	**< 0.001***	35 (1.0%)	4 (0.1%)	**0.003***

Data in bold represents statistically significant differences between test and control groups

the test group. In this respect, it is important to emphasize that the present study has used the combination of the two materials as a single concept, thus combining the effects of sodium hypochlorite/ amino acid gel to facilitate mechanical debridement and biofilm removal with the well-known wound-healing facilitating effects of xHyA. Based on previous findings from *in vitro* and animal experiments, it was hypothesized that the inherent effect of NaOCl to facilitate mechanical debridement and biofilm removal, may lend additional support to xHyA to express its wound healing improving properties [20, 23–25].

Despite the inherent positive effects of the used combination approach, it should be kept in mind that combining two materials and their use in conjunction with scaling and root planing also means a higher therapy effort in terms of time and costs. Additionally, it should be also emphasized that the present has only evaluated the outcomes in moderate (PD 4–6 mm) and deep sites (PD ≥ 7 mm) at teeth without furcation involvement. Obviously, further studies are warranted to evaluate the potential effect of this treatment approach in furcation involved teeth.

However, to the best of our knowledge, this is the first RCT evaluating the outcomes following the adjunctive application of sodium hypochlorite/amino acid gel and xHyA to scaling and root planing for untreated periodontal disease.

A recently published retrospective analysis of 29 clinical cases evaluated the adjunctive application of sodium hypochlorite/amino acid and a mixture of natural and cross-linked hyaluronic acid (high molecular) gels to SRP for treating residual periodontal pockets in patients diagnosed with periodontitis stages II–IV who were included into periodontal maintenance [30]. The authors reported an overall PD reduction exceeding 2 mm, associated with a similar CAL gain (2.02 mm). The results are comparable with the results obtained in this study. However, it must be emphasized that the study included compliant patients who already underwent nonsurgical periodontal treatment, as well as patients diagnosed with periodontitis stage IV, and therefore, direct comparisons are difficult. However, the same protocol has been evaluated in a very recent case series consisting of a total of twenty-one systemically healthy, non-smoking patients diagnosed with stage II-III periodontitis [31]. Compared to baseline, a statistically significant mean reduction of PD values was obtained after 3- and 6- months, amounting 2.6 ± 0.4 mm, and 2.9 ± 0.4 mm, respectively ($p < 0.001$), while mean CAL gain measured 2.3 ± 0.5 mm at 3- months, and 2.6 ± 0.5 mm at 6-months in comparison to baseline ($p < 0.001$). Mean reduction of BOP values amounted to 54.9 ± 16.9% at 3- months, and to 65.6 ± 16.4% at 6-months, respectively ($p < 0.001$). The number of moderate pockets (4–5 mm) reduced from 1808 at baseline to 274 at 6 months evaluation, and the number of deep (≥ 6 mm) pockets changed from 319 to 3, respectively [31]. These results compare well to those obtained in the present study, thus pointing to the potential clinical relevance of this novel clinical protocol.

Moreover, the adjunctive application of sodium hypochlorite/amino acid and hyaluronic acid gels to SRP has been tested separately in several clinical studies. On one hand, a recent clinical trial has evaluated the effect of the adjunctive application of sodium hypochlorite gel to SRP in residual periodontal pockets [9]. The findings revealed statistically significant PD reduction favouring the used of the sodium hypochlorite/amino acid gel, compared to a placebo ($p = 0.028$), as well as a statistically significant CAL gain at 6 months in the NaOCl-treated group, compared to the application of CHX gel ($p = 0.0026$).

One the other hand, the results of the studies on the adjunctive application of hyaluronic acid to non-surgical periodontal therapy are inconsistent. For instance, some of the studies found statistically significant improvements for the adjunctive application of hyaluronic acid to SRP in terms of PD and BOP reductions and CAL gain [27, 29], whereas in other studies adjunctive application of hyaluronic acid did not reach statistically significant differences in the investigated clinical parameters compared to SRP alone [36, 37].

Obviously, when interpreting the current results, certain the following limitations need to be mentioned: a) the study included a relatively small sample size and was of relatively short duration (i.e., 6 months), and b) only systemically healthy, non-smoking patients diagnosed with periodontitis stages II and III exhibiting adequate oral hygiene skills were included in the study.

Conclusion

Within their limits the present data indicate that: a) Both treatments resulted in statistically significant improvements in all evaluated clinical parameters, and b) The adjunctive subgingival application of sodium hypochlorite/amino acid gel and xHyA to SRP yielded statistically significantly higher improvements compared to SRP alone.

Acknowledgements The authors thank Regedent (Zurich, Switzerland) for providing the sodium hypochlorite/amino acid and cross-linked hyaluronic acid gels used for the study.

Author contributions Egle Ramanauskaite contributed to study design, data acquisition and interpretation, manuscript drafting and revision. Vita Machiulskiene contributed to manuscript drafting and revision. Yoshinori Shirakata contributed to manuscript drafting and revision. Urte Marija Dvyliene contributed to data acquisition and to manuscript drafting and revision. Irena Nedzelskiene contributed to data acquisition and statistical analysis. Anton Sculean contributed to study conception, design and supervision, data interpretation, manuscript drafting and revision. All authors gave their final approval and agreed to be accountable for all aspects of the work.

Funding This work was funded by Foundation of Science of Lithuanian University of Health Sciences.

Data availability All data underlying the results are available as part of the article and no additional source data is applicable.

Declarations

Competing interests The authors declare no competing interests.

Conflicts of Interest The authors declare no potential conflict of interest with respect to the authorship and/or publication of this article.

References

1. Belibasakis GN, Belstrøm D, Eick S, Gursoy UK, Johansson A, Könönen E (2023) Periodontal microbiology and microbial etiology of periodontal diseases: historical concepts and contemporary perspectives. Periodontol 2000. https://doi.org/10.1111/prd.12473
2. Borisy GG (2000) Valm AM (2021) Spatial scale in analysis of the dental plaque microbiome. Periodontol 86:97–112
3. Joseph S (2000) Curtis MA (2021) Microbial transitions from health to disease. Periodontol 86:201–209
4. Sedghi L, DiMassa V, Harrington A, Lynch SV (2000) Kapila YL (2021) The oral microbiome: Role of key organisms and complex networks in oral health and disease. Periodontol 87:107–131
5. Papapanou PN, Sanz M, Buduneli N, Dietrich T, Feres M, Fine DH, Flemmig TF, Garcia R, Giannobile WV, Graziani F, Greenwell H, Herrera D, Kao RT, Kebschull M, Kinane DF, Kirkwood KL, Kocher T, Kornman KS, Kumar PS, Loos BG, Machtei E, Meng H, Mombelli A, Needleman I, Offenbacher S, Seymour GJ, Teles R, Tonetti MS (2018) Periodontitis: Consensus report of workgroup 2 of the 2017 World Workshop on the Classification of Periodontal and Peri-Implant Diseases and Conditions. J Periodontol 89(Suppl 1):S173–S182
6. Darveau RP (2000) Curtis MA (2021) Oral biofilms revisited: A novel host tissue of bacteriological origin. Periodontol 86:8–13
7. Jakubovics NS, Goodman SD, Mashburn-Warren L, Stafford GP, Cieplik F (2021) The dental plaque biofilm matrix. Periodontol 2000(86):32–56
8. Sanz M, Herrera D, Kebschull M, Chapple I, Jepsen S, Beglundh T, Sculean A, Tonetti MS, Workshop Participants EFP, Consultants M (2020) Treatment of stage I-III periodontitis-The EFP S3 level clinical practice guideline. J Clin Periodontol 47(Suppl 22):4–60
9. Bonito AJ, Lux L, Lohr KN (2005) Impact of local adjuncts to scaling and root planing in periodontal disease therapy: a systematic review. J Periodontol 76:1227–1236
10 Ramanauskaite E, Machiulskiene V (2020) Antiseptics as adjuncts to scaling and root planing in the treatment of periodontitis: a systematic literature review. BMC Oral Health 20:143-020–01127-1
11. Ramanauskaite E, Sakalauskaite UM, Machiulskiene V (2020) The Efficacy of Adjunctive Aids in Periodontal Maintenance Therapy: A Systematic Literature Review and Meta-analysis. Oral Health Prev Dent 18:889–910
12. Smiley CJ, Tracy SL, Abt E, Michalowicz BS, John MT, Gunsolley J, Cobb CM, Rossmann J, Harrel SK, Forrest JL, Hujoel PP, Noraian KW, Greenwell H, Frantsve-Hawley J, Estrich C, Hanson N (2015) Systematic review and meta-analysis on the nonsurgical treatment of chronic periodontitis by means of scaling and root planing with or without adjuncts. J Am Dent Assoc 146:508–24.e5
13. Jurczyk K, Nietzsche S, Ender C, Sculean A, Eick S (2016) In-vitro activity of sodium-hypochlorite gel on bacteria associated with periodontitis. Clin Oral Investig 20:2165–2173
14. Roos-Jansåker AM, Almhöjd US, Jansson H (2017) Treatment of peri-implantitis: clinical outcome of chloramine as an adjunctive to non-surgical therapy, a randomized clinical trial. Clin Oral Implants Res 28:43–48
15. Megally A, Zekeridou A, Cancela J, Giannopoulou C, Mombelli A (2020) Short ultrasonic debridement with adjunctive low-concentrated hypochlorite/amino acid gel during periodontal maintenance: randomized clinical trial of 12 months. Clin Oral Investig 24:201–209
16. Radulescu V, Boariu MI, Rusu D, Roman A, Surlin P, Voicu A, Didilescu AC, Jentsch H, Siciliano VI, Ramaglia L, Vela O, Kardaras G, Sculean A, Stratul SI (2022) Clinical and microbiological effects of a single application of sodium hypochlorite gel during subgingival re-instrumentation: a triple-blind randomized placebo-controlled clinical trial. Clin Oral Investig 26(11):6639–6652. https://doi.org/10.1007/s00784-022-04618-3
17. Iorio-Siciliano V, Blasi A, Stratul SI, Ramaglia L, Sculean A, Salvi GE, Rusu D (2020) Anti-infective therapy of peri-implant mucositis with adjunctive delivery of a sodium hypochlorite gel: a 6-month randomized triple-blind controlled clinical trial. Clin Oral Investig 24:1971–1979
18. Fakhari A, Berkland C (2013) Applications and emerging trends of hyaluronic acid in tissue engineering, as a dermal filler and in osteoarthritis treatment. Acta Biomater 9:7081–7092
19. Deed R, Rooney P, Kumar P, Norton JD, Smith J, Freemont AJ, Kumar S (1997) Early-response gene signalling is induced by angiogenic oligosaccharides of hyaluronan in endothelial cells. Inhibition by non-angiogenic, high-molecular-weight hyaluronan. Int J Cancer 71:251–256
20. Asparuhova MB, Kiryak D, Eliezer M, Mihov D, Sculean A (2019) Activity of two hyaluronan preparations on primary human oral fibroblasts. J Periodontal Res 54:33–45
21. Longaker MT, Chiu ES, Adzick NS, Stern M, Harrison MR, Stern R (1991) Studies in fetal wound healing. V. A prolonged presence of hyaluronic acid characterizes fetal wound fluid. Ann Surg 213:292–296
22. Pirnazar P, Wolinsky L, Nachnani S, Haake S, Pilloni A, Bernard GW (1999) Bacteriostatic effects of hyaluronic acid. J Periodontol 70:370–374
23. Shirakata Y, Imafuji T, Nakamura T, Kawakami Y, Shinohara Y, Noguchi K, Pilloni A, Sculean A (2021) Periodontal wound healing/regeneration of two-wall intrabony defects following reconstructive surgery with cross-linked hyaluronic acid-gel with or without a collagen matrix: a preclinical study in dogs. Quintessence Int 0:308–316. https://doi.org/10.3290/j.qi.b937003
24. Shirakata Y, Imafuji T, Nakamura T, Shinohara Y, Iwata M, Setoguchi F, Noguchi K, Sculean A (2022) Cross-linked hyaluronic acid gel with or without a collagen matrix in the treatment of class III furcation defects: A histologic and histomorphometric study in dogs. J Clin Periodontol 49:1079–1089

25. Shirakata Y, Nakamura T, Kawakami Y, Imafuji T, Shinohara Y, Noguchi K, Sculean A (2021) Healing of buccal gingival recessions following treatment with coronally advanced flap alone or combined with a cross-linked hyaluronic acid gel. An experimental study in dogs. J Clin Periodontol 48:570–580
26. Chauhan AS, Bains VK, Gupta V, Singh GP, Patil SS (2013) Comparative analysis of hyaluronan gel and xanthan-based chlorhexidine gel, as adjunct to scaling and root planing with scaling and root planing alone in the treatment of chronic periodontitis: A preliminary study. Contemp Clin Dent 4:54–61
27. Eick S, Renatus A, Heinicke M, Pfister W, Stratul SI, Jentsch H (2013) Hyaluronic Acid as an adjunct after scaling and root planing: a prospective randomized clinical trial. J Periodontol 84:941–949
28. Johannsen A, Tellefsen M, Wikesjö U, Johannsen G (2009) Local delivery of hyaluronan as an adjunct to scaling and root planing in the treatment of chronic periodontitis. J Periodontol 80:1493–1497
29. Rajan P, Baramappa R, Rao NM, Pavaluri AK, P I, Rahaman SM, (2014) Hyaluronic Acid as an adjunct to scaling and root planing in chronic periodontitis. A randomized clinical trail. J Clin Diagn Res 8:ZC11-4
30. Diehl D, Friedmann A, Liedloff P, Jung RM, Sculean A, Bilhan H (2022) Adjunctive Application of Hyaluronic Acid in Combination with a Sodium Hypochlorite Gel for Non-Surgical Treatment of Residual Pockets Reduces the Need for Periodontal Surgery-Retrospective Analysis of a Clinical Case Series. Materials (Basel) 15:6508. https://doi.org/10.3390/ma15196508
31. Ramanauskaite E, Dvyliene UM, Machiulskiene V, Eliezer M, Sculean A (2023) Clinical evaluation of a novel combination of sodium hypochlorite/amino acid and cross-linked hyaluronic acid adjunctive to non-surgical periodontal treatment: A case series. Oral Health Prev Dent 21(1):279–284. https://doi.org/10.3290/j.ohpd.b4347453
32. Schulz KF, Altman DG, Moher D, CONSORT Group (2010) CONSORT 2010 statement: updated guidelines for reporting parallel group randomized trials. Ann Intern Med 152:726–732
33. De Boulle K, Glogau R, Kono T, Nathan M, Tezel A, Roca-Martinez J, Paliwal S, Stroumpoulis D (2013) A review of the metabolism of 1,4-butanediol diglycidyl ether-crosslinked hyaluronic acid dermal fillers. Dermatol Surg 39:1758–1766
34. Chapple ILC, Mealey BL, Van Dyke TE, Bartold PM, Dommisch H, Eickholz P, Geisinger ML, Genco RJ, Glogauer M, Goldstein M, Griffin TJ, Holmstrup P, Johnson GK, Kapila Y, Lang NP, Meyle J, Murakami S, Plemons J, Romito GA, Shapira L, Tatakis DN, Teughels W, Trombelli L, Walter C, Wimmer G, Xenoudi P, Yoshie H (2018) Periodontal health and gingival diseases and conditions on an intact and a reduced periodontium: Consensus report of workgroup 1 of the 2017 World Workshop on the Classification of Periodontal and Peri-Implant Diseases and Conditions. J Periodontol 89(Suppl 1):S74–S84
35. Salvi GE, Mombelli A, Mayfield L, Rutar A, Suvan J, Garrett S, Lang NP (2002) Local antimicrobial therapy after initial periodontal treatment. J Clin Periodontol 29:540–550
36. Pilloni A, Rojas MA, Trezza C, Carere M, De Filippis A, Marsala RL, Marini L (2022) Clinical effects of the adjunctive use of a polynucleotides and hyaluronic acid based gel in the subgingival re-instrumentation of residual periodontal pockets: A randomized, split-mouth clinical trial. J Periodontol 94(3):354–363
37. Pilloni A, Zeza B, Kuis D, Vrazic D, Domic T, Olszewska-Czyz I, Popova C, Kotsilkov K, Firkova E, Dermendzieva Y, Tasheva A, Orrù G, Sculean A, Prpić J (2021) Treatment of Residual Periodontal Pockets Using a Hyaluronic Acid-Based Gel: A 12 Month Multicenter Randomized Triple-Blinded Clinical Trial. Antibiotics (Basel) 10:924. https://doi.org/10.3390/antibiotics10080924

Authors and Affiliations

Egle Ramanauskaite[1] · Vita Machiulskiene[1] · Yoshinori Shirakata[2] · Urte Marija Dvyliene[1] · Irena Nedzelskiene[1] · Anton Sculean[3]

✉ Egle Ramanauskaite
egle.ramanauskaite@lsmuni.lt

[1] Clinic of Dental and Oral Pathology, Lithuanian University of Health Sciences, Eiveniu 2, 50103 Kaunas, Lithuania

[2] Department of Periodontology, Kagoshima University Graduate School of Medical and Dental Sciences, Kagoshima, Japan

[3] Department of Periodontology, University of Bern, Bern, Switzerland

Clinical Oral Investigations
https://doi.org/10.1007/s00784-023-05121-z

RESEARCH

In vitro activity of hyaluronic acid and human serum on periodontal biofilm and periodontal ligament fibroblasts

Xilei Zhu[1] · Livia von Werdt[1] · Graziano Zappalà[1] · Anton Sculean[1] · Sigrun Eick[1] · Alexandra Stähli[1]

Received: 31 January 2023 / Accepted: 8 June 2023

Abstract

Objectives A beneficial effect of cross-linked hyaluronic acid (cHA) on periodontal wound healing and regeneration has recently been demonstrated. The present in vitro study was designed to obtain deeper knowledge on the effect of cHA when applied in the gingival sulcus (serum-rich environment) during non-surgical periodontal therapy.

Materials and methods The influence of cHA, human serum (HS), and cHA/HS on (i) a 12-species biofilm formation, (ii) the adhesion of periodontal ligament fibroblasts (PDLF) to dentine surface, (iii) the expression and secretion of interleukin-8, and (iv) the expression of receptors of HA in PDLF and gingival fibroblasts (GF) were evaluated.

Results At 4 h of biofilm formation, cHA and HS in combination (cHA/HS) slightly decreased the colony-forming unit counts in biofilm whereas the metabolic activity of biofilm was reduced in all test groups (cHA, HS, cHA/HS) vs. control. At 24 h, the quantity of biofilm was reduced in all test groups vs. untreated control. The test substances did not affect adhesion of PDLF to dentin. HS increased the expression of IL-8 by PDLF and GF which was partially downregulated by cHA. HS and/or cHA promoted the expression of the HA receptor RHAMM in GF but not in PDLF.

Conclusions In summary, the present data indicate that serum neither negatively affect the activity of cHA against periodontal biofilm nor had any unwanted influence on the activity of PDLF.

Clinical relevance These findings lend additional support for the positive effects of cHA on cells involved in periodontal wound healing, thus pointing to its potential use in non-surgical periodontal therapy.

Keywords Periodontal therapy · Cross-linked hyaluronic acid · Periodontal ligament fibroblasts · Gingival fibroblasts · Interleukin-8 · Antibiofilm activity

Introduction

Hyaluronic acid (HA), also named hyaluronan, is a glycosaminoglycan and a major component of the extracellular matrix of vertebrate tissues, abundant in almost all body fluids such as synovial fluid or serum [1]. It is synthesized as a high-molecular weight polymer of 1000–6000 kDa, but can be degraded to low-molecular weight of less or equal 250 kDa or further fragmented to oligos [1]. In medicine, HA has become increasingly important as formulations used in wound healing, the treatment of osteoarthritis or of respiratory and urinary tract infections, and in tissue and regenerative medicine [2]. With respect to the oral cavity, HA is present in saliva [3], gingival crevicular fluid [4], and the soft periodontal tissues [5].

Periodontitis, a disease leading to the destruction of the tooth-supporting tissues, is characterized by an interaction of a dysbiotic biofilm with host response leading to an ongoing inflammatory state [6–8]. Therapy of periodontitis always includes the removal of the subgingival biofilm [9]. The subgingival area of a teeth is bathed in the gingival crevicular fluid, which corresponds to a serum transudate in periodontal health and a serum exudate in periodontal disease [10]. It contains many factors, e.g., immunoglobulins, antimicrobial peptides, or proteases, being involved in the immune response [11]. Periodontal ligament fibroblasts play a special part in periodontal tissue regeneration in the first place by establishing a new attachment [12]. Moreover, they are central players in innate immunity as in inflammation

Sigrun Eick and Alexandra Stähli both share the last position.

✉ Alexandra Stähli
alexandra.staehli@unibe.ch

[1] Department of Periodontology, School of Dental Medicine, University of Bern, Bern, Switzerland

they produce many mediators including proinflammatory cytokines such as interleukin (IL)-8 [13].

In vitro data have shown that a cross-linked hyaluronic acid (cHA) enhanced the expression of genes encoding type III collagen and transforming growth factor-β3, characteristic of scarless wound healing. Moreover, the cHA upregulated the expression of genes encoding pro-proliferative, pro-migratory, and proinflammatory factors and positively influenced the proliferative, migratory, and wound healing properties of different cell types involved in periodontal wound healing/regeneration [14]. These positive biologic effects of cHA on periodontal ligament cells have recently been confirmed in a series of experimental studies providing histological evidence for periodontal regeneration in intrabony, recession, and furcation defects following regenerative surgery and application of cHA [15–17]. Results from controlled clinical studies have provided further evidence on the potential clinical relevance of using cHA in regenerative periodontal surgery in intrabony and recession defects [18, 19].

Systematic reviews underlined a beneficial effect of HA on clinical outcomes (periodontal probing depth (PPD) reduction, less bleeding on probing (BOP), clinical attachment level (CAL) gain) of surgical and non-surgical periodontal therapy [20, 21]. In the included studies, different formulations of high-molecular weight HA and of different origins were applied [21]. In a recent RCT, a gel formulation was used which contained mainly cross-linked high-molecular weight HA added by a small amount of natural high-molecular weight HA [22]. After 3 months of non-surgical periodontal therapy, differences in BOP and PPD reduction were clearly in favor of the HA-treated group [22]. Using adjunctively the gel formulation in residual pockets resulted in by trend (not statistically significant) better results vs. instrumentation alone after 12 months [23].

The aim of this in vitro study was to get deeper knowledge of the effect of cHA when applied in the gingival sulcus during non-surgical periodontal therapy. The focus was on the interaction of microorganisms and periodontal fibroblasts against the background that serum is an essential component of gingival crevicular fluid. We analyzed the influence of cHA on (i) biofilm formation, (ii) the adhesion of periodontal ligament fibroblasts to tooth surface, (iii) the expression and secretion of interleukin-8, and (iv) the expression of receptors of HA in periodontal fibroblasts.

Materials and methods

HA and human serum preparation

As hyaluronic acid formulation a commercially available product (Hyadent BG®, Regedent AG, Zurich, Switzerland) was used. According to the manufacturer's information, the product (cHA) contains 16 mg cross-linked HA (molecular weight of about 1000 kDa) and 2 mg natural HA per ml.

Human serum (HS) was purchased from Sigma-Aldrich (Merk KGaA, Darmstadt, Germany). In the assays, cHA was used in concentrations of 12.5 mg/ml (0.225 mg/ml HA), 25 mg/ml (0.45 mg/ml HA), and 50 mg/ml (0.9 mg/ml HA) and HS in concentrations of 12.5 mg/ml, 25 mg/ml, and 50 mg/ml. When cHA was used in combination with serum (cHA/HS), the respective concentrations each of both were 12.5 mg/ml, 25 mg/ml, and 50 mg/ml. A 0.9% w/v NaCl solution was the negative control.

Microorganisms

A 12-species periodontal biofilm was used in this study:

1. *Streptococcus gordonii* ATCC 10558
2. *Actinomyces naeslundii* ATCC 12104
3. *Fusobacterium nucleatum* ATCC 25586
4. *Campylobacter rectus* ATCC 33238
5. *Parvimonas micra* ATCC 33270
6. *Eikenella corrodens* ATCC 23834
7. *Treponema denticola* ATCC 35405
8. *Prevotella intermedia* ATCC 25611
9. *Capnocytophaga gingivalis* ATCC 33624
10. *Porphyromonas gingivalis* ATCC 33277
11. *Tannerella forsythia* ATCC 43037
12. *Filifactor alocis* ATCC 33099

All strains (except for *T. denticola* which was maintained in Mycoplasma broth (BD, Franklin Lake, NJ)) were cultured on Schaedler agar plates (Oxoid, Basingstoke, UK) with 5% sheep blood, in an anaerobic incubator or with 5% CO_2 (*S. gordonii*) at 37 °C. The bacteria were suspended in 0.9% w/v NaCl according to McFarland 4. One part *S. gordonii* was mixed with two parts *A. naeslundii,* and four parts of the other nine species.

Cell culture

Human gingival fibroblasts (GF) and human periodontal ligament fibroblasts (PDLF) were harvested from freshly extracted and donated teeth from patients who had been informed of the use of their teeth for research purposes and signed written agreement. As these biomaterials were irreversibly anonymized, no additional approval of the Cantonal ethical committee (KEK) was needed according to the respective guidelines.

The procedure was as described recently [24, 25]. GF and PDLF were cultured in DMEM (Invitrogen, Carlsbad, CA, USA) supplemented with 10% fetal bovine serum (FBS;

Invitrogen). For experiments, cells were used between the third and fifth passage. Cells from two donors were included.

All cells were incubated with 5% CO_2 at 37 °C.

Activity on periodontal biofilm formation

First, wells of 96-well plates were coated with each 10 µl 1.5% bovine serum albumin (BSA, SERVA Electrophoresis GmbH, Heidelberg, Germany) in phosphate-buffered saline (PBS) for 1 h to generate a proteinaceous layer. Then, 10 µl of test substances (cHA, HS, cHA/HS, final concentration each 50 mg/ml) and the control were added for 30 min incubation. Thereafter, microbial suspension mixed with cultivation broth (Wilkins–Chalgren broth, Oxoid, Basingstoke, UK) in a volume ratio of 1:9 was additionally added, i.e., 200 µl per well. Thereafter, the plates were incubated in an anaerobic incubator, 37 °C for 4 h or 24 h.

At 4 h and 24 h, three different aspects of periodontal biofilm formation were measured: (a) colony-forming units (cfus), (b) biofilm mass, and (c) metabolic activity. Then, following a short, careful washing, 100 µl of 0.9% w/v NaCl were added. Biofilms were scraped from the surface and mixed. One aliquot of the suspension was serially diluted, plated on Schaedler agar plates. The cfus were counted after 8 days of anaerobic incubation. Biofilm quantity was measured by using crystal violet staining, and metabolic activity was determined by Alamar blue staining assay as described before [25].

Activity on adhesion of PDL fibroblasts to dentine specimens

The dentin discs (about 4 × 4 × 1 mm) were prepared as described recently [26]. The teeth were donated from patients who had been informed of the use of their teeth for research purposes and signed written agreement. As these biomaterials were irreversibly anonymized, no additional approval of the Cantonal ethical committee (KEK) was needed according to the respective guidelines. The dentine discs were placed in 24-well plates in the laminar flow. Then the discs of the serum groups (HS, CHA/HS) were coated with 10 µl of serum (undiluted) for 5 min in the laminar flow and thereafter those of the cHA groups (cHA, CHA/HS) with 10 µl of cHA (undiluted for 5 min). The controls were left uncoated.

Detached PDL fibroblasts were suspended in cell culture (with 1% FBS) to a density of 5×10^6/ml. After a short dipping of the test specimens into 0.9% w/v NaCl, each 1 ml of the cell suspension were added per well. The plates have been incubated with 5% CO_2 for 72 h. Then after short washing and fixing the cells with methanol, the attached cells were counted. The results represent the mean of 10 fields (mm^2). The statistical unit was the dentine specimen.

Release and expression of interleukin-8 and HA receptors by gingival and PDL fibroblasts

For determining cytokine level, each well of 48-well plates was covered with 25 µl of the test substances (final concentrations 12.5 mg/ml, 25 mg/ml, and 50 mg/ml each) for 30 min incubation (RT). Afterwards, 225 µl cell suspension was added at a density of 5×10^5 cells/well (GF and PDLF). After 18 h of incubation (37 °C, 5% CO_2), the media were collected and centrifuged. From the supernatants, the protein level of IL-8 was quantified by ELISA kits (R&D Systems Europe Ltd., Abingdon, UK) following the manufacturer's instructions.

For measuring mRNA expression of the cytokine IL-8 and also of the HA receptors (CD44, RHAMM, TLR2, and TLR4), GF and PDLF were seeded into 6-well plates at a density of 5×10^5 cells/well for 18 h. Then, after careful washing, culture medium with 0.5% FBS and the test substances in concentrations of each 25 mg/ml were added for 1 h. After 3 times PBS wash, total RNA was extracted following the instruction of innuPREP RNA Mini Kit 2.0 (Analytic Jena GmbH, Jena, Germany). Then, the GoScript™ Reverse Transcription System (Promega, Madison, WI, USA) was used to reverse 1000 ng RNA into cDNA. Quantitative RT-PCR was carried out by GoTaq® qPCR Master Mix (Promega) with the QuantStudio 3 Real-Time PCR System (Thermo Fischer, Waltham, MA, USA) to determine the mRNA expression level of the cytokine IL-8, and HA receptor genes (CD44, RHAMM). The primer sets are given in Table 1. Gene expression was normalized by GAPDH and analyzed by the $2^{-\Delta\Delta CT}$ method.

Statistical analysis

All experiments were performed in at least two independent experiments in each quadruplicate (eight independent biological samples). Log_{10} transformation was used in the case of cfu counts.

Statistical analysis was performed with Kruskal–Wallis test and followed by Mann–Whitney *U* test (with Bonferroni correction) using SPSS 26.0 (IBM Corporation, New York, NY, USA). For qRT-PCR results, one-way ANOVA and Dunnett's multiple comparisons test were carried out by Graphpad Prism 9 (Graphpad Software, California, USA). Statistical significance was set at $p < 0.05$.

Table 1 Primer sequences used for qRT-PCR

Gene	Forward/reverse primers	Primer sequences 5'-3'	References
IL-8	F	GAG AGT GAT TGA GAG GTG GAC CAC	[27]
	R	CAC AAC CCT CTG CAC CCA GTT T	
CD44	F	GAC CTC TGC AAG GCT TTC AAT A	# M59040.1
	R	CAA AGG CAT TGG GCA GGT CT	
RHAMM	F	AGG ACC AGT ATC CTT TCA GAA ATC	# BC017793.1
	R	AGT GCA GCA TTT AGC CTT GC	
GAPDH	F	GAC AGT CAG CCG CAT CTT CT	[28]
	R	TTA AAA GCA GCC CTG GTG AC	

Results

Periodontal biofilm formation

In median, the untreated biofilm consisted of 6.59 log10 cfu at 4 h and of 8.90 log10 cfu at 24 h.

When applying test substances, there were only minor differences in the cfu counts. The highest difference vs. control was − 0.36 log10, when 50 mg/ml cHA/HS were applied at 4 h ($p < 0.001$; Fig. 1a). At 24 h, all test substances increased the cfu counts; however, differences were in median 0.10 log10 (cHA, $p = 0.483$) to 0.13 log10 (HS, $p = 0.015$).

In terms of biofilm quantity (Fig. 1b), at 4 h, both cHA and cHA/HS groups had higher values compared to the control group (each $p < 0.001$). The quantity of biofilm in HS group decreased ($p = 0.009$). However, at 24 h, the quantity of biofilm was reduced in all test groups vs. untreated control ($p < 0.001$ each).

In all test groups, the metabolic activity of the biofilm was reduced compared to the control at 4 h ($p < 0.001$ each). At 24 h, no difference was found anymore (Fig. 1c).

HA and attachment of PDL fibroblasts to dentin

An important step in the resolution of periodontal tissue destruction is a promoted adhesion of fibroblasts to tooth surfaces in the periodontal pocket. Here, the influence of HS and cHA on the number of adhered PDL fibroblasts was studied. There was a minor trend (not statistically significant) to a reduced attachment when the surface was coated with cHA. In case of coating with HS and cHA/HS, the numbers remained unchanged (Fig. 2).

HA receptors expression in oral fibroblasts

Two crucial HA receptor genes were checked in gingival and PDL fibroblasts. Each 25 mg/ml of test substances (HS, cHA) were used for the mRNA expression experiments.

The analyzed receptors (CD44, RHAMM) were expressed by both fibroblast types. An influence by the test substances was minor despite reaching in part statistical significance. In gingival fibroblasts (Fig. 3a), all test groups (cHA, HS, cHA/HS) increased the mRNA expression of RHAMM ($p = 0.003$, $p = 0.003$, $p = 0.001$). In PDL fibroblasts (3b), the receptors' mRNA expression did not statistically significantly differ among the groups.

Interleukin-8 expression in oral fibroblasts

Both mRNA expression and protein expression of interleukin-8 (IL-8) were measured in GF and PDLF, in which 25 mg/ml cHA and HS were used for mRNA expression whilst 5, 25, and 50 mg/ml were used for protein expression.

As shown in Fig. 4a and c, cHA decreased the mRNA expression of IL-8 in the two fibroblast types (GF: $p < 0.001$, PDLF: $p = 0.005$). At protein level, there was no statistically significant difference for any of the tested cHA concentrations vs. control neither with GF nor PDLF. In contrast, HS significantly increased IL-8 expression in GF and PDLF at the mRNA level ($p = 0.001$, $p = 0.009$). At protein level, results were accordingly, after each tested concentration of cHA higher IL-8 levels were measured vs. non-stimulated GF and PDLF cells (each $p < 0.001$). Also, when cHA was combined with serum, the released levels of IL-8 from GF and PDLF were always higher than from the control (each $p < 0.001$). When comparing the high levels of IL-8 after HS stimulation with those after cHA/HS, the combination with cHA decreased the mRNA expression (GF: $p < 0.001$, PDLF: $p = 0.002$) and also the protein expression (GF all concentrations $p < 0.001$, PDLF 12.5 mg/ml HS vs. 12.5 mg cHA/HS $p < 0.001$, 50 mg/ml HS vs. 50 mg cHA/HS $p = 0.001$).

Discussion

The present in vitro study has analyzed the effects of a commercial HA product on a periodontal biofilm and periodontal fibroblasts. A product topically used in non-surgical periodontal therapy should inhibit biofilm formation, and,

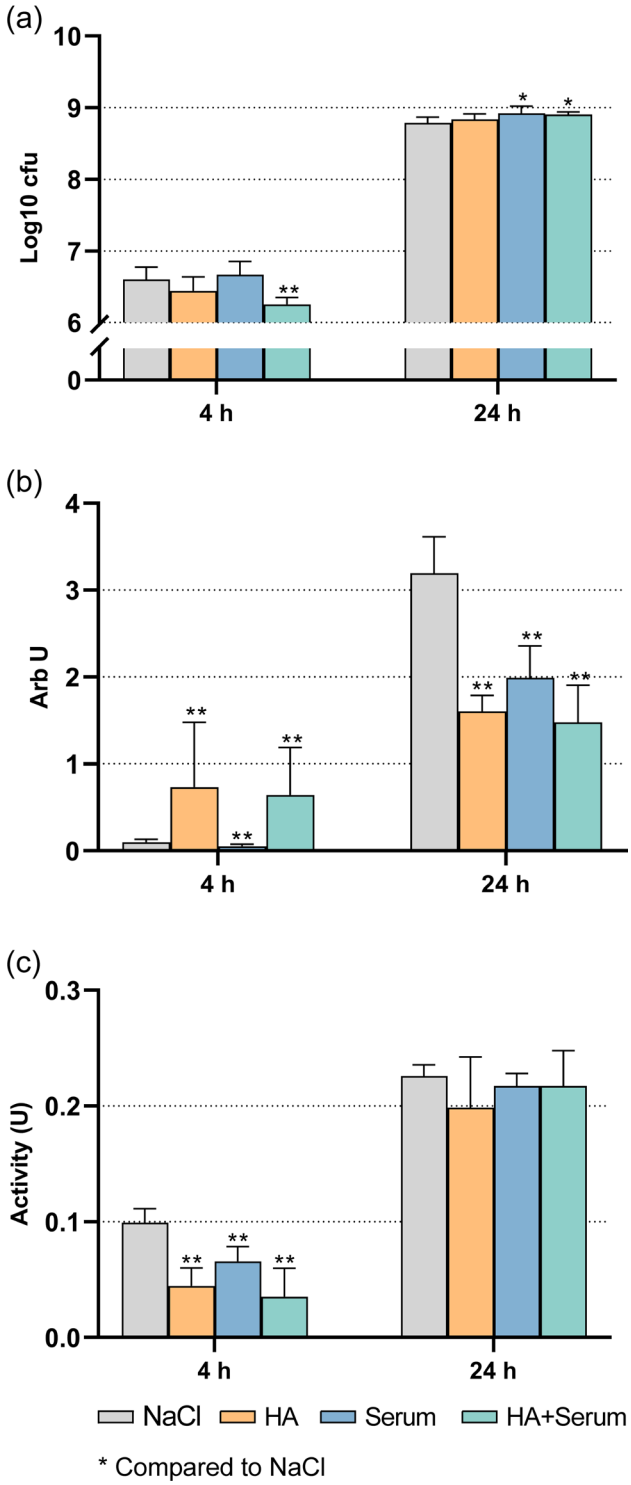

Fig. 1 Influence of coating with 50 mg/ml hyaluronic acid (cHA), human serum (HS), and each 50 mg/ml hyaluronic acid/human serum (cHA/HS) on periodontal biofilm formation after 4 h and 24 h. **a** Colony-forming units (cfu); **b** quantity; **c** metabolic activity. Median incl. 25 and 75 percentiles; $*p<0.05$, $**p<0.01$ vs. control

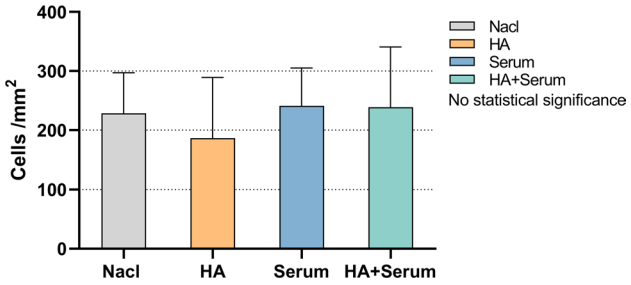

Fig. 2 Influence of coating dentine surfaces with hyaluronic acid (cHA), human serum (HS), and hyaluronic acid/human serum (cHA/HS) on attachment of periodontal ligament fibroblasts. Mean and SD

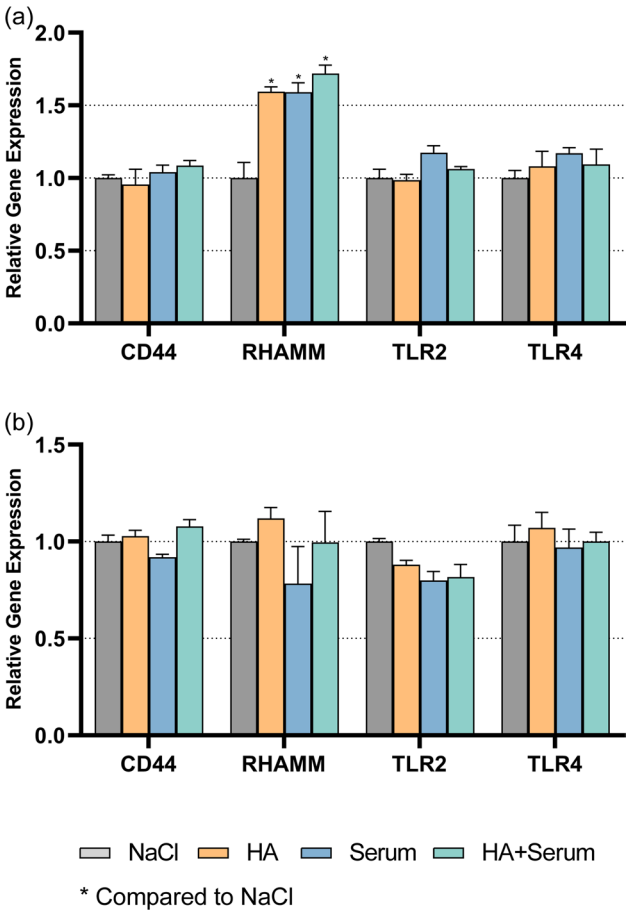

Fig. 3 Influence of 25 mg/ml hyaluronic acid (cHA), human serum (HS), and each 25 mg/ml hyaluronic acid/human serum (cHA/HS) on mRNA expression of hyaluronic acid receptors (CD44, RHAMM) in **a** gingival fibroblasts (GF), and **b** periodontal ligament fibroblasts (PDLF). Mean ± SD, $*p<0.05$, $**p<0.01$ vs. control

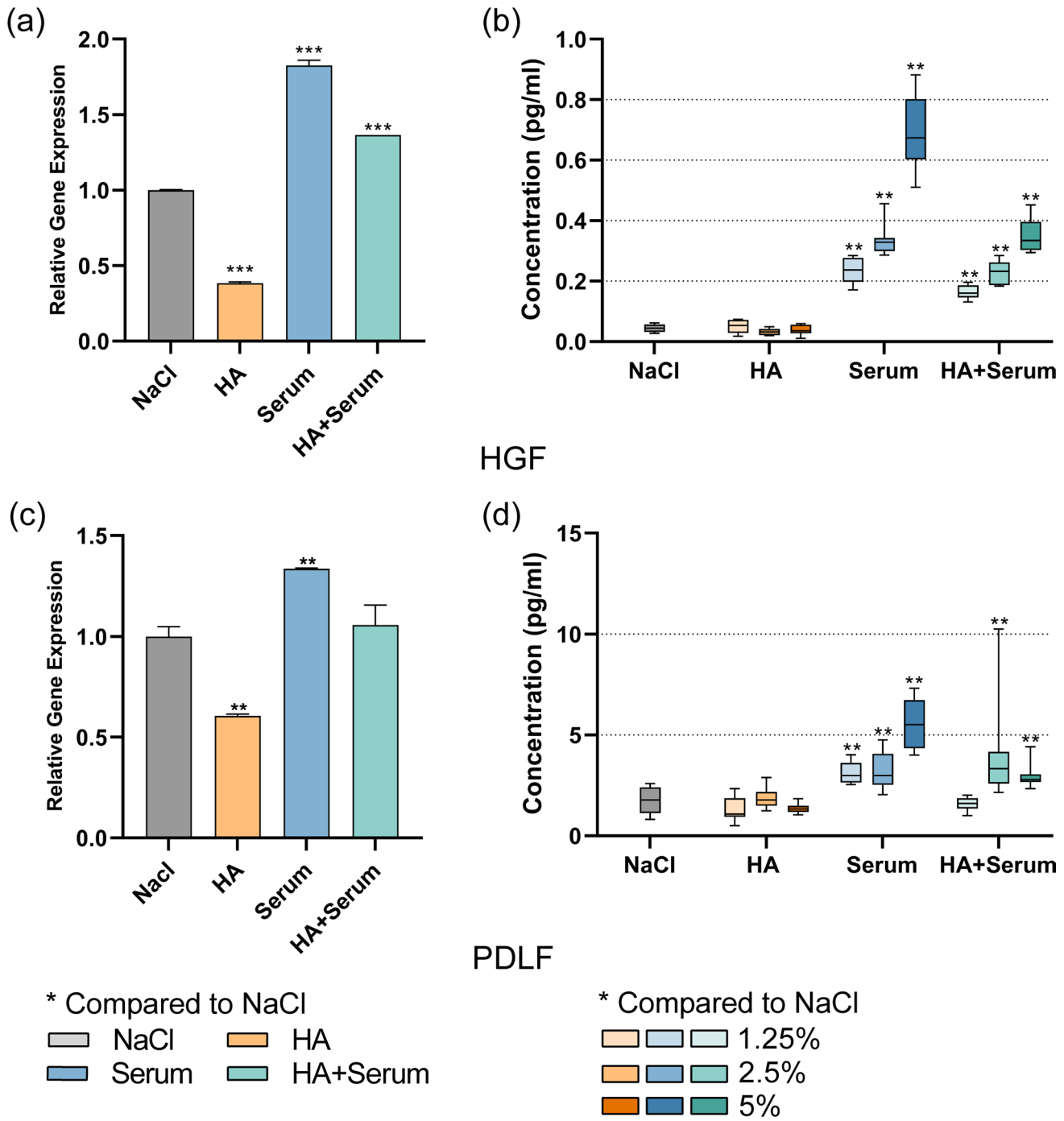

Fig. 4 Influence of hyaluronic acid (cHA), human serum (HS), and hyaluronic acid/human serum (cHA/HS) on mRNA expression (**a**, **c**) and protein level (**b**, **d**) of interleukin-8 in **a**, **b** gingival fibroblasts, and **c**, **d** periodontal ligament fibroblasts. mRNA expression: mean ± SD, protein: median incl. 25 and 75 percentiles. *$p < 0.05$, **$p < 0.01$ vs. control

at the same time, positively affect the healing/regenerative potential of the host cells. Gingival crevicular fluid does contain not only serum, but also, besides the presence of serum proteins, a number of other markers involved in the innate and acquired immune response [29].

The results of the present study have shown that both cHA and HS interfered with initial biofilm formation; however, they did not affect adhesion of PDLF to dentin. A further finding was that HS increased the expression of IL-8 by periodontal fibroblasts which was partially downregulated by cHA.

In biofilm formation, bacterial counts were only minorly affected. The strongest effect occurred at 4 h when the surface was coated both with cHA and HS. Interestingly, the results on biofilm quantity were more remarkable. Initially, cHA increased the biofilm quantity since it was probably incorporated in the matrix of the multi-species biofilm. However, at 24 h, the quantity was reduced when the surface was coated with cHA and/or HS. Recently, it was reported that HS inhibited biofilm formation of pathogens including *Staphylococcus aureus*, *Staphylococcus epidermidis*, and *Pseudomonas aeruginosa* although it did not affect planktonic growth, but the addition of an antibiofilm compound could reverse this effect [30]. In the present study, an increased inhibitory effect of cHA on HS was found. Interactions of HS albumin with HA can enlarge the binding ability of HA, as some positive divalent cations, e.g., Ca^{2+}, increase the affinity between them and contribute to lubrication [31]. Reported results on HA influence on biofilm formation are controversial. When adding HA on single-species biofilms of respiratory pathogens continuously less biofilm was quantified, the finding was discussed as a disaggregation of the matrix [32]. Also linking a polymethacrylate surface with HA reduced the adhesion of *Staphylococcus epidermidis* [33]. But using HA synthesized by *Streptococcus equi* promoted biofilm formation of *Streptococcus pneumonia* [34]. Regarding bacteria being associated with periodontal disease, recently a decrease by 60% (0.4 log10) of viable counts of *P. gingivalis* after 72 h of biofilm formation was mentioned [35]. An interesting approach seems to be to supplement HA gels with antimicrobials, for example, a HA formulation releasing oxygen reduced *P. gingivalis* growth [36].

In the present study, no clear effect of cHA or/and HS on fibroblast adhesion to dentin surfaces was found. This finding is in line with the results of a recent study [37] where cHA did not change the numbers of adhered PDLF to dentin surfaces. However, it has to be kept in mind that the analysis was made after 8 h and not after 72 h as in our study. Studies on non-cross-linked HA (ncHA) showed an inhibition of fibroblast adhesion and proliferation [33, 38]. cHA is less water soluble and promotes more cell proliferation than ncHA [39]. However, PDLF cultured on plastic surface showed an increase of fibroblast counts (proliferation) by about 20–30% by high-molecular weight HA, irrespective of whether cross-linked or not [40]. Both HA (cHA and ncHA) formulations have a high biocompatibility; in several studies, no negative effect on fibroblast viability was found [14, 40].

As the periodontal fibroblasts also function as immune cells [13], the IL-8 expression was analyzed. IL-8 is one of the most abundant proinflammatory cytokines in the oral cavity; in periodontal disease, it is produced by fibroblasts, epithelial cells, keratinocytes, and macrophages in response to the inflammatory reaction caused by bacteria and their components [41]. HS increased the expression of IL-8 which might be confirmatory to other studies. Serum amyloid A induces the expression of IL-8 in human gingival fibroblasts [42]. HS and its component serum albumin increased the expression of IL-8 by epithelial cells, also after challenging *P. gingivalis* and its obvious ability to degrade IL-8 [43]. IL-8 is a chemoattractant for neutrophils to the site of infection [44]. A positive role of neutrophils in battling the non-balanced microbiota can be assumed; however, neutrophils are also associated with tissue damage [45]. A downregulation of mRNA expression by cHA was found in that study; cHA decreased but did not block IL-8 expression induced by serum. This finding may support a beneficial role in the resolution of inflammation in periodontal therapy. Chen et al. showed that gingival fibroblasts after pretreatment with high-molecular weight HA and thereafter with *P. gingivalis* released less IL-8 in comparison with HA of lower molecular weight [46]. In the inflammatory model of interstitial cystitis, HA showed potent inhibition of IL-8 release [47]. IL-8 binds to HA, the binding is depending on the sulfation degree and the presence of metallic ions [48].

HA is triggering via the receptors RHAMM, CD44, and the intracellular adhesion molecule (ICAM)-1 [2]. Following injury, there is an increased expression of hyaluronic acid receptor genes in the initial stage of inflammation which promotes fibroblasts migration [49]. The focus on the present study was on RHAMM and CD44. The receptors are expressed both by the PDLF and the GF. Expression of CD44 was not affected neither by HS nor by cHA. CD44 is involved in wound healing thereby decreasing inflammatory response [50]. In case of RHAMM, the two types of fibroblasts responded differently to the stimuli. PDLF RHAMM expression did not significantly differ, whereas HS and/or cHA promoted the RHAMM expression in gingival fibroblasts. RHAMM expression is known to be stimulated by low-molecular weight HA. Signaling via the receptor leads to wound closure and resolution of inflammation [51]. The observed increase of RHAMM expression by HS may, at least partly, be responsible for cHA exerting its activity.

Animal models and in vitro research shed light to the role of HA in periodontal regeneration. A study on two wall intrabony defects in dogs which were treated with cHA and a collagen matrix highlighted the role of cHA in promoting periodontal wound healing/regeneration [15]. In diabetic rats, adding cHA to a collagen membrane prevented its premature degradation [52]. In vitro both cHA and ncHA increased early osteogenic differentiation of primary PDL fibroblasts [40]. Both preparations induced proliferation and migration of the fibroblasts and upregulation of genes involved in wound healing and regeneration [14]. In palatal but not in gingival fibroblasts, expression of matrix-metalloproteinases was induced, a finding of relevance when applying palatal transplants in periodontal surgery [14]. Further,

the proliferation of mesenchymal stromal and osteogenic progenitor cells was increased by cHA and ncHA [53].

In summary, the present study analyzed the role of cHA in the serum-rich environment of a periodontal pocket. It was shown that the serum did not negatively affect the activity of cHA against periodontal biofilm and on periodontal fibroblasts which, in turn, may support the application of cHA in non-surgical periodontal therapy. However, the present study has also some limitations. First of all, this is an in vitro study which did not consider the complexity of the periodontal region with a plethora of cells interacting with each other. Although here not tested, we assume that similar results concerning the effect of serum and cHA can be expected also for epithelial cells and alveolar bone cells. Second, an interaction of the periodontal biofilm with host cells (e.g., fibroblasts and monocytic cells) was not studied, and third, only one HA formulation (i.e., cHA) was used. Nevertheless, the results of the study encourage further in vitro research including other cell types and interactions with a periodontal biofilm and other HA formulations.

Acknowledgements Alexandra Stähli is supported by a grant from the Geistlich-Stucki Foundation (Switzerland). The authors appreciate the excellent technical assistance of Ivan Abegglen and Fabiola Costanco (Department of Periodontology, Laboratory of Oral Microbiology).

Author contribution XZ performed the experiments; LvonW and GZ were involved in cell counting; SE, AS, and AS designed the study; SE supervised and designed the experiments; XZ, SE, and AS wrote the first draft of the manuscript; AS critically revised the manuscript.

Funding Open access funding provided by University of Bern The study was entirely funded by the Department of Periodontology of the University of Bern.

Declarations

Competing interests The authors declare no competing interests.

Ethics approval and consent to participate Human gingival fibroblasts (GF) and human periodontal ligament fibroblasts (PDLF) were obtained from extracted teeth whose owner had been informed and given written agreement. As these biomaterials were irreversibly anonymized, no approval of the local ethical committee (KEK) was needed according to the respective guidelines.

Conflict of interest The authors declare no competing interests.

References

1. Tavianatou AG et al (2019) Hyaluronan: molecular size-dependent signaling and biological functions in inflammation and cancer. Febs j 286(15):2883–2908
2. Vasvani S, Kulkarni P, Rawtani D (2020) Hyaluronic acid: a review on its biology, aspects of drug delivery, route of administrations and a special emphasis on its approved marketed products and recent clinical studies. Int J Biol Macromol 151:1012–1029
3. Pogrel MA, Lowe MA, Stern R (1996) Hyaluronan (hyaluronic acid) in human saliva. Arch Oral Biol 41(7):667–671
4. Castillo F et al (2021) Levels of low-molecular-weight hyaluronan in periodontitis-treated patients and its immunostimulatory effects on CD4(+) T lymphocytes. Clin Oral Investig 25(8):4987–5000
5. Bartold PM, Page RC (1986) The effect of chronic inflammation on gingival connective tissue proteoglycans and hyaluronic acid. J Oral Pathol 15(7):367–374
6. Darveau RP, Curtis MA (2021) Oral biofilms revisited: a novel host tissue of bacteriological origin. Periodontol 2000 86(1):8–13
7. Jakubovics NS et al (2021) The dental plaque biofilm matrix. Periodontol 2000 86(1):32–56
8. Joseph S, Curtis MA (2021) Microbial transitions from health to disease. Periodontol 2000 86(1):201–209
9. Cobb CM, Sottosanti JS (2021) A re-evaluation of scaling and root planing. J Periodontol 92(10):1370–1378
10. Griffiths GS (2000) Formation, collection and significance of gingival crevice fluid. Periodontol 2003(31):32–42
11. Tsuchida S et al (2018) Current status of proteomic technologies for discovering and identifying gingival crevicular fluid biomarkers for periodontal disease. Int J Mol Sci 20(1):86
12. Du J, Li M (2017) Functions of periostin in dental tissues and its role in periodontal tissues' regeneration. Cell Mol Life Sci 74(23):4279–4286
13. Meyle J et al (2017) The innate host response in caries and periodontitis. J Clin Periodontol 44(12):1215–1225
14. Asparuhova MB et al (2019) Activity of two hyaluronan preparations on primary human oral fibroblasts. J Periodontal Res 54(1):33–45
15. Shirakata Y et al (2021) Periodontal wound healing/regeneration of two-wall intrabony defects following reconstructive surgery with cross-linked hyaluronic acid-gel with or without a collagen matrix: a preclinical study in dogs. Quintessence Int 0(0):308–316
16 Shirakata Y et al (2021) Healing of buccal gingival recessions following treatment with coronally advanced flap alone or combined with a cross-linked hyaluronic acid gel. An experimental study in dogs. J Clin Periodontol 48(4):570–580
17. Shirakata Y et al (2022) Cross-linked hyaluronic acid gel with or without a collagen matrix in the treatment of class III furcation defects: a histologic and histomorphometric study in dogs. J Clin Periodontol 49(10):1079–1089
18. Pilloni A et al (2021) Healing of intrabony defects following regenerative surgery by means of single-flap approach in conjunction with either hyaluronic acid or an enamel matrix derivative: a 24-month randomized controlled clinical trial. Clin Oral Investig 25(8):5095–5107
19. Pilloni A et al (2019) Effectiveness of adjunctive hyaluronic acid application in coronally advanced flap in Miller class I single gingival recession sites: a randomized controlled clinical trial. Clin Oral Investig 23(3):1133–1141
20. Eliezer M et al (2019) Hyaluronic acid as adjunctive to non-surgical and surgical periodontal therapy: a systematic review and meta-analysis. Clin Oral Investig 23(9):3423–3435
21. Bertl K et al (2015) Hyaluronan in non-surgical and surgical periodontal therapy: a systematic review. J Clin Periodontol 42(3):236–246

22. Olszewska-Czyz I, Kralik K, Prpic J (2021) Biomolecules in dental applications: randomized, controlled clinical trial evaluating the influence of hyaluronic acid adjunctive therapy on clinical parameters of moderate periodontitis. Biomolecules 11(10):1491
23. Pilloni A et al (2021) Treatment of residual periodontal pockets using a hyaluronic acid-based gel: a 12 month multicenter randomized triple-blinded clinical trial. Antibiotics (Basel) 10(8):924
24. Lin Z et al (2020) Enhanced wound healing potential of primary human oral fibroblasts and periodontal ligament cells cultured on four different porcine-derived collagen matrices. Materials (Basel) 13(17):3819
25. Strauss FJ et al (2018) Acid bone lysate activates TGFβ signalling in human oral fibroblasts. Sci Rep 8(1):16065
26. Hagi TT et al (2015) A biofilm pocket model to evaluate different non-surgical periodontal treatment modalities in terms of biofilm removal and reformation, surface alterations and attachment of periodontal ligament fibroblasts. PLoS ONE 10(6):e0131056
27. Parisi L et al (2022) Discovery and characterization of heterogeneous and multipotent fibroblast populations isolated from excised cleft lip tissue. Stem Cell Res Ther 13(1):469
28. Shen Y et al (2010) Identification of suitable reference genes for measurement of gene expression in human cervical tissues. Anal Biochem 405(2):224–229
29. Subbarao KC et al (2019) Gingival crevicular fluid: an overview. J Pharm Bioallied Sci 11(Suppl 2):S135-s139
30. Yin S et al (2018) The interaction of N-acetylcysteine and serum transferrin promotes bacterial biofilm formation. Cell Physiol Biochem 45(4):1399–1409
31. Bełdowski P et al (2021) Albumin-hyaluronan interactions: influence of ionic composition probed by molecular dynamics. Int J Mol Sci 22(22):12360
32. Drago L et al (2014) Antiadhesive and antibiofilm activity of hyaluronic acid against bacteria responsible for respiratory tract infections. APMIS 122(10):1013–1019
33. Cassinelli C et al (2000) Evaluation of interfacial properties of hyaluronan coated poly(methylmethacrylate) intraocular lenses. J Biomater Sci Polym Ed 11(9):961–977
34. Yadav MK et al (2013) Hyaluronic acid derived from other streptococci supports Streptococcus pneumoniae in vitro biofilm formation. Biomed Res Int 2013:690217
35. Binshabaib M et al (2020) Antimicrobial efficacy of 0.8% hyaluronic acid and 0.2% chlorhexidine against Porphyromonas gingivalis strains: an in-vitro study. Pak J Med Sci 36(2):111–114
36. Özçelik H et al (2021) Characterization of a hyaluronic acid-based hydrogel containing an extracellular oxygen carrier (M101) for periodontitis treatment: an in vitro study. Int J Pharm 605:120810
37. Mueller A et al (2017) Effect of hyaluronic acid on morphological changes to dentin surfaces and subsequent effect on periodontal ligament cell survival, attachment, and spreading. Clin Oral Investig 21(4):1013–1019
38. Yu KH et al (2018) A cochlear implant loaded with dexamethasone and coated with hyaluronic acid to inhibit fibroblast adhesion and proliferation. J Drug Deliv Sci Technol 46:173–181
39. Tang S et al (2021) A covalently cross-linked hyaluronic acid/bacterial cellulose composite hydrogel for potential biological applications. Carbohydr Polym 252:117123
40. Fujioka-Kobayashi M et al (2017) In vitro effects of hyaluronic acid on human periodontal ligament cells. BMC Oral Health 17(1):44
41. Sahingur SE, Yeudall WA (2015) Chemokine function in periodontal disease and oral cavity cancer. Front Immunol 6:214
42. Song LT et al (2020) The interaction between serum amyloid A and Toll-like receptor 2 pathway regulates inflammatory cytokine secretion in human gingival fibroblasts. J Periodontol 91(1):129–137
43. Guentsch A et al (2010) Influence of serum on interaction of Porphyromonas gingivalis ATCC 33277 and Aggregatibacter actinomycetemcomitans Y4 with an epithelial cell line. J Periodontal Res 45(2):229–238
44. Baggiolini M, Clark-Lewis I (1992) Interleukin-8, a chemotactic and inflammatory cytokine. FEBS Lett 307(1):97–101
45 Hajishengallis G (2020) New developments in neutrophil biology and periodontitis. Periodontol 2000 82(1):78–92
46. Chen M et al (2019) High molecular weight hyaluronic acid regulates P. gingivalis–induced inflammation and migration in human gingival fibroblasts via MAPK and NF-κB signaling pathway. Arch Oral Biol 98:75–80
47. Rooney P et al (2015) Hyaluronic acid decreases IL-6 and IL-8 secretion and permeability in an inflammatory model of interstitial cystitis. Acta Biomater 19:66–75
48. Brunori F et al (2022) Sulfation pattern dependent iron(III) mediated interleukin-8 glycan binding. ChemBioChem 23(3):e202100552
49. Slevin M et al (2007) Hyaluronan-mediated angiogenesis in vascular disease: uncovering RHAMM and CD44 receptor signaling pathways. Matrix Biol 26(1):58–68
50. Govindaraju P et al (2019) CD44-dependent inflammation, fibrogenesis, and collagenolysis regulates extracellular matrix remodeling and tensile strength during cutaneous wound healing. Matrix Biol 75–76:314–330
51. Tolg C, Telmer P, Turley E (2014) Specific sizes of hyaluronan oligosaccharides stimulate fibroblast migration and excisional wound repair. PLoS ONE 9(2):e88479
52. Eliezer M et al (2019) Hyaluronic acid slows down collagen membrane degradation in uncontrolled diabetic rats. J Periodontal Res 54(6):644–652
53. Asparuhova MB et al (2020) Role of hyaluronan in regulating self-renewal and osteogenic differentiation of mesenchymal stromal cells and pre-osteoblasts. Clin Oral Investig 24(11):3923–3937

materials

MDPI

Article

Adjunctive Application of Hyaluronic Acid in Combination with a Sodium Hypochlorite Gel for Non-Surgical Treatment of Residual Pockets Reduces the Need for Periodontal Surgery—Retrospective Analysis of a Clinical Case Series

Daniel Diehl [1,2,†], Anton Friedmann [1,*,†], Pheline Liedloff [1], Rico Marvin Jung [1], Anton Sculean [3] and Hakan Bilhan [1]

[1] Department of Periodontology, Faculty of Health, Witten/Herdecke University, 58455 Witten, Germany
[2] Institute of Pharmacology and Toxicology, Faculty of Health, Witten/Herdecke University, 58455 Witten, Germany
[3] Department of Periodontology, School of Dental Medicine, University of Bern, 3012 Bern, Switzerland
* Correspondence: anton.friedmann@uni-wh.de
† These authors contributed equally to this work.

Abstract: The comprehensive treatment of periodontitis stage 2 to 4 aims at the resolution of periodontal inflammation and "pocket closure", which implies a residual probing depth of ≤4 mm and a negative BoP. However, supportive periodontal therapy (SPT) regularly leaves behind persistent periodontal pockets with 5 or more mm in residual PPD and sites that often re-colonize and re-infect. Various adjunctive options for subgingival instrumentation have been proposed to enhance the antimicrobial effects to better control the re-infection of these residual sites. The locally applied adjuncts, based on their anti-inflammatory effect, are sodium hypochlorite antiseptic cleaning gel and cross-linked hyaluronic acid (xHyA). Both recently moved into the focus of clinical research on non-surgical and surgical therapy for periodontitis. The surgical use of xHyA indicates regenerative potential, supporting periodontal regeneration. This case series retrospectively analyzes the clinical benefits of the consecutive flapless application of sodium-hypochlorite-based cleaning gel and xHyA at the SPT to achieve pocket closure, thereby reducing the need for periodontal surgery. In 29 patients, 111 sites received the treatment sequence. At 6-month re-evaluation, an overall PPD reduction exceeding 2 mm was achieved, associated with a similar CAL gain (2.02 mm); the bleeding tendency (BoP) was reduced by >60%. Pocket closure occurred in almost 25% of all the sites. Within their limits, the present data suggest that the proposed combined adjunctive treatment of residual active periodontal sites yielded significant improvement in the clinical parameters. Further studies in RCT format are required to confirm these observations.

Keywords: hyaluronic acid; sodium hypochlorite; periodontitis; non-surgical periodontal therapy

check for updates

Citation: Diehl, D.; Friedmann, A.; Liedloff, P.; Jung, R.M.; Sculean, A.; Bilhan, H. Adjunctive Application of Hyaluronic Acid in Combination with a Sodium Hypochlorite Gel for Non-Surgical Treatment of Residual Pockets Reduces the Need for Periodontal Surgery—Retrospective Analysis of a Clinical Case Series. *Materials* **2022**, *15*, 6508. https://doi.org/10.3390/ma15196508

Academic Editor: Francesco Inchingolo

Received: 15 August 2022
Accepted: 13 September 2022
Published: 20 September 2022

1. Introduction

Non-surgical periodontal treatment (NSPT) results in improved probing depth, clinical attachment level, and bleeding tendency [1]. The purpose of NSPT is the resolution of periodontal inflammation and a reduction in pocket-probing depth (PPD) to 4 mm or less, resulting in pocket closure. However, residual or recurring pockets exhibiting PPD values ≥4 mm are regularly found at re-evaluation. Residual periodontal pockets facilitate the accumulation of biofilm, leading to dysbiosis within the re-colonized subgingival habitat and, thus, to persistent inflammation [2,3]. Moreover, long-term data confirm the association between residual PPD and increased risk of tooth loss [4]. Therefore, as recommended in the European Federation of Periodontology (EFP) guidelines, continuous supportive periodontal therapy (SPT) accompanied by repeated instrumentation is imperative for sustained periodontal stability [5].

In an effort to improve the outcome of non-surgical instrumentation, a variety of adjunct treatment modalities are used. In addition to systemic antibiotics, a plethora of locally administered adjunctives seek to minimize both PPD and bleeding tendency, thereby facilitating the closure of the periodontal pocket.

Most of these adjunctive treatments are based upon the antimicrobial effects delivered by either photodynamic therapy (PDT) or the use of local antibiotic chemotherapy, preferably applied as a device with sustained release kinetics [6–10]. Furthermore, gelatin chips sustainably releasing chlorhexidine have been described [11–13]. Addressing the limitations of subgingival instrumentation on pocket-closure frequency, a recent systematic review and meta-analysis evaluated the additional benefit of locally applied adjunctive therapies. Even though the authors found effects of statistical significance, the magnitude of these benefits was deduced to be rather irrelevant to clinical success in terms of pocket closure [14]. Furthermore, the microbiological analysis of samples retrieved from persistent deep pockets before and after repeated local metronidazole application revealed high counts of periodontal pathogens [9].

By contrast, a novel amino-acid-buffered sodium hypochlorite cleaning gel exhibiting antimicrobial potential was significantly effective in improving the outcome of non-surgical therapy and, thus, significantly reduced counts of Gram-negative pathogens in an artificial biofilm model [15,16].

Another strategy to improve periodontal parameters is the local administration of regenerative biologics. In an attempt to harness its well-documented regenerative properties, a recent multi-center randomized controlled trial investigated the effect of enamel-matrix derivatives (EMDs) as an adjunct to the NSPT of patients situated in SPT [17]. The authors were able to show significantly greater pocket closure for sites treated with adjunctive EMD, demonstrating biologics-based regenerative technologies as promising supplements for non-surgical therapy.

Furthermore, a review with a meta-analysis showed that the adjuvant non-surgical administration of hyaluronic acid (HA) resulted in an improvement in both clinical attachment and probing depth [18]. Currently, however, there is a lack in protocols for adjuncts to NSPT combining both antimicrobial and regenerative properties. In this retrospective case series, we propose a novel two-step approach consisting of an amino-acid-buffered sodium hypochlorite cleaning gel to assist in the decontamination of the root surface, followed by the concomitant application of a cross-linked hyaluronic acid gel (xHyA) to facilitate healing and, thus, pocket closure. We report the retrospective analysis of 6-month clinical follow-up data from patients who qualified for this therapy.

2. Materials and Methods

The local ethics committee at the Witten/Herdecke University approved this retrospective evaluation of a clinical case series (S-203/2021). All the analyzed cases had been diagnosed with stage 2 to 4 periodontitis previously and had already undergone comprehensive periodontal therapy, as proposed by the EFP guidelines [5,19]. Four calibrated specialists and residents at the Department of Periodontology of Witten/Herdecke University were responsible for all treatment steps. Calibration of investigators was evaluated by analysis of variance (ANOVA), followed by Tukey's post hoc analysis for multiple comparisons ($p > 0.59$ for all investigators). The decision to administer systemic antibiotics strictly complied with the EFP guidelines, following completion of initial subgingival instrumentation.

2.1. Inclusion Criteria

The proposed treatment applied to sites that exhibited persistent deep pocket depths after patients had undergone consecutive SPT re-evaluations at least twice. Sites ascribed to the treatment by protocol had never been subjected to any surgical intervention, even though patients may have received periodontal surgery at other sites. Specifically, persistent and recurrent periodontal pockets displaying $\geq$5 mm in PPD with positive BoP were included. The number of sites per patient assigned to the therapy was unrestricted. There

was no limit to the localization of residual or recurrent pockets, and single- and multi-rooted teeth were included. In teeth with high PPD associated with furcation involvement of more than Class 1, only the change in vertical component of the defect was analyzed for this report.

2.2. Treatment Sequence

Four calibrated operators treated all patients; the operators agreed upon the treatment protocol before the first application. Following supragingival mechanical instrumentation, each site received subgingivally administrated sodium hypochlorite cleaning gel (Perisolv; Regedent AG, Zürich, Switzerland) for 30 to 45 s to support chemical disinfection and improve the scaling outcome. Subgingival instrumentation was carried out with Gracey curettes (Deppeler, American Dental Systems, Munich, Germany). The sodium hypochlorite cleaning-gel application was repeated until the instrumentation was considered sufficient (Figure 1). Sufficient instrumentation was attained when root surfaces exhibited smooth surfaces upon probing with an explorer probe (ODU 11/12 DH2, Deppeler, Rolle, Switzerland). Subsequently, 0.3 mL of the cross-linked hyaluronic acid gel (xHyA; hyaDENT BG, Regedent AG, Zürich, Switzerland) was applied into the subgingival pocket in a flapless manner until plenished. Patients were instructed to uphold daily mechanical biofilm control by means of interdental brushes and a toothbrush. Measures for oral hygiene were not adjusted in the operated area. Neither systemic antibiotics nor antiseptics for rinsing were prescribed by protocol. Within the next 7 days, a repeated subgingival xHyA application (0.3 mL) was conducted combined with the oral hygiene control. The first re-evaluation took place 5–6 months after treatment and the subsequent SPT interval was set to 3 months for a 12-month period. At the 12-month re-evaluation, a periapical radiograph taken with the parallel technique was obtained to verify the crestal bone level.

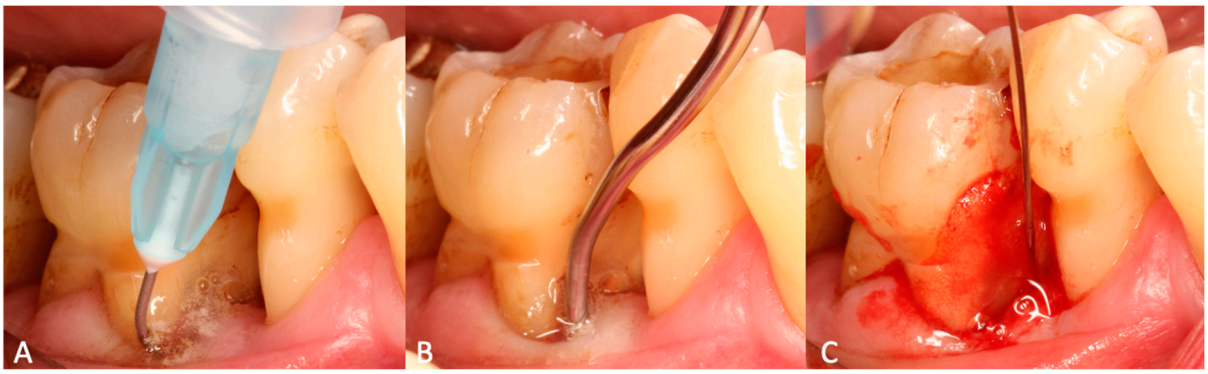

Figure 1. Visualization of the applied treatment protocol. (**A**) Application of chloramine gel to the pocket for 30–45 s. (**B**) Scaling and root planning is performed. Chloramine gel may be applied repeatedly until non-surgical treatment is deemed sufficient. (**C**) Cross-linked hyaluronic acid (xHya) is applied to the pocket until plenished.

2.3. Statistical Analysis

For all obtained datasets, a descriptive data analysis was performed. Further statistical analyses included the Shapiro–Wilk, Kolmogorov–Smirnov, and D'Agostino–Pearson tests to assess data distribution. CAL gain and PPD reduction (pre–post) were both calculated by Wilcoxon signed-rank test, respectively. p-values of ≤ 0.05 were considered significant.

3. Results

This retrospective analysis included 29 patients with 111 treated teeth/sites, ranging from 1 to 17 per patient. The mean age was 54.6 years, and 69% were female (20:9; 69% vs. 31%). All patients were normo-glycemic and 7% (n = 2) were smokers. Table 1 discloses the

demographics, habits, and health condition of the participants. All of them participated in the SPT program offered by the Department of Periodontology.

Table 1. Patient demographics and mean clinical parameters before (pre) and after (post = 6 months) the treatment. CAL = clinical attachment level, PPD = probing pocket depth, BOP = bleeding on probing, * = Wilcoxon signed-rank test.

Patients (Sites)			**29 (111)**	
Mean Age (Range)			**54.6 (39–75)**	
Sex				
– **Male (%)**			**9 (31%)**	
– **Female (%)**			**20 (69%)**	
Smokers (%)			**2 (7%)**	
Diabetes (%)			**0**	
		Pre	**Post**	**CAL gain/PPD Reduction**
CAL	Mean (SD)	7.96 (±2.2)	5.95 (±1.8)	+2.02 mm ($p < 0.0001$) *
	Median	7	6	
	Min	2	2	
	Max	9	13	
PPD	Mean (SD)	7.19 (±1.89)	5.16 (±1.81)	−2.04 mm ($p < 0.0001$) *
	Median	6	5	
	Min	4	2	
	Max	15	12	
BOP		97.6%	40.1%	

The mean PPD at baseline was 7.19 (±1.89) mm, and the CAL loss was 7.96 (±2.2) mm; 97.6% of all sites presented with positive BoP. Consecutive six-month re-evaluation revealed an overall PPD reduction of 2.04 mm and a clinical attachment level gain of 2.02 mm, indicating that no further progression in gingival recession occurred. The BoP frequency decreased to 40.1%. Stratified by furcation involvement (12 teeth), the mean CAL gain was 1.5 mm ($p = 0.0195$), whereas the treatment of single-rooted teeth resulted in a 2.04 mm ($p < 0.001$) CAL gain (Tables 2 and 3, Figure 2). Both measurements yielded statistically significant differences compared to the baseline values. In terms of pocket closure, 25 out of 99 (25.25%) sites in the single-rooted teeth exhibited pocket closure, with a PPD < 4 mm and a negative BoP.

Table 2. Descriptive statistics of PPD and CAL development in furcation-involved sites after combined chloramine and xHya treatment. Pre = baseline, Post = 6 months post treatment, * = Wilcoxon signed-rank test.

Furcation Involved (n = 12)		**Pre**	**Post**	**CAL Gain/PPD Reduction**
CAL	Mean (SD)	9.08 (±2.88)	7.58 (±1.73)	+1.50 mm ($p = 0.0195$) *
	Median	9	8	
	Min	6	4	
	Max	16	9	
PPD	Mean (SD)	8.25 (±2.59)	5.833 (±1.75)	−2.42 mm ($p = 0.002$) *
	Median	8	5.5	
	Min	6	3	
	Max	15	9	

Table 3. Descriptive statistics of PPD and CAL development in sites without furcation involvement after combined chloramine and xHya treatment. Pre = baseline, Post = 6 months post treatment, * = Wilcoxon signed-rank test.

No Furcation Involved (n = 99)		Pre	Post	CAL Gain/PPD Reduction
CAL	Mean (SD)	7.93 (±2.03)	5.89 (±1.87)	+2.04 mm ($p < 0.0001$) *
	Median	7	6	
	Min	5	2	
	Max	13	13	
PPD	Mean (SD)	6.96 (±1.68)	5.15 (±1.86)	−1.81 mm ($p < 0.0001$) *
	Median	6	5	
	Min	4	2	
	Max	12	12	

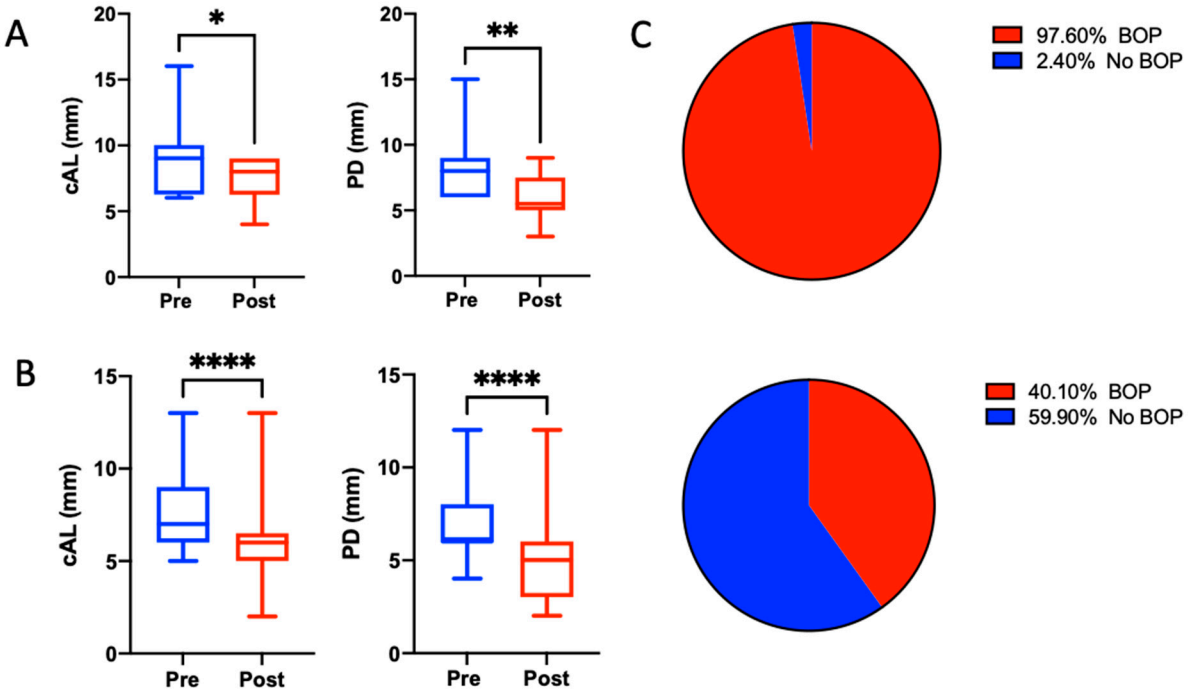

Figure 2. Boxplots for clinical parameters before and after the treatment sequence of non-furcation-involved (**A**) and furcation-involved (**B**) sites. Whiskers represent minimum and maximum values. * $p < 0.05$, ** $p < 0.01$, **** $p < 0.0001$. (**C**) Amount of sites exhibiting bleeding on probing before (upper) and after (lower) the treatment.

4. Discussion

This retrospective case series shows that the combination of an antiseptic adjunctive cleaning gel and xHyA applied subgingivally for the treatment of persistently deep periodontal pockets at SPT visit yielded clinically relevant improvements in PPD reduction, CAL gain, and BoP frequency. The follow-up of the reported cases revealed statistically significant improvement in all three of these parameters. The overall CAL gain exceeded 2 mm on average in sites previously classified as non-responding and persistent. Although a minor number of treated sites exhibited complete pocket closure after three to six months, the two-component flapless adjunctive treatment considerably reduced the need for periodontal surgery. Sites ascribed to surgical step3 therapy according to the EFP guidelines clinically improved to such an extent that the periodontal surgery became redundant. To the best of our knowledge, this is the first report of the combined use of antiseptic and

biologic approaches in flapless periodontal treatment. As each site received both adjunctive materials administered at one visit, we must emphasize that a discussion of the individual contributions to the results appeared unnecessary.

Recent in vitro, pre-clinical, and clinical studies investigated either the sodium hypochlorite cleaning gel or the xHyA application in a separate manner. The antimicrobial effects of the sodium hypochlorite cleaning gel became evident [16,20]. Cell-based experiments also disclosed the high level of cytocompatibility of its compounds [20,21]. However, the benefits of adjunctive sodium hypochlorite cleaning gel for NSPT remain controversial. Sodium hypochlorite gel failed to affect the clinical outcome of ultrasonic or manual subgingival instrumentation in SPT treatment. Nevertheless, its use was associated with significantly reduced recolonization of the sites by *T. denticola* and *T. forsythia* [22]. By contrast, the adjunctive benefit of sodium hypochlorite gel formulation for minimally invasive non-surgical therapy (MINST) was positively evaluated by a recent RCT [15]. The authors compared the outcome of step-2 therapy after delivering it to untreated stage-3 and -4 periodontitis patients in both study arms. Moreover, in an RCT study from a Scandinavian research group, diabetic foot ulcers resolved significantly quicker under treatment with this cleaning gel formulation than those in the control group [23].

Hyaluronic acid (HA) is a glycosaminoglycan heteropolysaccharide and, in its native form, it is both a light-molecular-weight (LMWHA) and a high-molecular-weight long polymer (HMWHA) [24]. HA is an important natural component of the extracellular matrix and is almost ubiquitously present in mammalian tissues, including the periodontium [25]. Several studies confirmed bacteriostatic [26,27], fungostatic [28], anti-inflammatory [29], anti-edematous [30], osteoinductive [29,31–33], and pro-angiogenic [34] properties of HA. In animal studies on skin wounds, HA promoted enhanced connective-tissue elasticity and healing, improved re-epithelialization, and appeared to increase microvascular density [34,35]. HA sufficiently improved wound healing in extraoral wounds, skin ulcers, and intraoral injuries [36–38].

The potential of xHyA to promote periodontal regeneration became a subject in a recent series of histological evaluations in dogs' mandibles. The histomorphometric assessments revealed that xHyA-treated intraosseous and furcation sites formed significantly greater areas of new cementum and periodontal ligament fibers on previously exposed root surfaces. Similar observations were made from the same treatment sequence applied in gingival recessions [39–41].

The clinical results mediated by xHyA indicated a substantial benefit, which was corroborated by both a recent RCT study and a case series [42,43]. Beyond the positive effects of xHyA unfolded in the surgical context, its adjunctive use in NSPT yielded inconsistent outcomes in clinical studies [44–46].

In our retrospective analysis, we found a significant probing-depth reduction accompanied by a significant gain in clinical attachment (Figure 2). Moreover, the needlessness of root conditioning and drying the wound area increased the ease of handling and delivered strong arguments in favor of xHyA as an adjunct to flapless subgingival instrumentation, as well as accounting for its hygroscopic/wound-stabilizing and regenerative properties. In addition, compliance with the second visit scheduled for repeated xHyA application was high in all the patients. With respect to the proposed protocol, the sodium hypochlorite cleaning-gel application may offer further advantages to NSPT by means of improving the mechanical biofilm removal, thus enhancing the effects of the xHyA. Therefore, we consider the proposed protocol highly beneficial for NSPT. However, the presented results require further confirmation by randomized controlled clinical trials, which may also account for the exposure time and application frequency of the hypochlorite gel.

Author Contributions: D.D., A.F. contributed to conception, design, data acquisition, and interpretation, performed all the statistical analyses, and drafted and critically revised the manuscript. P.L.; R.M.J. contributed to data acquisition and critically revised the manuscript. H.B. contributed to the conception, design, and data acquisition and critically revised the manuscript. A.S. critically proofread and revised the manuscript. All authors have read and agreed to the published version of the manuscript.

Funding: This research received no external funding. D.D. was supported by an internal Ph.D. scholarship of the Witten/Herdecke University.

Institutional Review Board Statement: The study was conducted according to the guidelines of the Declaration of Helsinki and approved by the local Ethics Committee of Witten/Herdecke University (S-203/2021).

Informed Consent Statement: Informed consent was obtained from all subjects involved in the study.

Data Availability Statement: The data presented in this study are available on request from the corresponding authors. The data are not publicly available because they were derived from patients.

Conflicts of Interest: The authors declare no conflict of interest.

References

1. Suvan, J.; Leira, Y.; Moreno Sancho, F.M.; Graziani, F.; Derks, J.; Tomasi, C. Subgingival instrumentation for treatment of periodontitis. A systematic review. *J. Clin. Periodontol.* **2020**, *47* (Suppl. 22), 155–175. [CrossRef]
2. Kebschull, M.; Chapple, I. Evidence-based, personalised and minimally invasive treatment for periodontitis patients—the new EFP S3-level clinical treatment guidelines. *Br. Dent. J.* **2020**, *229*, 443–449. [CrossRef] [PubMed]
3. Sanz, M.; Beighton, D.; Curtis, M.A.; Cury, J.A.; Dige, I.; Dommisch, H.; Ellwood, R.; Giacaman, R.A.; Herrera, D.; Herzberg, M.C.; et al. Role of microbial biofilms in the maintenance of oral health and in the development of dental caries and periodontal diseases. Consensus report of group 1 of the Joint EFP/ORCA workshop on the boundaries between caries and periodontal disease. *J. Clin. Periodontol.* **2017**, *44* (Suppl. 18), S5–S11. [CrossRef] [PubMed]
4. Matuliene, G.; Pjetursson, B.E.; Salvi, G.E.; Schmidlin, K.; Brägger, U.; Zwahlen, M.; Lang, N.P. Influence of residual pockets on progression of periodontitis and tooth loss: Results after 11 years of maintenance. *J. Clin. Periodontol.* **2008**, *35*, 685–695. [CrossRef] [PubMed]
5. Sanz, M.; Herrera, D.; Kebschull, M.; Chapple, I.; Jepsen, S.; Berglundh, T.; Sculean, A.; Tonetti, M.S.; On behalf of the EFP Workshop Participants and Methodological Consultants. Treatment of stage I-III periodontitis-The EFP S3 level clinical practice guideline. *J. Clin. Periodontol.* **2020**, *47* (Suppl. 22), 4–60. [CrossRef] [PubMed]
6. Salvi, G.E.; Stähli, A.; Schmidt, J.C.; Ramseier, C.A.; Sculean, A.; Walter, C. Adjunctive laser or antimicrobial photodynamic therapy to non-surgical mechanical instrumentation in patients with untreated periodontitis: A systematic review and meta-analysis. *J. Clin. Periodontol.* **2020**, *47* (Suppl. 22), 176–198. [CrossRef]
7. Cosgarea, R.; Eick, S.; Batori-Andronescu, I.; Jepsen, S.; Arweiler, N.B.; Rößler, R.; Conrad, T.; Ramseier, C.A.; Sculean, A. Clinical and Microbiological Evaluation of Local Doxycycline and Antimicrobial Photodynamic Therapy during Supportive Periodontal Therapy: A Randomized Clinical Trial. *Antibiotics* **2021**, *10*, 277. [CrossRef]
8. Christodoulides, N.; Nikolidakis, D.; Chondros, P.; Becker, J.; Schwarz, F.; Rössler, R.; Sculean, A. Photodynamic therapy as an adjunct to non-surgical periodontal treatment: A randomized, controlled clinical trial. *J. Periodontol.* **2008**, *79*, 1638–1644. [CrossRef]
9. Riep, B.; Purucker, P.; Bernimoulin, J.P. Repeated local metronidazole-therapy as adjunct to scaling and root planing in maintenance patients. *J. Clin. Periodontol.* **1999**, *26*, 710–715.
10. Rudhart, A.; Purucker, P.; Kage, A.; Hopfenmüller, W.; Bernimoulin, J.P. Local metronidazole application in maintenance patients. *Clinical and microbiological evaluation. J. Periodontol.* **1998**, *69*, 1148–1154.
11. Jeffcoat, M.K.; Palcanis, K.G.; Weatherford, T.W.; Reese, M.; Geurs, N.C.; Flashner, M. Use of a biodegradable chlorhexidine chip in the treatment of adult periodontitis: Clinical and radiographic findings. *J. Periodontol.* **2000**, *71*, 256–262. [CrossRef] [PubMed]
12. Kasaj, A.; Chiriachide, A.; Willershausen, B. The adjunctive use of a controlled-release chlorhexidine chip following treatment with a new ultrasonic device in supportive periodontal therapy: A prospective, controlled clinical study. *Int. J. Dent. Hyg.* **2007**, *5*, 225–231. [CrossRef] [PubMed]
13. Salvi, G.E.; Mombelli, A.; Mayfield, L.; Rutar, A.; Suvan, J.; Garrett, S.; Lang, N.P. Local antimicrobial therapy after initial periodontal treatment. *J. Clin. Periodontol.* **2002**, *29*, 540–550. [CrossRef] [PubMed]
14. Herrera, D.; Matesanz, P.; Martín, C.; Oud, V.; Feres, M.; Teughels, W. Adjunctive effect of locally delivered antimicrobials in periodontitis therapy: A systematic review and meta-analysis. *J. Clin. Periodontol.* **2020**, *47* (Suppl. 22), 239–256. [CrossRef]
15. Iorio-Siciliano, V.; Ramaglia, L.; Isola, G.; Blasi, A.; Salvi, G.E.; Sculean, A. Changes in clinical parameters following adjunctive local sodium hypochlorite gel in minimally invasive nonsurgical therapy (MINST) of periodontal pockets: A 6-month randomized controlled clinical trial. *Clin. Oral Investig.* **2021**, *25*, 5331–5340. [CrossRef]

16. Jurczyk, K.; Nietzsche, S.; Ender, C.; Sculean, A.; Eick, S. In-vitro activity of sodium-hypochlorite gel on bacteria associated with periodontitis. *Clin. Oral Investig.* **2016**, *20*, 2165–2173. [CrossRef]
17. Jentsch, H.F.; Roccuzzo, M.; Pilloni, A.; Kasaj, A.; Fimmers, R.; Jepsen, S. Flapless application of enamel matrix derivative in periodontal retreatment: A multicentre randomized feasibility trial. *J. Clin. Periodontol.* **2021**, *48*, 659–667. [CrossRef]
18. Eliezer, M.; Imber, J.C.; Sculean, A.; Pandis, N.; Teich, S. Hyaluronic acid as adjunctive to non-surgical and surgical periodontal therapy: A systematic review and meta-analysis. *Clin. Oral Investig.* **2019**, *23*, 3423–3435. [CrossRef]
19. Tonetti, M.S.; Greenwell, H.; Kornman, K.S. Staging and grading of periodontitis: Framework and proposal of a new classification and case definition. *J. Periodontol.* **2018**, *89*, S159–S172. [CrossRef]
20. Kotsakis, G.A.; Lan, C.; Barbosa, J.; Lill, K.; Chen, R.; Rudney, J.; Aparicio, C. Antimicrobial Agents Used in the Treatment of Peri-Implantitis Alter the Physicochemistry and Cytocompatibility of Titanium Surfaces. *J. Periodontol.* **2016**, *87*, 809–819. [CrossRef]
21. Mueller, A.; Fujioka-Kobayashi, M.; Mueller, H.D.; Lussi, A.; Sculean, A.; Schmidlin, P.R.; Miron, R.J. Effect of hyaluronic acid on morphological changes to dentin surfaces and subsequent effect on periodontal ligament cell survival, attachment, and spreading. *Clin. Oral Investig.* **2017**, *21*, 1013–1019. [CrossRef] [PubMed]
22. Megally, A.; Zekeridou, A.; Cancela, J.; Giannopoulou, C.; Mombelli, A. Short ultrasonic debridement with adjunctive low-concentrated hypochlorite/amino acid gel during periodontal maintenance: Randomized clinical trial of 12 months. *Clin. Oral Investig.* **2020**, *24*, 201–209. [CrossRef]
23. Bergqvist, K.; Almhöjd, U.; Herrmann, I.; Eliasson, B. The role of chloramines in treatment of diabetic foot ulcers: An exploratory multicentre randomised controlled trial. *Clin. Diabetes Endocrinol.* **2016**, *2*, 6. [CrossRef]
24. Marinho, A.; Nunes, C.; Reis, S. Hyaluronic Acid: A Key Ingredient in the Therapy of Inflammation. *Biomolecules* **2021**, *11*, 1518. [CrossRef] [PubMed]
25. Trimmel, B.; Gede, N.; Hegyi, P.; Szakács, Z.; Mezey, G.A.; Varga, E.; Kivovics, M.; Hanák, L.; Rumbus, Z.; Szabó, G. Relative performance of various biomaterials used for maxillary sinus augmentation: A Bayesian network meta-analysis. *Clin. Oral. Implants Res.* **2021**, *32*, 135–153. [CrossRef]
26. Zhao, N.; Wang, X.; Qin, L.; Zhai, M.; Yuan, J.; Chen, J.; Li, D. Effect of hyaluronic acid in bone formation and its applications in dentistry. *J. Biomed. Mater. Res. Part A* **2016**, *104*, 1560–1569. [CrossRef] [PubMed]
27. Carlson, G.A.; Dragoo, J.L.; Samimi, B.; Bruckner, D.A.; Bernard, G.W.; Hedrick, M.; Benhaim, P. Bacteriostatic properties of biomatrices against common orthopaedic pathogens. *Biochem. Biophys. Res. Commun.* **2004**, *321*, 472–478. [CrossRef]
28. Pirnazar, P.; Wolinsky, L.; Nachnani, S.; Haake, S.; Pilloni, A. Bacteriostatic effects of hyaluronic acid. *J. Periodontol.* **1999**, *70*, 370–374. [CrossRef]
29. Kang, J.H.; Kim, Y.Y.; Chang, J.Y.; Kho, H.S. Influences of hyaluronic acid on the anticandidal activities of lysozyme and the peroxidase system. *Oral Dis.* **2011**, *17*, 577–583. [CrossRef]
30. Sasaki, T.; Watanabe, C. Stimulation of osteoinduction in bone wound healing by high-molecular hyaluronic acid. *Bone* **1995**, *16*, 9–15. [CrossRef]
31. Dahiya, P.; Kamal, R. Hyaluronic Acid: A boon in periodontal therapy. *N. Am. J. Med. Sci.* **2013**, *5*, 309–315. [CrossRef] [PubMed]
32. de Brito Bezerra, B.; Mendes Brazão, M.A.; de Campos, M.L.G.; Casati, M.Z.; Sallum, E.A.; Sallum, A.W. Association of hyaluronic acid with a collagen scaffold may improve bone healing in critical-size bone defects. *Clin. Oral Implants Res.* **2012**, *23*, 938–942. [CrossRef] [PubMed]
33. Kawano, M.; Ariyoshi, W.; Iwanaga, K.; Okinaga, T.; Habu, M.; Yoshioka, I.; Tominaga, K.; Nishihara, T. Mechanism involved in enhancement of osteoblast differentiation by hyaluronic acid. *Biochem. Biophys. Res. Commun.* **2011**, *405*, 575–580. [CrossRef] [PubMed]
34. Mendes, R.M.; Silva, G.A.; Lima, M.F.; Calliari, M.V.; Almeida, A.P.; Alves, J.B.; Ferreira, A.J. Sodium hyaluronate accelerates the healing process in tooth sockets of rats. *Arch. Oral Biol.* **2008**, *53*, 1155–1162. [CrossRef]
35. Pilloni, A.; Schmidlin, P.R.; Sahrmann, P.; Sculean, A.; Rojas, M.A. Correction to: Effectiveness of adjunctive hyaluronic acid application in coronally advanced flap in Miller class I single gingival recession sites: A randomized controlled clinical trial. *Clin. Oral Investig.* **2018**, *22*, 2961–2962. [CrossRef]
36. Yıldırım, S.; Özener, H.Ö.; Doğan, B.; Kuru, B. Effect of topically applied hyaluronic acid on pain and palatal epithelial wound healing: An examiner-masked, randomized, controlled clinical trial. *J. Periodontol.* **2018**, *89*, 36–45. [CrossRef]
37. Humbert, P.; Mikosinki, J.; Benchikhi, H.; Allaert, F.A. Efficacy and safety of a gauze pad containing hyaluronic acid in treatment of leg ulcers of venous or mixed origin: A double-blind, randomised, controlled trial. *Int. Wound J.* **2013**, *10*, 159–166. [CrossRef]
38. Juhasz, I.; Zoltan, P.; Erdei, I. Treatment of partial thickness burns with Zn-hyaluronan: Lessons of a clinical pilot study. *Ann. Burn. Fire Disasters* **2012**, *25*, 82–85.
39. Shirakata, Y.; Nakamura, T.; Kawakami, Y.; Imafuji, T.; Shinohara, Y.; Noguchi, K.; Sculean, A. Healing of buccal gingival recessions following treatment with coronally advanced flap alone or combined with a cross-linked hyaluronic acid gel. An experimental study in dogs. *J. Clin. Periodontol.* **2021**, *48*, 570–580. [CrossRef]
40. Shirakata, Y.; Imafuji, T.; Nakamura, T.; Shinohara, Y.; Iwata, M.; Setoguchi, F.; Noguchi, K.; Sculean, A. Cross-linked hyaluronic acid-gel with or without a collagen matrix in the treatment of class III furcation defects: A histologic and histomorphometric study in dogs. *J. Clin. Periodontol.* **2022**. *ahead of print*. [CrossRef]

41. Shirakata, Y.; Imafuji, T.; Nakamura, T.; Kawakami, Y.; Shinohara, Y.; Noguchi, K.; Pilloni, A.; Sculean, A. Periodontal wound healing/regeneration of two-wall intrabony defects following reconstructive surgery with cross-linked hyaluronic acid-gel with or without a collagen matrix: A preclinical study in dogs. *Quintessence Int.* **2021**, 308–316. [CrossRef]
42. Pilloni, A.; Rojas, M.A.; Marini, L.; Russo, P.; Shirakata, Y.; Sculean, A.; Iacono, R. Healing of intrabony defects following regenerative surgery by means of single-flap approach in conjunction with either hyaluronic acid or an enamel matrix derivative: A 24-month randomized controlled clinical trial. *Clin. Oral Investig.* **2021**, *25*, 5095–5107. [CrossRef]
43. Božić, D.; Ćatović, I.; Badovinac, A.; Musić, L.; Par, M.; Sculean, A. Treatment of Intrabony Defects with a Combination of Hyaluronic Acid and Deproteinized Porcine Bone Mineral. *Materials* **2021**, *14*, 6795. [CrossRef]
44. Pilloni, A.; Zeza, B.; Kuis, D.; Vrazic, D.; Domic, T.; Olszewska-Czyz, I.; Popova, C.; Kotsilkov, K.; Firkova, E.; Dermendzieva, Y.; et al. Treatment of Residual Periodontal Pockets Using a Hyaluronic Acid-Based Gel: A 12 Month Multicenter Randomized Triple-Blinded Clinical Trial. *Antibiotics* **2021**, *10*, 924. [CrossRef]
45. Olszewska-Czyz, I.; Kralik, K.; Prpic, J. Biomolecules in Dental Applications: Randomized, Controlled Clinical Trial Evaluating the Influence of Hyaluronic Acid Adjunctive Therapy on Clinical Parameters of Moderate Periodontitis. *Biomolecules* **2021**, *11*, 1491. [CrossRef]
46. Rajan, P.; Baramappa, R.; Rao, N.M.; Pavaluri, A.K.; Indeevar, P.; Rahaman, S.M.U. Hyaluronic Acid as an adjunct to scaling and root planing in chronic periodontitis. A randomized clinical trail. *J. Clin. Diagn. Res. JCDR* **2014**, *8*, ZC11. [CrossRef]

Clinical Oral Investigations
https://doi.org/10.1007/s00784-022-04618-3

ORIGINAL ARTICLE

Clinical and microbiological effects of a single application of sodium hypochlorite gel during subgingival re-instrumentation: a triple-blind randomized placebo-controlled clinical trial

Viorelia Radulescu[1] · Marius Ion Boariu[2] · Darian Rusu[1] · Alexandra Roman[3] · Petra Surlin[4] · Adrian Voicu[5] · Andreea Cristiana Didilescu[6] · Holger Jentsch[7] · Vincenzo Iorio Siciliano[8] · Luca Ramaglia[8] · Octavia Vela[1] · Giorgios Kardaras[1] · Anton Sculean[9] · Stefan-Ioan Stratul[1]

Received: 1 April 2022 / Accepted: 5 July 2022

Abstract

Objectives The aim of this study is to assess the clinical and microbiological effects of a single subgingival administration of sodium hypochlorite gel (NaOCl) and compare it with 1% chlorhexidine (CHX) gel and a placebo gel following mechanical re-instrumentation during supportive periodontal therapy (SPT).

Materials and methods Sixty-two patients who had been treated for stage III–IV periodontitis and enrolled in SPT were included in the study based on following criteria: (1) active periodontal therapy completed at least 6 months before enrollment in the study, (2) presence of at least 4 non-adjacent sites with probing pocket depths (PPDs) ≥ 4 mm with bleeding on probing (BOP), or presence of 5–8 mm PPDs with or without BOP. All sites presenting PPD ≥ 4 mm and BOP at baseline and 3-, 6-, and 9-month follow-up timepoints were subgingivally re-instrumented with ultrasounds. Selected patients were randomly assigned into three groups and treated additionally with a single subgingival administration of NaOCl gel (group A); 1% CHX gel (group B); and placebo gel (group C). Main outcome variable was pocket closure at 12 months. Secondary outcome variables were changes in mean PPD, BOP, and clinical attachment level (CAL) along with changes in the numbers of the following five keystone bacterial pathogens: *Aggregatibacter actinomycetemcomitans* (*A.a.*), *Porphyromonas gingivalis* (*P.g.*), *Prevotella intermedia* (*P.i.*), *Tannerella forsythia* (*T.f.*), and *Treponema denticola* (*T.d.*).

Results At 12 months, pocket closure was obtained in 77.5% in the NaOCl treated sites. The reduction in PPD was higher with CHX than with NaOCl, although a statistically significant adjunctive effect for NaOCl ($P = 0.028$) was only observed in comparison with placebo only. Mean CAL improved in all groups and at all timepoints, compared to the baseline ($P < 0.05$). However, after 6 months, CAL gain was statistically significantly higher in the NaOCl treated group than following application of CHX ($P = 0.0026$).

Conclusion In SPT patients, a single adjunctive use of a NaOCl gel may provide benefits in controlling inflammation and residual pockets.

Trial registration ISRCTN Registry of Clinical Trials (ISRCTN11387188).

Clinical relevance A baseline single application of NaOCl gel in conjunction with mechanical debridement may achieve substantial pocket closure in patients enrolled in SPT; treatment time, cost, and applicability considerations should be taken into account when selecting this therapy.

Keywords Periodontal maintenance · Subgingival re-instrumentaion · Sodium hypochlorite · Probing pocket debridement

Introduction

Substantial evidence has shown that periodontitis is triggered and maintained by dysbiosis of the periodontal pathogenic biofilm and subsequent destructive inflammatory response. Consequently, treatment of periodontitis

✉ Marius Ion Boariu
boarium@yahoo.com

Extended author information available on the last page of the article

Published online: 12 July 2022

always focuses in all phases on the mechanical removal or destruction of the supra- and subgingival biofilm [1–5].

Subgingival re-instrumentation during supportive periodontal therapy (SPT) has been shown to result in additional clinical improvements in only about 50% of affected sites, as evidenced by a reduction in probing pocket depths and bleeding on probing, while the rest of affected sites may show further disease progression [6–8].

The goals of SPT are to minimize or prevent recurrence of the disease and/or arrest its progression to maintain long-term periodontal health and chewing comfort [9–11]. Substantial evidence indicates that SPT plays a key role in arresting periodontal disease prognosis and increases tooth survival [12–16]. It is recommended that SPT starts once the endpoint of active periodontal therapy (APT) is reached (i.e., PPD ≤ 4 mm, absence of BOP of 4 mm sites) [17–20].

Mechanical disruption of the biofilm is an effective approach and is still considered as the "gold standard"; it is sometimes limited by the inadequate access and visibility to the operative sites [21, 22]. Air polishing devices have been proposed as a more effective alternative for biofilm removal at sites difficult to access with hand curettes or machined driven instruments, since the stream of abrasive particles can remove biofilm residues which may remain after conventional instrumentation [23]. Recent data provide evidence suggesting that air polishing devices may represent a valuable modality for biofilm removal during SPT [24]. However, the rationale of performing repeated subgingival scaling at 3-month intervals for patients with persistent disease has been questioned [25], thus pointing to the need, in specific clinical scenarios, of using adjunctive antimicrobials having as main rationale the antimicrobial effect at sites that are inaccessible to mechanical therapy thus increasing the possibility of reaching and destroying remaining pathogens [26]. Local delivery systems containing antibiotic or antiseptic drugs allow therapeutic agents to target diseased sites with minimal systemic effects [27]. Compared to use of SRP only, the combined use of several local anti-infective agents and scaling and root planning (SRP) seems to provide additional benefits in PPD reduction and clinical attachment level (CAL) gain [28]. Within the last decade, topical slow-release antimicrobials, such as chlorhexidine, doxycycline, minocycline, and metronidazole, have been used subgingivally in conjunction with mechanical instrumentation during SPT [29–33]. Substantial evidence indicates that adding a chemotherapeutic agent to conventional SPT has an adjunctive effect in interrupting further periodontal disease progression, as observed in persistent or recurrent periodontitis after local use of doxycycline [6, 31, 34]. The adjunctive application of an antimicrobial agent may be also useful for patients with contraindications of surgery and patients with extreme sensitivity after active periodontal treatment [32].

A recent study [35] has evaluated the potential benefit of an enamel matrix derivative (EMD) as an adjunct to re-instrumentation of residual pockets during the step 3 of periodontal therapy [20]. The frequency of pocket closure in the test group was statistically significantly higher than in the control group at 6 months and was maintained up to 12 months.

Very recently, the use of sodium hypochlorite (NaOCl) has been also suggested as a possible alternative to improve the outcomes of subgingival SRP. This is mainly due to its broad antimicrobial activity, fast bactericidal action, and non-toxicity at application concentration [36, 37]. Histologically, subgingival application of (NaOCl) provides chemolysis of the soft tissue wall of the periodontal pocket with minimal effect on the adjacent tissues. Hence, its use in the maintenance phase of periodontal therapy has been recommended [38].

Antimicrobials which are currently use adjunctively in subgingival re-instrumentation during SPT (i.e., mainly antibiotics and CHX) have been associated with potential risks of antimicrobial resistance [37, 39]. For instance, the oral cavity has been highlighted as potential reservoir for antimicrobial resistance genes in numerous publications from recent years [40, 41]. NaOCl could be an interesting alternative because its mechanism of action is rather non-selective (oxidative burst) as opposed to antibiotics or CHX [42]. Thus, development of resistances toward NaOCl seems less likely as toward antibiotics or CHX.

Recently, a novel formulation of NaOCl gel (Perisolv, RLS Global AB, Gothenburg, Sweden) buffered with leucine, lysine, and glutamic acid was used as an adjunct to subgingival instrumentation [43] and re-instrumentation [44] for the treatment of peri-implant mucositis [45] and peri-implantitis [46]. The active ingredients in the gel create chloramines, which have a strong antimicrobial effect and can penetrate the biofilm [44], thus making an alternative approach to improve the outcomes of ultrasonic re-instrumentation (USI) procedures [47, 48]. An in vitro study indicated that the NaOCl gel had antimicrobial activity against Gram-negative species associated with periodontitis, although it failed to eliminate a multi-species biofilm [40].

The phase of therapy at which other topical slow-release antimicrobials are most beneficial remains unclear. However, these formulations appear to be most beneficial when used during SPT at non-responding or recurrent chronic inflammation sites [49].

Accordingly, to the best of our knowledge, at present, only one study has addressed the issue of topical NaOCl gel in re-instrumentation of persistent pockets during SPT [44]. However, in that study, the treatment consisted of repeated topical applications of the novel hypochlorite gel in conjunction with short-time ultrasonic debridement. As other studies have indicated, the existing data on the potential clinical relevance of local application of NaOCl gel used in conjunction with subgingival mechanical instrumentation remains limited [43].

Therefore, the aim of this triple-blinded randomized placebo-controlled clinical study was to compare the clinical and microbiological effects between the adjunctive subgingival administration of NaOCl gel and chlorhexidine and a placebo gel with subgingival re-instrumentation and air polishing during the first 12 months of SPT.

Material and methods

Study design

This study was conducted as a triple-blinded randomized placebo-controlled clinical trial of 12 months with a parallel design of three independent groups by a 1:1:1 allocation ratio. The study was approved by the Research Ethics Committee of the Victor Babes University of Medicine and Pharmacy Timisoara (approval no.1/21.01.2018). The study was conducted according to the principles outlined in the Declaration of Helsinki on human medical experimentation. All participants provided written informed consent, giving permission for the dental procedures and sampling of biological material. The study was conducted between January 2018 and September 2019. The study was registered in the ISRCTN Registry of Clinical Trials (ISRCTN11387188) and followed the guidelines described in the CONSORT 2010 statement on clinical trials.

Study population

Out of 85 randomly selected and screened patients, 62 patients agreed to participate in the study. The participants were randomly assigned to one of the three study groups: groups A, B, and C. Not more than 50% of the patients were smokers. With respect to smoking, the patients were distributed in three groups: smokers (> 10 cigarettes/day regularly), former smokers, and non-smokers [50].

Patients that were included in the study had completed APT and received SPT for a minimum of 6 months of documented SPT, until the desired number of participants was attained. APT was performed in a private practice in Timisoara, Romania, whereas SPT was performed in a private practice and in the Department of Periodontology, Victor Babes University of Medicine and Pharmacy, Timisoara, Romania. A flowchart of the study according to CONSORT is provided in Fig. 1.

The inclusion criteria were as follows:

(a) Patients aged 20–80 years
(b) Patients enrolled in SPT after at least 6 months following APT for periodontitis stages III–IV
(c) **A**t least four non-adjacent sites with PPDs ≥ 4 mm with BOP or PPDs > 5 mm, but not deeper than 8 mm, with or without BOP, needing retreatment ("reference sites") [6]
(d) Neither furcation involvement, nor third molars or severely malpositioned teeth
(e) Vital teeth or teeth with "lege-artis" root canal treatment
(f) Full mouth bleeding score (FMBS) ≤ 20%
(g) Full mouth plaque score (FMPS) ≤ 20%
(h) Mobility degree ≤ 2 [53]
(i) Patients treated (no surgical/surgical if indicated) in the same private practice where the study was conducted.
(j) Patients willing to provide written informed consent and willing to complete the 12-month study follow-up.

Exclusion criteria:

(a) Known allergies or adverse reactions to hypochlorite
(b) Clinically relevant psychological disorders
(c) Alcohol abuse
(d) HIV infection
(e) Self-reported diabetes mellitus
(f) Use of local or systemic administration of antibiotics during the last 3 months
(g) Pregnancy and breast feeding
(h) Heavy smokers. If progression of periodontal destruction was observed or if adverse reactions to the test product were reported, the participant was excluded from the study. Progression of periodontal destruction was defined as attachment loss > 2 mm or an increase in PPD > 2 mm between subsequent evaluations [6, 26].

Clinical examination

The clinical examination team included an examiner (specialist in periodontology), a randomizer, and an operator (specialist in periodontology) with at least 4 years of clinical experience. The intra-examiner calibration for reliability testing resulted in $\kappa = 0.92$ for repeated measurements of PPD and CAL in two quadrants of five patients, other than the patients recruited for the study. Periodontal diagnosis was made according to the new classification system for periodontal and peri-implant diseases and conditions (2018) [51]. Each patient's medical history was updated.

All clinical measurements (i.e., at baseline, at 3-, 6-, 9-, and 12-months) were performed by the same investigator (SS). Additionally, FMPS and FMBS were calculated [52]. PPD, gingival recessions (REC), and clinical attachment levels (CAL) were measured at six sites per tooth using a manual periodontal probe (PCP-UNC15, Hu-Friedy, Chicago, IL, USA). Measurements were recorded to the nearest millimeter. Mobility was recorded according to the Miller classification [53]. Periodontal parameters were recorded in the periodontal chart (http://www.periodontalchart-online.com/uk/), saved in "pdf" format, printed, and included the observation file of each patient.

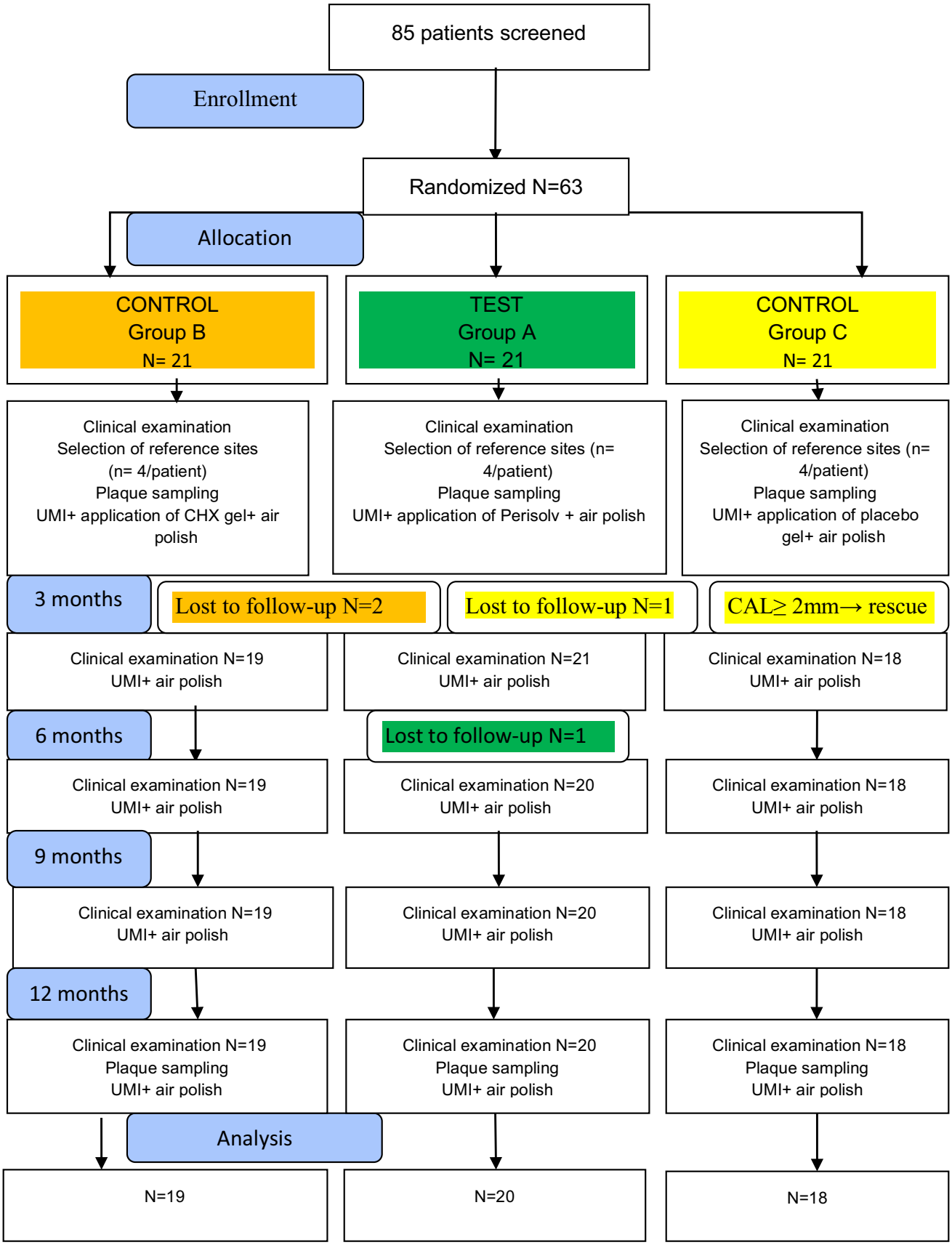

Fig. 1 CONSORT flow chart of patient enrolment and follow-up examination

Microbiological examination

To detect the selected bacteria, *Aggregatibacter actinomycetemcomitans* (*A.a.*), *Porphyromonas gingivalis* (*P.g.*), *Prevotella intermedia* (*P.i.*), *Tannerella forsythia* (*T.f.*), and *Treponema denticola* (*T.d.*), a molecular genetic analysis was performed. The semi-quantitative analysis of bacteria was assessed using the commercial kit, micro-IDent® plus (Hain Lifescience GmbH, Nehren, Germany), which is based on DNA STRIP technology. The microbiological samples were collected by the treating clinician (VR) from the teeth with the deepest PPD recorded at the initial evaluation. The microbiological samples at the 12-month re-evaluation time point were harvested exactly from the same sites. Subgingival plaque was collected for microbiological examination as follows. First, the site was isolated with cotton rolls. After removing the supragingival plaque and the debris with a sterile cotton gauze, the gingival surface was dried. The plaque samples were collected by inserting one sterile paper point ISO #30 in each one of the four reference sites and allowing them 30 s in situ for saturation [54]. The paper points were pooled immediately into sterile-sealed Eppendorf tubes and sent for polymerase chain reaction (PCR). The PCR testing was conducted in the laboratories of the Department of Biochemistry, Victor Babeş University of Medicine and Pharmacy. The cones were removed after 15 min of vortex mixing at room temperature, and the eluates were clarified by centrifugation for 5 min at 3000 × g at 23 °C. The samples were stored for one day at – 20 °C, and then at – 80 °C until the microbiological analysis was performed (not more than 30 days later).

Randomization and therapy assignment

Randomization was achieved using a number generator (www.randomizer.org) by a randomizer who was independent of the operator or evaluator. The randomizer ensured blinding by using a placebo gel similar in aspect and consistency to the test gel. Moreover, neither the patients, operator, nor clinical examiner knew the groups the patients were assigned. The computerized randomization assigned the patients to one of the three groups by an allocation ratio of 1:1:1. The randomizer performed the assignment to interventions, while a dental assistant performed the documentation. An allocation table containing the names of the patients was created and used to assign patient treatment numbers, as indicated by the randomization process. Each patient was given a sealed opaque envelope containing the treatment number.

SPT procedures

The operator (VA) performed the supragingival debridement (EMS Piezon® Master, EMS, Nyon, Switzerland) and air polishing (standard air-flow nozzle, AIRFLOW® PLUS powder (EMS, Nyon, Switzerland) at all sites. The reference sites and all sites presenting PPD ≥ 4 mm at baseline and 3-, 6-, and 9-month follow-up timepoints were re-instrumented with USI using fine subgingival inserts (PS (Perio Slim) EMS, Nyon, Switzerland) in the context of regular SPT. The NaOCl gel, chlorhexidine gel, or placebo gel was not reapplied at the 3-, 6-, and 9-month timepoints.

The investigated antimicrobial product (Perisolv®, Regedent AG, Zürich, Switzerland) consisted of two components contained in two separate interconnectable syringes: 0.95% sodium hypochlorite solution and transparent gel (the activating vehicle), containing amino acids (glutamic acid, leucine, lysine), carboxymethylcellulose, and ultrapure water. The two components were mixed before use to generate chloramines [44]. The chlorhexidine product (Clorhexamed® 1% gel, GSK, Germany) and placebo treatment consisted of gels with similar aspect and consistency as the test product, packaged in transparent syringes and identical with the syringe for the test product.

In group A, the reference sites were additionally treated as follows. According to the manufacturer's instructions, Perisolv® was applied by interconnecting the two syringes and mixing the liquids by alternately pushing the plungers. It was mixed until the liquid became homogeneous (10–15 cycles) and was then pushed into the transparent syringe. A blunt applicator was applied to this syringe and was inserted into the pocket mesially, lingually, distally, and buccally to cover the full circumference of the teeth and reach the bottom of the pocket. Perisolv® gel was left in situ for 30 s after application, followed by USI. After 15 min, Perisolv® was applied again, and teeth were re-instrumented subgingivally after 30 s using USI. Air polishing was used on all teeth to destroy the biofilm. In groups B and C, the reference sites were additionally treated with the chlorhexidine gel and placebo gel. The gels were applied in the same manner as in group A. For USI, no time limitations were set, and instrumentation was performed without local anesthesia until the treating clinician felt comfortable with the debrided root surfaces.

During the first periodontal re-evaluation, the investigator asked patients if any allergy or adverse reactions occurred after the treatment procedure, or if they had used medication that might interfere with the inclusion criteria. If necessary, the individual's oral hygiene was reinforced.

The participants were instructed to avoid using any other local or systemic antimicrobials. Oral hygiene instructions that were given to all participants during the initial periodontal therapy (i.e., use of rotary toothbrushing, dental floss, interdental brushes, pulsated water jet) were repeated and reinforced during each visit of the SPT. The timeline of the study is presented in Fig. 2.

Data analysis

The statistical analyses were performed using the software R version 4.0.0 (R Development Core Team, R Foundation

for Statistical Computing, Vienna, Austria) [55]. Statistical analysis was conducted intra- and inter-groups. The main outcome variable was pocket closure at the 12-month timepoint. Mean PPD changes, BOP, mean CAL changes, and the changes in the frequency detection scores of the five selected bacterial species were regarded as secondary outcomes. The sample size calculation was based on earlier reports on periodontal re-instrumentation [35, 56]. A minimal required sample size of 16 patients per group was required to achieve 80% power for detecting a statistically significant mean difference of 1 mm in the reduction of PPD between groups, assuming a common standard deviation of 0.8 mm and given significance level, $\alpha = 0.05$. The Pitman asymptotic relative efficiency correction was applied in the sample size computation to account for the use of nonparametric comparison tests. At least 18 patients were enrolled in each of the 3 groups to account for possible attrition. For each of the quantitative variable, PPD, REC, and CAL, a patient mean value was computed per timepoint, which was further used in the statistical analyses. For quantitative data, intergroup comparisons were made using the Kruskal–Wallis tests with Mann–Whitney post-hoc tests. Differences within each group from baseline to later timepoints (3, 6, 9, and 12 months) were analyzed using Wilcoxon signed-rank tests. Chi-squared tests or Fisher's exact tests, as appropriate, were used for comparisons between groups in the case of qualitative data. Statistical significance was set at $P < 0.05$.

Regarding the microbiological status, changes in the detection frequency scores of major keystone bacteria were assessed. Results were recorded and classified into one of the following categories: 0 = nondetectable, 1 = detectable $< 10^4$ (10^3 for *A.a*), 2 = 10^4–10^5 (10^3–10^4 for *A.a*), 3 = 10^5–10^6 (10^4–10^5 for *A.a*), and 4 $\geq 10^7$ (10^6 for *A.a*) [54]. Intra-group comparisons of detection scores of pathogen species between the baseline and 12-month re-evaluation timepoints were performed using Wilcoxon signed rank test. The Kruskal–Wallis test was used for inter-group comparisons of detection scores for each timepoint.

Results

No side or adverse effects related to any of the treatment procedures occurred in any of the patients. Table 1 presents the characteristics of the patients at baseline. Test and control groups showed no statistically significant differences regarding sex, smoking, age, FMPS, FMBS, and PPD at baseline. The intragroup distribution was well pondered. The PPD of the sites ranged from 4 to 7 mm at baseline. The mean PPD at baseline was 4.56 ± 0.46 mm for the Perisolv® group, 4.48 ± 0.36 mm for the chlorhexidine group, and 4.57 ± 0.46 mm for the placebo group (Table 2). Additionally, 83.75% of Perisolv® treated sites, 94.74% of chlorhexidine treated sites, and 95.83% of placebo sites were identified as BOP-positive after probing at baseline (Table 3).

Out of 85 individuals that were screened, 63 patients met the inclusion criteria, gave written informed consent to participate, and were included in the study. Due to attrition, 57 patients were available for examination after 12 months. During the study, two participants showed disease progression; therefore, they were excluded from the study to undergo standard therapy. Figure 1 presents the study flow chart according to the CONSORT guidelines.

Tooth types (incisors/canines/premolars/molars) of reference teeth were distributed among groups as follows: 15/9/26/30 for Perisolv®, 7/11/27/31 for Chlorhexidine, and 20/15/18/19 for placebo. A total of 228 reference sites

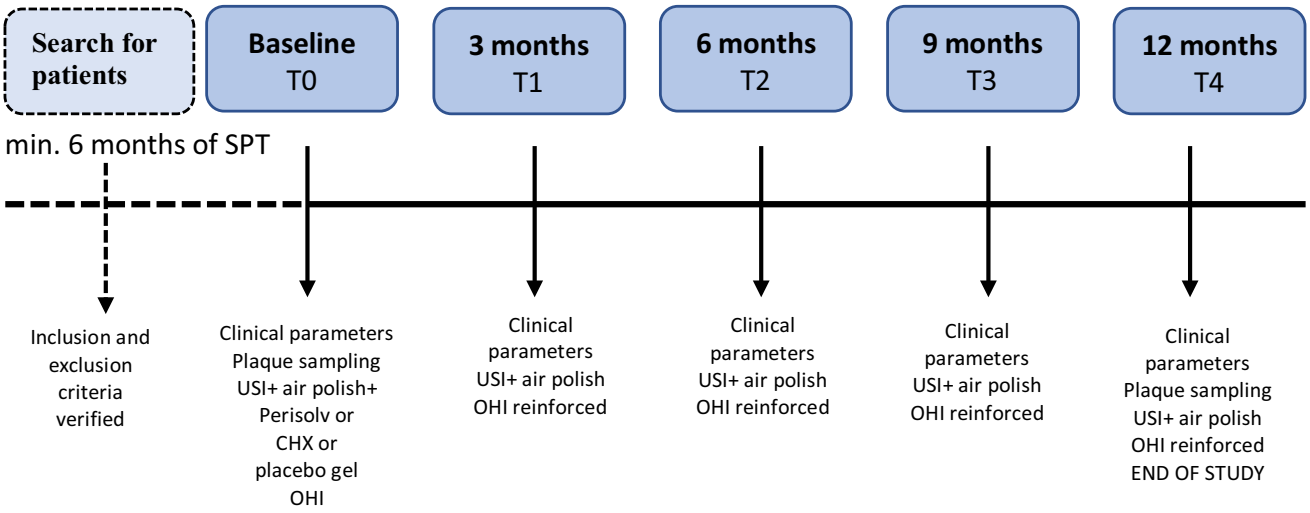

Fig. 2 Timeline of the study

Table 1 Characteristics of study participants at baseline

Parameter	Perisolv ($n=20$)	CHX ($n=19$)	Placebo ($n=18$)	p value
Age (years, mean ± SD)	44.60 ± 9.86	48.68 ± 11.63	50.61 ± 9.31	0.155[a]
Sex = female (n, %)	10 (50%)	8 (42.11%)	12 (66.67%)	0.313[b]
Smoker (n, %)	3 (15%)	3 (15.79%)	3 (16.67%)	1[c]
FMPS	15.10 ± 6.45	16.16 ± 6.11	16.33 ± 5.65	0.869[a]
FMBS	20.50 ± 4.32	20.16 ± 4.13	21.89 ± 2.11	0.608[a]
PPD = 4 mm (n, %)	46 (57.50%)	48 (63.16%)	39 (54.17%)	
PPD = 5 mm (n, %)	26 (23.50%)	22 (28.95%)	26 (36.11%)	
PPD = 6 mm (n, %)	5 (6.25%)	6 (7.89%)	6 (8.33%)	
PPD = 7 mm (n, %)	3 (3.75%)	0 (0%)	1 (1.39%)	

[a]Kruskal-Wallis test

[b]Chi-squared test

[c]Fisher's exact test

Table 2 Mean probing pocket depth (PPD) ± standard deviation (mm) at baseline and 3-, 6-, 9-, and 12-month timepoints in the treatment and control groups and p values of Kruskal–Wallis tests for intergroup comparisons

	PERISOLV	CHX	placebo	p-value
Baseline	4.56 ± 0.46	4.48 ± 0.36	4.57 ± 0.46	0.669
3 months	3.59 ± 0.42	3.66 ± 0.52	3.89 ± 0.64	0.127
Difference to baseline	0.98 ± 0.31	0.79 ± 0.36	0.68 ± 0.73	0.065
6 months	3.58 ± 0.35	3.76 ± 0.53	3.79 ± 0.72	0.343
Difference to baseline	0.99 ± 0.31	0.68 ± 0.45	0.78 ± 0.71	0.069
9 months	3.65 ± 0.43	3.71 ± 0.65	3.82 ± 0.58	0.524
Difference to baseline	0.91 ± 0.42	0.74 ± 0.58	0.75 ± 0.56	0.310
12 months	3.75 ± 0.47	3.84 ± 0.61	3.82 ± 0.57	0.934
Difference to baseline	0.81 ± 0.38	0.61 ± 0.52	0.75 ± 0.58	0.356

Table 3 Proportion of sites with BOP and p values of chi-squared tests for intergroup comparison

	PERISOLV	CHX	placebo	p-value
Baseline	67/80 (83.75%)	72/76 (94.74%)	69/72 (95.83%)	0.013
3 months	12/80 (15.00%)	15/76 (19.74%)	20/72 (27.78%)	0.147
6 months	18/80 (22.50%)	25/76 (32.89%)	20/72 (27.78%)	0.349
9 months	18/80 (22.50%)	22/76 (28.95%)	17/72 (23.61%)	0.615
12 months	10/80 (12.50%)	22/76 (28.95%)	23/72 (31.94%)	0.010

were treated. The four reference teeth were in different quadrants in 24 patients, and each reference site belonged to one reference tooth. The other 33 patients had a maximum of two reference teeth on the same quadrant (at least three teeth apart from each other), while the other two reference teeth were situated in the remaining three quadrants.

Table 4 Proportion of sites with pocket closure and p-values of chi-square tests for intergroup comparisons

	PERISOLV	CHX	placebo	p value
Baseline	0/80	0/76	0/72	–
3 months	64/80 (80.00%)	53/76 (69.74%)	46/72 (63.89%)	0.082
6 months	61/80 (76.25%)	51/76 (67.10%)	47/72 (65.28%)	0.281
9 months	61/80 (76.25%)	48/76 (63.16%)	46/72 (63.89%)	0.144
1 months	62/80 (77.50%)	48/76 (6 3.16%)	43/72 (59.72%)	0.044

The primary outcome variable, pocket closure (Table 4), defined as the transition of sites with PPD > 5 mm or 4 mm with BOP to non-bleeding sites with PPD ≤ 4 mm, was attained in 77.5% of Perisolv® sites after 12 months. The reduction was higher in the CHX group than in the sodium hypochlorite gel group. However, a significant adjunctive effect of Perisolv® ($P=0.028$) was observed, when compared with the placebo group only at the 12-month timepoint. Therefore, the hypothesis tested could be confirmed only for one arm.

Periodontal re-instrumentation caused clinical improvements in both control and test groups, showing reductions in mean PPD value at test and control sites between baseline and 3-month follow-up timepoint. The results were maintained at subsequent re-evaluations (Table 2). However, these improvements, as well as differences between groups, were not statistically significant at any time point. Marginally, statistically significant differences were observed at the 3- and 6-month timepoints, favoring Perisolv® over

CHX and placebo. After 12 months of maintenance therapy, the mean PPD value of the study sites was reduced by 0.81 ± 0.38 mm in the test group, by 0.61 ± 0.52 mm in the CHX group, and by 0.75 ± 0.58 mm in the placebo group.

The analysis of BOP changes at test and control sites (Table 3) shows that the proportion of BOP sites in the Perisolv® group was significantly lower than in the CHX and placebo groups at baseline and at the 12-month timepoint. No difference in BOP incidence was recorded at 3-, 6-, and 9-month timepoints among study groups. The intra-group analysis showed an important decrease in the number of sites with BOP at the 3-month timepoint, followed by a stabilization tendency in all groups.

No statistically significant differences were identified in terms of REC changes among the study groups at any timepoint (Table 5). The intra-group analysis showed a statistically significant increase at 3-, 6-, and 9-month timepoint (Wilcoxon test, $P < 0.05$) from 0.29 ± 0.43 and 0.30 ± 0.57 to 0.40 ± 0.44 and 0.51 ± 0.67 for Perisolv and CHX group, respectively.

Although no statistically significant differences in terms of CAL changes were found among the groups at any timepoint (Table 6), an improvement occurred in all three groups compared to baseline (Wilcoxon tests, $P < 0.005$). Differences were observed among the groups when comparing the values from baseline with those from the 6-month timepoint (Kruskal–Wallis test, $P = 0.010$). Mann–Whitney post-hoc tests revealed that these differences were due to the more important 6-month CAL gain in the Perisolv® group than in the CHX group ($P = 0.0026$).

The intra-group analysis reveals a statistically significant decrease in detection scores from baseline to 12 months for *P.g.* (Perisolv®, CHX, and placebo group with *P* values of 0.015, 0.004, 0.002, respectively), *P.i.* (placebo group, $P = 0.049$), *T.f.* (Perisolv®, CHX, and placebo group, *P* value of 0.004, 0.003, and 0.010, respectively), and *T.d.* (Perisolv® and placebo groups with *P* value of 0.005 and 0.040, respectively). The inter-group analysis showed no statistically significant differences in the detection scores for *A.a.*, *P.g.*, *P.i.*, *T.f.*, and *T.d.* among the three groups, either at baseline or after 12 months (Table 7). In all three groups, pathogen detection scores either decreased over time or remained constant, with very few exceptions.

Table 5 Mean gingival recession (REC) ± standard deviation (mm) at baseline, 3, 6, 9, and 12 months in the treatment and control groups and p-values of Kruskal–Wallis tests for intergroup comparisons

	PERISOLV	CHX	placebo	*p*
Baseline	0.29 ± 0.43	0.30 ± 0.57	0.47 ± 0.69	0.635
3 months	0.43 ± 0.45	0.46 ± 0.66	0.58 ± 0.72	0.875
Difference to baseline	0.14 ± 0.19	0.16 ± 0.28	0.11 ± 0.23	0.656
6 months	0.40 ± 0.44	0.57 ± 0.67	0.61 ± 0.70	0.787
Difference to baseline	0.11 ± 0.21	0.26 ± 0.36	0.14 ± 0.25	0.299
9 months	0.36 ± 0.36	0.55 ± 0.69	0.61 ± 0.71	0.731
Difference to baseline	0.08 ± 0.28	0.25 ± 0.39	0.14 ± 0.26	0.496
12 months	0.40 ± 0.44	0.51 ± 0.67	0.65 ± 0.71	0.683
Difference to baseline	0.11 ± 0.15	0.21 ± 0.35	0.18 ± 0.32	0.781

Table 6 Mean clinical attachment level (CAL) ± standard deviation (mm) at baseline and 3-, 6-, 9-, and 12-month timepoints in the treatment and control groups and *p* values of Kruskal–Wallis tests for intergroup comparisons

	PERISOLV	CHX	placebo	*p*-value
Baseline	4.85 ± 0.70	4.75 ± 0.61	5.04 ± 0.82	0.531
3 months	4.01 ± 0.68	4.12 ± 0.65	4.47 ± 0.83	0.161
Difference to baseline	0.84 ± 0.37	0.63 ± 0.36	0.57 ± 0.60	0.078
6 months	3.98 ± 0.60	4.33 ± 0.64	4.40 ± 0.96	0.191
Difference to baseline	0.88 ± 0.35	0.42 ± 0.37	0.64 ± 0.62	0.010
9 months	4.01 ± 0.68	4.26 ± 0.70	4.43 ± 0.78	0.276
Difference to baseline	0.84 ± 0.46	0.49 ± 0.43	0.61 ± 0.46	0.062
12 months	4.15 ± 0.73	4.36 ± 0.69	4.47 ± 0.78	0.460
Difference to baseline	0.70 ± 0.40	0.39 ± 0.38	0.57 ± 0.50	0.095

Discussion

This study sought to evaluate the benefit of a single subgingival application of a low concentration hypochlorite/amino acid gel associated with subgingival USI and air polish in residual pockets ≥ 4 mm with positive BOP or residual pockets > 5 mm over a year of SPT.

The rationale for supplementary efforts aiming at improving periodontal maintenance and early intervention during SPT is confirmed by earlier observations that the current standard, based on repeated mechanical re-instrumentation of sites ≥ 4 mm and positive BOP, patient motivation, and oral hygiene instructions, is unable to control inflammation in more than 50% of sites. Although mechanical treatment substantially decreases the counts of subgingival microorganisms, it does not necessarily eliminate all periodontal pathogens [57].

The recently published S3-level clinical guideline for the treatment of periodontitis [20] tackles decision-making for retreatment after step 2 therapy (initial non-surgical phase). Based on the findings from a systematic review [58], it is recommended to re-instrument residual pockets with a PPD of 5 mm by a non-surgical approach. Residual pockets of ≥ 6 mm should be reduced by periodontal surgery to reach the endpoint of active therapy (PPD ≤ 4 mm, without BOP).

Table 7 Detection frequency scores for *A.a*, *P.g*, *P.i*, *T.f*, *T.d* at baseline and 12-month timepoint

Species	Timepoint	Detection score	PERISOLV	CHX	placebo	*p*-value**
A.a	Baseline	0	15 (75%)	14 (73.68%)	16 (88.88%)	0.408
		1	1 (5%)	1 (5.26%)	–	
		2	–	–	1 (5.56%)	
		3	1 (5%)	2 (10.53%)	1 (5.56%)	
		4	3 (15%)	2 (10.53%)	–	
	12 months	0	17 (85%)	16 (84.21%)	18 (100%)	0.218
		1	2 (10%)	1 (5.26%)	–	
		2	–	1 (5.26%)	–	
		3	1 (5%)	–	–	
		4	–	1 (5.26%)	–	
	p value*		0.098	0.181	0.371	
P.g	Baseline	0	6 (30%)	3 (15.79%)	1 (5.56%)	0.935
		1	1 (5%)	3 (15.79%)	1 (5.56%)	
		2	1 (5%)	1 (5.26%)	4 (22.22%)	
		3	3 (15%)	5 (26.32%)	6 (33.33%)	
		4	9 (45%)	7 (36.84%)	6 (33.33%)	
	12 months	0	11 (55%)	12 (63.16%)	9 (50%)	0.529
		1	1 (5%)	3 (15.79%)	–	
		2	2 (10%)	1 (5.26%)	2 (11.11%)	
		3	4 (20%)	–	3 (16.67%)	
		4	2 (10%)	3 (15.79%)	4 (22.22%)	
	p value*		**0.015**	**0.004**	**0.002**	
P.i	Baseline	0	5 (25%)	8 (42.10%)	6 (33.33%)	0.529
		1	4 (20%)	2 (10.53%)	1 (5.56%)	
		2	5 (25%)	6 (31.58%)	6 (33.33%)	
		3	6 (30%)	3 (15.79%)	5 (27.78%)	
		4	–	–	–	
	12 months	0	9 (45%)	12 (63.16%)	11 (61.11%)	0.354
		1	4 (20%)	3 (15.79%)	–	
		2	2 (10%)	4 (21.05%)	3 (16.67%)	
		3	5 (25%)	–	4 (22.22%)	
		4	–	–	–	
	p value*		0.121	0.095	**0.049**	
T.f	Baseline	0	–	–	–	0.325
		1	1 (5%)	1 (5.26%)	–	
		2	2 (10%)	2 (10.53%)	1 (5.56%)	
		3	4 (20%)	4 (21.05%)	11 (61.11%)	
		4	13 (65%)	12 (63.16%)	6 (33.33%)	
	12 months	0	8 (40%)	9 (47.37%)	6 (33.33%)	0.877
		1	1 (5%)	1 (5.26%)	1 (5.56%)	
		2	-	1 (5.26%)	1 (5.56%)	
		3	5 (25%)	2 (10.53%)	5 (27.78%)	
		4	6 (30%)	6 (31.58%)	5 (27.78%)	
	p value*		**0.004**	**0.003**	**0.010**	

Table 7 (continued)

Species	Timepoint	Detection score	PERISOLV	CHX	placebo	*p*-value**
T.d	Baseline	0	3 (15%)	4 (21.05%)	2 (11.11%)	0.121
		1	–	4 (21.05%)	7 (38.89%)	
		2	11 (55%)	9 (47.37%)	6 (33.33%)	
		3	6 (30%)	2 (10.53%)	3 (16.67%)	
		4	–	–	–	
	12 months	0	9 (45%)	8 (42.10%)	6 (33.33%)	0.860
		1	3 (15%)	5 (26.32%)	5 (27.78%)	
		2	4 (20%)	5 (26.32%)	6 (27.78%)	
		3	4 (20%)	1 (5.26%)	1 (5.56%)	
		4	–	–	–	
	p value*		**0.005**	0.078	**0.040**	

Data presented as frequencies (%)

* Corresponding to Wilcoxon tests for intra-group comparison of pathogen detection scores between successive timepoints

** Corresponding to Kruskal–Wallis tests for inter-group comparisons of pathogen detection scores for each timepoint

However, in the present study, a reduced number of sites with PD = 7 mm (3 in the test and one in the placebo group) were re-instrumented.

In a clinical trial from 1998 on chronic periodontitis [7], the authors noted that the average number of bleeding pockets per patient doubled over 5 years of SPT. PPD of 5 mm seemed to represent a risk factor for tooth loss, whereas residual PPD ≥ 6 mm represented an incomplete periodontal treatment outcome requiring further therapy [8]. The most relevant parameters used to assess the capacity of maintaining periodontal health and making supportive treatment useful are the percentage of sites with BOP and prevalence of residual pockets > 4 mm [59, 60]. These two parameters are easily affected by therapy.

Concurrently, the influence residual inflammation evidenced by BOP on tooth loss was addressed in many studies [60, 61]. Thus, the absence of BOP and PPD ≤ 4 mm (closed pockets) as clinical endpoints of treatment success is justified [17, 18]. According to Chapple et al. [19], periodontal stability is defined by a successful treatment resulting in minimal BOP (< 10% of sites) and PPD < 4 mm. For other authors [62], the reduction of PPD on a physiological level of up to 3 mm, which is the clinical pocket closure, remains the most important end parameter for clinically applicable success estimation after periodontal treatment.

Previous studies have assessed the effect of various adjunctive topical antimicrobial products in enhancing the outcomes of subgingival re-instrumentation of residual pockets during SPT [6, 30–32]. A recent study about the benefit of enamel matrix derivative (EMD) as an adjunct to re-instrumentation of residual pockets [35] was conducted according to the recently published S3-level clinical guideline for the treatment of periodontitis [20]. In that study, the authors explored the benefits of EMD as an adjunct to re-instrumentation of residual deep pockets with a PPD of 5–8 mm. The primary outcome was the change in mean PPD after 6 months. A statistically significant additional benefit of 0.79 ± 1.3 mm was observed in the test group and could be maintained until 12 months (0.85 ± 1.1 mm). In the present study, an additional benefit of 0.99 ± 0.31 mm was attained after 6 months for the test group and was maintained at the 12-month timepoint (0.81 ± 0.38 mm), although it was not statistically significant.

Regarding the change of residual deep sites to sites with shallow probing depth (PPD ≤ 4 mm), the frequency of conversion amounted to 76% at the 6-month timepoint and 80% at the 12-month timepoint for the test sites, compared to 46% and 45% for the control sites. In the present study, the frequency of PPD reduction was 76.25% at the 6-month timepoint and 77.50% at the 12-month timepoint for the test group and 63.89% at the 6-month timepoint and 59.72% at the 12-month timepoint for the placebo group. In addition, for the primary outcome, pocket closure at the 12-month timepoint, a statistically significant effect was demonstrated in favor of the test group when compared with the placebo group ($P < 0.05$). Hence, the hypothesis of the study could be confirmed.

In our study, patients' level of hygiene improved markedly during the SPT. The intra-group analysis showed a statistically significant reduction in FMPS at the 12-month timepoint, compared to the baseline in all three groups (Wilcoxon test, $P < 0.05$), which in turn points to the excellent compliance of the patients.

In a previous study, the authors tested the probability of pocket closure after using locally delivered doxycycline as an adjunct to subgingival re-instrumentation [56]. The estimated probability for a site to reach the successful treatment endpoint of pocket closure (defined in the study as PPD ≤ 4 mm regardless BOP) was 45% at 3 months and 53% at 9 months for the test sites, compared to 46% and 45%, respectively, for the control sites. In the present study, the frequency of conversion of residual deep sites to sites with shallow probing depth (PPD ≤ 4 mm) attained 80.00% at 3 months and 76.25% at 9 months for test group, and 63.89% at 3 months and 63.89% at 9 months for placebo group, respectively. Previous studies [56] reported that the probability of pocket closure was not improved by the adjunctive topical doxycycline therapy. However, in our study, a statistically significant effect was demonstrated in favor of the test group, when compared to the placebo group at the 12-month timepoint. In the same study, the test group showed a mean PPD reduction of 1.1 mm after 9 months, which is consistent with our results. An additional benefit of 0.91 ± 0.42 mm was attained after 9 months in the test group and was maintained at the 12-month timepoint (0.81 ± 0.38) but was not statistically significant.

Our study revealed that repeated short USI during periodontal maintenance, with or without single adjunctive administration of antimicrobials, resulted in statistically significant improvements in mean CAL in all three groups at all timepoints, compared to baseline ($P < 0.05$). The inter-group analysis showed minor CAL improvements in favor of the Perisolv® group, when compared with both CHX and placebo groups (mean change, 0.70 ± 0.40 mm vs. 0.39 ± 0.38 mm and vs. 0.57 ± 0.50 mm at the 12-month timepoint). However, no statistically significant differences were found, except for the CAL changes in the Perisolv® group compared to the CHX group at the 6-month re-timepoint evaluation ($P = 0.0026$). These results are consistent with those reported in a previous clinical study with repeated topical administration of Perisolv® in 32 patients with at least 3 months of SPT [44]. The authors reported clinically relevant CAL gain and PD reduction of 1 mm in 1 year, without inducing further recession after 3 repeated short (1 min) USI with adjunctive administration of the antimicrobial product. Despite the measured improvements, no statistically significant difference was observed between the test and control (USI only). These results appear to suggest that a single topical administration of Perisolv® during periodontal re-instrumentation is sufficient to induce a clinically measurable effect.

It is important to consider that the participants of this study presented residual periodontal pockets, following active periodontal treatment consisting of nonsurgical or/and surgical therapy. A previous study [44] has suggested that the persistence of the pockets was caused by incomplete removal of microbial deposits during nonsurgical therapy.

Another study reporting on 202 periodontal maintenance participants (minimum of 6 months of SPT) with recurrent or persistent pockets, treated using USI (with [test] or without [control]). Participants received a slow-released doxycycline (SRD) in all residual periodontal pockets of > 4 mm [6]. Although the patients received a full cycle of periodontal therapy with periodontal surgery if indicated, a single topical administration of SRD caused a modest adjunctive benefit for 3 months only. These differences may on one hand be explained by differences in baseline PPD values (i.e., in the aforementioned study the PPD values measured ≥ 5 mm at baseline while in the present study the baseline values measured at least PPD ≥ 4 mm with BOP(+). One the other hand, the results might have also been influenced by the locally applied materials (i.e., SRD, Perisolv® and CHX, respectively).

Findings of a previous "in-vitro" study revealed that cell survival and repopulation of root surfaces is possible following either air polishing or application with Perisolv®. Moreover, it has been also shown that Perisolv® clearly reduces the vitality of the microorganisms despite failing to completely eliminate the biofilm [63]. Thus, the present study used air polishing only supragingivally to avoid influencing the outcomes of the use of Perisolv® in pockets deeper than 4 mm. At this point, it is important to mention that a statistically significant CAL gain was measured event after 6 months which in turn, points to the potential clinical relevance of using Perisolv® in residual pockets in patients enrolled in SPT.

The choice of the PCR method in the context of the currently accepted host-mediated dysbiosis of the subgingival microbiota associated with the exaggerated host response was based on the finding that recolonization by the key stone pathogen *P.g.* might play an important role in the pathogenesis of recurrent periodontitis during SPT [64] while other microbiological assessments of patients under SPT focused on the same bacteria as in our study [32, 44].The microbiological results showed no statistically significant differences among the groups at any timepoint. The intra-group comparison revealed a significant decrease in detection scores between baseline and the 12-month timepoint for *P.g.*, *P.i.*, *T.f.*, and *T.d.*. A statistically significant decrease was observed in the bacterial species, which presented relatively high counts at baseline. However, this was not the situation for *A.a.* which presented low counts at baseline with low frequency detection scores. These intra-group microbiological results compare favorably with those obtained in a similar study with repeated applications of Perisolv® [44]. The authors observed a statistically significant longitudinal reduction for only *T.f.* in the test group from baseline to day 7 and for *T.d.* from baseline to month 4. This reduction in the numbers of *T.f.* seems to correlate with the constantly improved FMPS score observed in all groups during the follow-up timepoints. Like in the above-mentioned study, no inter-group statistically significant differences were observed in our study.

Time of application and the costs of the antimicrobials are other factors that should be taken into consideration, even if not specifically addressed in our study. Since the time of

application for both products seem to be similar, an eventual cost difference between the two products could be compensated in time by the reduction of the number of residual pockets, as shown by our results in the Perisolv group. This may lead to fewer sites in need of re-instrumentation during the continuous care follow-up appointments.

Conclusion

Within their limits, the present results suggest that in patients treated for stage III–IV periodontitis and enrolled in SPT, treatment of residual pockets by means of subgingival USI and a single application of a sodium hypochlorite gel may lead to substantial clinical benefits evidenced by pocket closure.

Author contribution Conceptualization: Viorelia Radulescu, Stefan-Ioan Stratul; methodology: Darian Rusu, Giorgios Kardaras; formal analysis and investigation: Viorelia Radulescu; writing—original draft preparation: Marius Ion Boariu, Vincenzo Iorio Siciliano, Octavia Vela; writing—review and editing: Alexandra Roman, Petra Surlin, Andreea Cristiana Didilescu; supervision: Stefan-Ioan Stratul, Anton Sculean, Holger Jentsch, Luca Ramaglia.Viorelia Radulescu and Darian Rusu have equally contributed and can be both considered as first authors. All authors commented on previous versions of the manuscript, read, and approved the final manuscript.

Funding No funding was obtained for this study.

Declarations

Ethics approval The study was approved by the Research Ethics Committee of the Victor Babes University of Medicine and Pharmacy Timisoara (approval no.1/21.01.2018).

Informed consent All study participants provided written informed consent.

Conflict of interest The authors declare conflict of interest.

References

1. Joseph S, Curtis MA (2021) Microbial transitions from health to disease. Periodontol 2000 86(1):201–209. https://doi.org/10.1111/prd.12377
2. Jakubovics NS, Goodman SD, Mashburn-Warren L, Stafford GP, Cieplik F (2021) The dental plaque biofilm matrix. Periodontol 2000 86(1):32–56. https://doi.org/10.1111/prd.12361
3. Sedghi L, DiMassa V, Harrington A, Lynch SV, Kapila YL (2021) The oral microbiome: Role of key organisms and complex networks in oral health and disease. Periodontol 2000 87(1):107–131. https://doi.org/10.1111/prd.12393
4. Darveau RP, Curtis MA (2021) Oral biofilms revisited: a novel host tissue of bacteriological origin. Periodontol 2000 86(1):8–13. https://doi.org/10.1111/prd.12374
5. Hajishengallis G, Lamont RJ (2021) Polymicrobial communities in periodontal disease: Their quasi-organismal nature and dialogue with the host. Periodontol 2000 86(1):210–230. https://doi.org/10.1111/prd.12371
6. Tonetti MS, Lang NP, Cortellini P et al (2012) Effects of a single topical doxycycline administration adjunctive to mechanical debridement in patients with persistent/recurrent periodontitis but acceptable oral hygiene during supportive periodontal therapy. J Clin Periodontol 39(5):475–482
7. Tonetti MS, Muller-Campanile V, Lang NP (1998) Changes in the prevalence of residual pockets and tooth loss in treated periodontal patients during a supportive maintenance care program. J Clin Periodontol 25(12):1008–1016
8. Matuliene G, Pjetursson BE, Salvi GE et al (2008) Influence of residual pockets on progression of periodontitis and tooth loss: results after 11 years of maintenance. J Clin Periodontol 35(8):685–695
9. Lindhe J, Westfelt E, Nyman S, Socransky SS, Haffajee AD (1984) Long-term effect of surgical/non-surgical treatment of periodontal disease. J Clin Periodontol 11(7):448–458
10. Manresa C Sanz-Miralles EC Twigg J Bravo M (2018) Supportive periodontal therapy (SPT) for maintaining the dentition in adults treated for periodontitis. Cochrane Database Syst Rev 1(1):CD009376
11. Armitage GC, Xenoudi P (2016) Post-treatment supportive care for the natural dentition and dental implants. Periodontol 2000 71(1):164–184
12. Fardal Ø, Johannessen AC, Linden GJ (2004) Tooth loss during maintenance following periodontal treatment in a periodontal practice in Norway. J Clin Periodontol 31(7):550–555
13. Farooqi OA, Wehler CJ, Gibson G, Jurasic MM, Jones JA (2015) Appropriate recall interval for periodontal maintenance: a systematic review. J Evid Based Dent Pract 15(4):171–181
14. De Wet LM, Slot DE, Van der Weijden GA (2018) Supportive periodontal treatment: Pocket depth changes and tooth loss. Int J Dent Hyg 16(2):210–218
15. Graetz C, Plaumann A, Schlattmann P et al (2017) Long-term tooth retention in chronic periodontitis—results after 18 years of a conservative periodontal treatment regimen in a university setting. J Clin Periodontol 44(2):169–177
16. Nibali L, Sun C, Akcalı A, Meng X, Tu YK, Donos N (2017) A retrospective study on periodontal disease progression in private practice. J Clin Periodontol 44(3):290–297
17. Tomasi C, Wennström JL (2017) Is the use of differences in the magnitude of CAL gain appropriate for making conclusions on the efficacy of non-surgical therapeutic means? J Clin Periodontol 44(6):601–602
18. Loos BG, Needleman I (2020) Endpoints of active periodontal therapy. J Clin Periodontol 47:61–71
19. Chapple ILC, Mealey BL, Van Dyke TE et al (2018) Periodontal health and gingival diseases and conditions on an intact and a reduced periodontium: consensus report of workgroup 1 of the 2017 World Workshop on the Classification of Periodontal and Peri-Implant Diseases and Conditions. J Periodontol 89(Suppl 1):S74–S84
20. Sanz M, Herrera D, Kebschull M et al (2020) Treatment of stage I-III periodontitis-The EFP S3 level clinical practice guideline. J Clin Periodontol 47(Suppl 22):4–60
21. Bastendorf KD, Strafela-Bastendorf N, Lussi A (2021) Mechanical removal of the biofilm: is the curette still the gold standard? Monogr Oral Sci 29:105–118

22. Sanz I, Alonso B, Carasol M, Herrera D, Sanz M (2012) Nonsurgical treatment of periodontitis. J Evid Based Dent Pract 12(3 Suppl):76–86
23. Petersilka GJ (2011) Subgingival air-polishing in the treatment of periodontal biofilm infections. Periodontol 2000 55(1):124–142
24. Ng E, Byun R, Spahr A, Divnic-Resnik T (2018) The efficacy of air polishing devices in supportive periodontal therapy: a systematic review and meta-analysis. Quintessence Int 49(6):453–467
25. Jenkins WM, Said SH, Radvar M, Kinane DF (2000) Effect of subgingival scaling during supportive therapy. J Clin Periodontol 27(8):590–596
26. Harks I, Koch R, Eickholz P et al (2015) Is progression of periodontitis relevantly influenced by systemic antibiotics? A clinical randomized trial. J Clin Periodontol 42(9):832–842
27. Goodson JM (2000) Antimicrobial strategies for treatment of periodontal diseases. Periodontol 1994(5):142–168
28. Hanes PJ, Purvis JP (2003) Local anti-infective therapy: pharmacological agents. A Syst Rev Ann Periodontol 8(1):79–98
29. Perinetti G, Paolantonio M, Cordella C, D'Ercole S, Serra E, Piccolomini R (2004) Clinical and microbiological effects of subgingival administration of two active gels on persistent pockets of chronic periodontitis patients. J Clin Periodontol 31(4):273–281
30. Kasaj A, Chiriachide A, Willershausen B (2007) The adjunctive use of a controlled-release chlorhexidine chip following treatment with a new ultrasonic device in supportive periodontal therapy: a prospective, controlled clinical study. Int J Dent Hyg 5(4):225–231
31. Dannewitz B, Lippert K, Lang NP, Tonetti MS, Eickholz P (2009) Supportive periodontal therapy of furcation sites: non-surgical instrumentation with or without topical doxycycline. J Clin Periodontol 36(6):514–522
32. McColl E, Patel K, Dahlen G et al (2006) Supportive periodontal therapy using mechanical instrumentation or 2% minocycline gel: a 12month randomized, controlled, single masked pilot study. J Clin Periodontol 33(2):141–150
33. Salvi GE, Mombelli A, Mayfield L et al (2002) Local antimicrobial therapy after initial periodontal treatment. J Clin Periodontol 29(6):540–550
34. Eickholz P, Kim TS, Bürklin T et al (2002) Non-surgical periodontal therapy with adjunctive topical doxycycline: a double-blind randomized controlled multicenter study. J Clin Periodontol 29(2):108–117
35. Jentsch HFR, Roccuzzo M, Pilloni A, Kasaj A, Fimmers R, Jepsen S (2021) Flapless application of enamel matrix derivative in periodontal retreatment: a multicentre randomized feasibility trial. J Clin Periodontol 48(5):659–667
36. Jurczyk K, Nietzsche S, Ender C, Sculean A, Eick S (2016) In-vitro activity of sodium-hypochlorite gel on bacteria associated with periodontitis. Clin Oral Investig 20(8):2165–2173
37. Slots J (2002) Selection of antimicrobial agents in periodontal therapy. J Periodontal Res 37(5):389–398
38. Kalkwarf KL, Tussing GJ, Davis MJ (1982) Histologic evaluation of gingival curettage facilitated by sodium hypochlorite solution. J Periodontol 53(2):63–70
39. Gilbert P, Moore LE (2005) Cationic antiseptics: diversity of action under a common epithet. J Appl Microbiol 99(4):703–715
40. Conrads G, Klomp T, Deng D, Wenzler JS, Braun A, Abdelbary MMH (2021) The Antimicrobial susceptibility of porphyromonas gingivalis: genetic repertoire, global phenotype, and review of the literature. Antibiot (Basel) 10(12):1438
41. RaheemLateef Al-Awsi G, Al-Hadeithi ZSM, AbdalkareemJasim S, Alkhudhairy MK, Ghasemian A (2022) Virulence traits and plasmid-mediated quinolone resistance among Aggregatibacter actinomycetemcomitans from Iraq: Low rate of highly virulent JP2 genotype. Microb Pathog 164:105438
42. del Carpio-Perochena A, Bramante CM, de Andrade FB et al (2015) Antibacterial and dissolution ability of sodium hypochlorite in different pHs on multi-species biofilms. Clin Oral Investig 19(8):2067–2073
43. Iorio-Siciliano V, Ramaglia L, Isola G, Blasi A, Salvi GE, Sculean A (2021) Changes in clinical parameters following adjunctive local sodium hypochlorite gel in minimally invasive nonsurgical therapy (MINST) of periodontal pockets: a 6-month randomized controlled clinical trial. Clin Oral Investig 25(9):5331–5340
44. Megally A, Zekeridou A, Cancela J, Giannopoulou C, Mombelli A (2020) Short ultrasonic debridement with adjunctive low-concentrated hypochlorite/amino acid gel during periodontal maintenance: randomized clinical trial of 12 months. Clin Oral Investig 24(1):201–209
45. Iorio-Siciliano V, Blasi A, Stratul SI et al (2020) Anti-infective therapy of peri-implant mucositis with adjunctive delivery of a sodium hypochlorite gel: a 6-month randomized triple-blind controlled clinical trial. Clin Oral Investig 24(6):1971–1979
46. Roos-Jansåker AM, Almhöjd US, Jansson H (2017) Treatment of peri-implantitis: clinical outcome of chloramine as an adjunctive to non-surgical therapy, a randomized clinical trial. Clin Oral Implants Res 28(1):43–48
47. Gottardi W, Nagl M (2010) N-chlorotaurine, a natural antiseptic with outstanding tolerability. J Antimicrob Chemother 65(3):399–409
48. Gottardi W, Debabov D, Nagl M (2013) N-chloramines, a promising class of well-tolerated topical anti-infectives. Antimicrob Agents Chemother 57(3):1107–1114
49. Rodrigues IF, Machion L, Casati MZ et al (2007) Clinical evaluation of the use of locally delivered chlorhexidine in periodontal maintenance therapy. J Periodontol 78(4):624–628
50. Tonetti MS, Pini-Prato G, Cortellini P (1995) Effect of cigarette smoking on periodontal healing following GTR in infrabony defects A preliminary retrospective study. J Clin Periodontol 22(3):229–234
51. Caton JG, Armitage G, Berglundh T et al (2018) A new classification scheme for periodontal and peri-implant diseases and conditions—introduction and key changes from the 1999 classification. J Clin Periodontol 45(Suppl 20):S1–S8
52. O'Leary TJ, Drake RB, Naylor JE (1972) The plaque control record. J Periodontol 43(1):38
53. Miller SC (1950) Textbook of Periodontia. Blakiston Co, Philadelphia, p 91
54. Rusu D, Stratul SI, Sarbu C et al (2017) Evaluation of a hydrophobic gel adhering to the gingiva in comparison with a standard water-soluble 1% chlorhexidine gel after scaling and root planing in patients with moderate chronic periodontitis A randomized clinical trial. Int J Dent Hyg 15(1):53–64
55. R Core Team: a language and environment for statistical computing. Foundation for Statistical Computing Vienna p201 2017
56. Tomasi C, Koutouzis T, Wennström JL (2008) Locally delivered doxycycline as an adjunct to mechanical debridement at retreatment of periodontal pockets. J Periodontol 79(3):431–439
57. Haffajee AD, Cugini MA, Dibart S, Smith C, Kent RL Jr, Socransky SS (1997) The effect of SRP on the clinical and microbiological parameters of periodontal diseases. J Clin Periodontol 24(5):324–334
58. Sanz-Sánchez I, Montero E, Citterio F, Romano F, Molina A, Aimetti M (2020) Efficacy of access flap procedures compared to subgingival debridement in the treatment of periodontitis A systematic review and meta-analysis. J Clin Periodontol 47(Suppl 22):282–302
59. Lang NP, Tonetti MS (2003) Periodontal risk assessment (PRA) for patients in supportive periodontal therapy (SPT). Oral Health Prev Dent 1(1):7–16

60. Schätzle M, Löe H, Lang NP, Bürgin W, Anerud A, Boysen H (2004) The clinical course of chronic periodontitis. J Clin Periodontol 31(12):1122–1127
61. Lang NP, Adler R, Joss A, Nyman S (1990) Absence of bleeding on probing An indicator of periodontal stability. J Clin Periodontol 17(10):714–721
62. Kolakovic M, Held U, Schmidlin PR, Sahrmann P (2014) An estimate of pocket closure and avoided needs of surgery after scaling and root planing with systemic antibiotics: a systematic review. BMC Oral Health 14:159
63. Schmidlin PR, Fujioka-Kobayashi M, Mueller HD, Sculean A, Lussi A, Miron RJ (2017) Effects of air polishing and an amino acid buffered hypochlorite solution to dentin surfaces and periodontal ligament cell survival, attachment, and spreading. Clin Oral Investig 21(5):1589–1598
64. Fujise O, Miura M, Hamachi T, Maeda K (2006) Risk of Porphyromonas gingivalis recolonization during the early period of periodontal maintenance in initially severe periodontitis sites. J Periodontol 77(8):1333–1339

Authors and Affiliations

Viorelia Radulescu[1] · Marius Ion Boariu[2] · Darian Rusu[1] · Alexandra Roman[3] · Petra Surlin[4] · Adrian Voicu[5] · Andreea Cristiana Didilescu[6] · Holger Jentsch[7] · Vincenzo Iorio Siciliano[8] · Luca Ramaglia[8] · Octavia Vela[1] · Giorgios Kardaras[1] · Anton Sculean[9] · Stefan-Ioan Stratul[1]

1 Department of Periodontology, Faculty of Dental Medicine, Anton Sculean Research Center for Periodontal and Peri-Implant Diseases, Victor Babes University of Medicine and Pharmacy, , Timisoara, Romania

2 Department of Endodontics, Faculty of Dental Medicine, TADERP Research Center, Victor Babes University of Medicine and Pharmacy, Timisoara, Romania

3 Department of Periodontology, Faculty of Dental Medicine, Applicative Periodontal Regeneration Research Unit, Iuliu Hatieganu University of Medicine and Pharmacy, Cluj Napoca, Romania

4 Department of Periodontology, Faculty of Dental Medicine, University of Medicine and Pharmacy, Craiova, Romania

5 Department of Informatics and Medical Biostatistics, Victor Babes University of Medicine and Pharmacy, Timisoara, Romania

6 Department of Embryology, Faculty of Dental Medicine, Carol Davila University of Medicine and Pharmacy, Bucuresti, Romania

7 Department of Cariology, Endodontology and Periodontology, Centre for Periodontology, University Hospital of Leipzig, Leipzig, Germany

8 Department of Periodontology, School of Dental Medicine, University of Naples Federico II, Naples, Italy

9 Department of Periodontology, University of Bern, Bern, Switzerland

biomolecules

MDPI

Study Protocol

Biomolecules in Dental Applications: Randomized, Controlled Clinical Trial Evaluating the Influence of Hyaluronic Acid Adjunctive Therapy on Clinical Parameters of Moderate Periodontitis

Iwona Olszewska-Czyz [1,*], Kristina Kralik [2] and Jelena Prpic [3]

[1] Department of Periodontology and Oral Pathology, Dental Institute, Medical Faculty, Jagielonian University, 31155 Krakow, Poland
[2] Department of Medical Statistics and Medical Informatics, Medical Faculty Osijek, University Josip Juraj Strossmayer of Osijek, 31000 Osijek, Croatia; kristina.kralik@gmail.com
[3] Department of Oral Medicine and Periodontology, Faculty of Dental Medicine, University of Rijeka, 51000 Rijeka, Croatia; jelena.horvat.prpic@gmail.com
* Correspondence: iwona.olszewska-czyz@uj.edu.pl

Abstract: The biological activity of hyaluronic acid (HA) has been well-researched during the past decades; however, there are few randomized, controlled trials of its clinical effects in periodontal therapy. The purpose of this study was to evaluate the effect of hyaluronic acid on the principal parameters of periodontal healing. A specific, commercially available formulation designed and registered for professional dental application, composed of 16 mg/mL of cross-linked and 2 mg/mL of non-cross-linked HA, was used as an adjunctive to non-surgical periodontal therapy, and clinical parameters were evaluated after 3 months. The addition of HA to periodontal therapy demonstrated more favorable clinical results regarding reduction in inflammation, measured by bleeding on probing (−6% compared to the control group) and gain in periodontal attachment (1 mm more than control group), while it had no effect on probing depth reduction. No side effects were reported. Our study demonstrated that HA is a safe and easy-to-use biological agent; due to its wide array of properties, it may significantly improve the results of periodontal therapy. However, more long-term studies are needed to investigate whether these favorable effects remain over time.

Keywords: hyaluronic acid; non-surgical periodontal debridement; periodontitis

check for updates

Citation: Olszewska-Czyz, I.; Kralik, K.; Prpic, J. Biomolecules in Dental Applications: Randomized, Controlled Clinical Trial Evaluating the Influence of Hyaluronic Acid Adjunctive Therapy on Clinical Parameters of Moderate Periodontitis. *Biomolecules* **2021**, *11*, 1491. https://doi.org/10.3390/biom11101491

Academic Editor: Atsushi Saito

Received: 25 September 2021
Accepted: 7 October 2021
Published: 9 October 2021

1. Introduction

1.1. Background

Periodontitis is a chronic, inflammatory disease leading to pathological loss of tissues supporting the teeth. It has a multifactorial pathogenesis and involves complex interactions among dysbiotic plaque and destructive immune responses [1]. Epidemiological studies showed increased frequency and severity of periodontitis, which affects almost 50% of the population, with a tendency to expand with age [2]. It has also been linked to various systemic conditions such as cardiovascular disease, diabetes mellitus, rheumatoid arthritis and metabolic disease [3]. Some studies suggested that periodontitis plays a causal role in the initiation or aggravation of some of the above general disorders, most likely by stimulating an immune-inflammatory response [4]. If periodontitis is treated by professional bacterial biofilm control, it can be slowed down or stopped in most cases; however, if any factor affects either the local environment or the host response, progression of the disease and deterioration of the therapy response may occur [5]. On the other hand, some clinical studies have shown that periodontal treatment could improve other systemic conditions, for example, by better glycemic control in diabetic patients or by reducing serum inflammatory biomarkers such as C-reactive protein [3–5].

Periodontal diagnostics is currently based on clinical criteria, and the keystone of therapy is a non-surgical approach (professional plaque removal and subgingival instrumentation). Mechanical biofilm control leads to reduction in probing depths as well as clinical attachment gain. In some cases, supportive, adjunctive, local antimicrobial treatment is applied [6]. As the use of some locally administrated drugs is restricted to certain clinical situations due to their side effects, clinicians are still seeking additional therapy tools, such as dual-wavelength or photodynamic diode lasers, as well as new agents, which could be of benefit in periodontal therapy [7–10].

Hyaluronic acid (HA) is one of the local substances recently used as an addition to non-surgical periodontal treatment due to its biocompatibility, biodegradability, and properties of wound healing, rather than its antimicrobial impact [7,8,11]. HA is a biological molecule that can be found in many different tissues in the human body and is widely used in biomedicine. Studies have shown that hyaluronic acid can be found in gingivae, periodontal ligaments, cementum, alveolar bones, and in unstimulated saliva with a concentration of 148 to 1270 ng/mg protein [7,8]. It is an important component of the extracellular matrix and plays a significant role in cell migration and proliferation, which contributes to wound healing, tissue regeneration, and immunomodulation [11,12]. HA seems to be successful in the therapy of various medical problems; however, the dental application of this agent is relatively new [13–15]. As the results of some studies have suggested that HA may play bacteriostatic role [16], has the ability to interact with stem cells [17,18], and has tissue regeneration potential [7], it has been employed as a component of different products [13].

Hyaluronic acid concentration is tissue-dependent, and its properties are determined by molecular weight. In general, high-molecular-weight HA (HMW > million Da) has immunosuppressive and anti-angiogenic properties, medium-size HA (HMW form 2×10^4 to 1 million Da) influences embryogenesis, wound healing, and regeneration, and small HA molecules (HMW from 6×10^3 Da to 2×10^4 Da) contribute to pro-inflammatory, angiogenic, and gene expression effects. The majority of HA-based agents used in periodontal therapy contain high molecular weight HA [8]. It was reported that high-molecular-weight HA products do not prolong inflammation, impair the healing process, or cause excessive metalloproteinase (MMP) expression at the repair site in gingival tissue [8]. Other studies revealed that HMW hyaluronic acid increases the proliferation of human periodontal ligament (PDL) cells and maintains their high viability [18]. Hyaluronic acid in dentistry has been recently used in the treatment of mucogingival defects and residual periodontal pockets; in improving wound healing, sinus lifting, bone grafting, and socket preservation; or as a physical barrier between soft and hard tissues in procedures such as regenerative and plastic surgery, and in local therapy of various types of lesions within the oral mucosa [8,19,20]. To the best of our knowledge, there are very few studies on HA adjunctive therapy of periodontitis, and none of them were conducted on a group of moderate periodontitis cases, for which this procedure would have been the first periodontal treatment attempt. Moreover, there are few hyaluronic-acid-based products registered and tested in randomized, clinical trials for applications in periodontal procedures. Furthermore, most of the studies failed to report the exact type and molecular weight of the agents used.

Considering all of the above aspects, a hypothesis was raised of the potential influence of hyaluronic-acid-based gel (with defined molecular properties), used as a local adjunctive to non-surgical periodontal therapy, on treatment outcomes of localized, moderate periodontitis.

1.2. Objectives

The aim of the study was to evaluate the impact of hyaluronic-acid-based gel as a local delivery agent in therapy of localized moderate periodontitis, by clinical parameters' assessment. The main research objective was to investigate whether additional use of HA affects treatment outcomes, and to analyze eventual differences with the control placebo group.

1.3. Trial Design

The trial was a 3 month, single center, prospective, randomized, controlled, single-blinded clinical trial conducted at the Periodontology Department of University Dental Clinic in Cracow, Poland. The study was performed in accordance with the Declaration of Helsinki. All the participants gave informed consent to participate in the study. Official approval from the Jagiellonian University Ethics Committee was obtained (No. 122.6120.132.2015). The participants were enrolled during the periodontal appointments and the trial design follows the CONSORT guidelines (Figure 1).

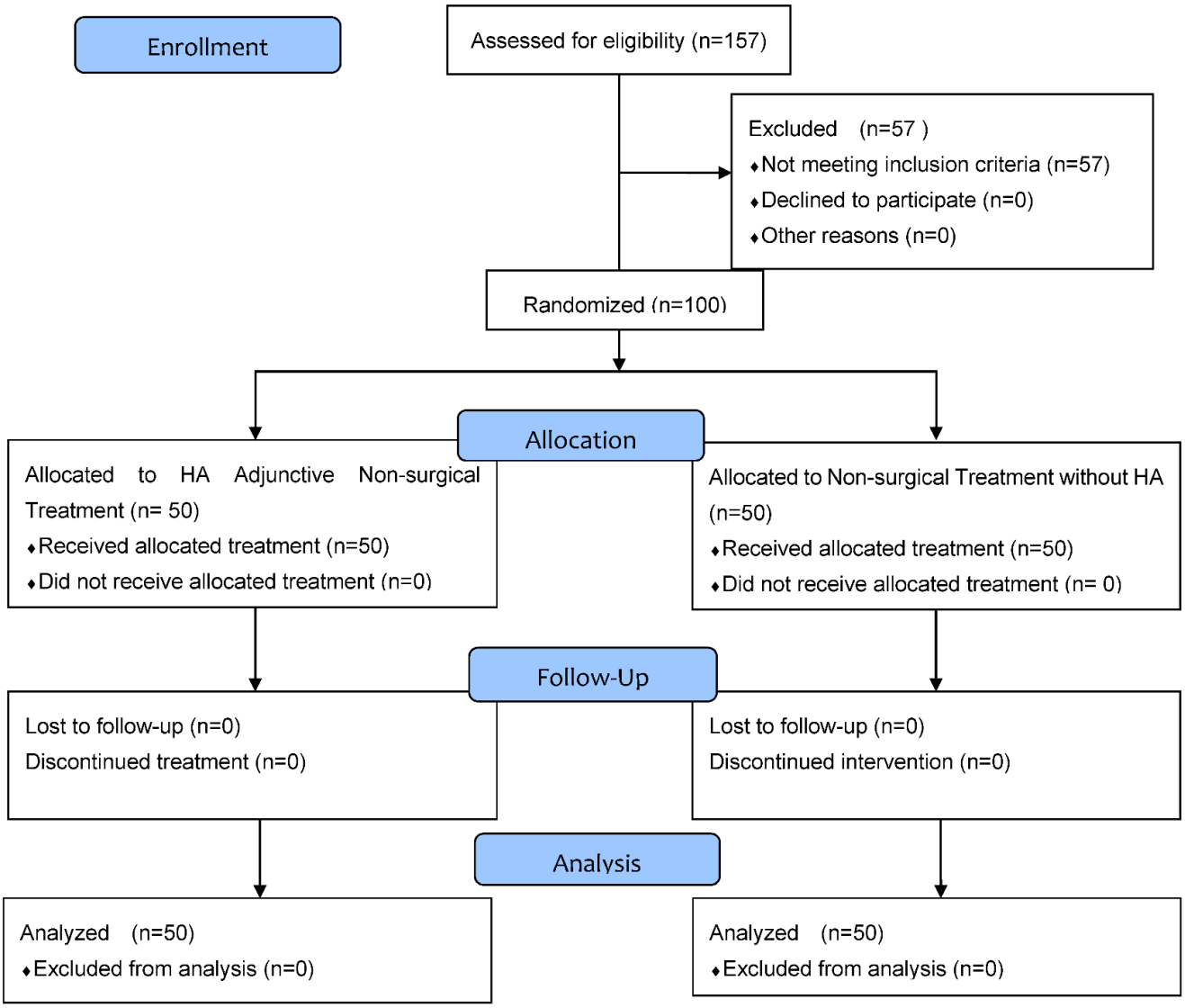

Figure 1. CONSORT 2010 flow diagram.

1.4. Randomization and Blinding

Patients enrolled in the study received code numbers. Randomizing software was used to randomly allocate patients to one of the two groups (non-surgical treatment only study group, and non-surgical treatment with adjunctive hyaluronic acid (HA) treatment control group; allocation ratio: 1:1) was used [21]. Participants were blinded to which treatment group they were assigned, as the hyaluronic acid was applied by an anesthetic syringe, whereas the non-surgical treatment alone also involved using an anesthetic syringe containing anesthetic agent.

2. Materials and Methods

2.1. Participants

One hundred, generally healthy, adult participants aged from 25 to 65 years (51% women) were enrolled in the study. The subjects were recruited from patients who had completed the first step of periodontal therapy (oral hygiene instructions and supragingival cleaning) no later than four weeks before enrollment in the study, and presented with an approximal plaque index (API) of less than 25%. To be included in the study, the patients had to demonstrate localized, moderate periodontitis with a minimum of two sites, and with a periodontal probing depth (PPD) equal or greater than 4 mm. Radiographs were used to confirm the diagnoses. A diagnosis of periodontitis was based on clinical and radiological examination, in accordance with the 2017 World Workshop on the Classification of Periodontal and Peri-Implant Disease and Conditions [22]. None of the participants had taken any antibiotics for the past 6 months, nor any non-steroidal anti-inflammatory drugs, corticosteroids, or multivitamin supplements within the 3 months prior to enrollment. They had to be nonsmokers (for a minimum of 5 years), and free from caries, epithelial dysplasia, and inflammatory lesions of the oral mucosa. Those with a history of rheumatic disorders, Sjögren disorder, enteritis, asthma, or sinusitis were also excluded from participation in the study. Pregnancy and having received periodontal treatment in the 6 months prior to the study were also added to the exclusion criteria.

2.2. Data Collection

Data were collected at baseline and after 12 weeks. Medical history, medication use, demographics, and oral hygiene routine were recorded. The periodontal clinical parameters were measured.

2.3. Clinical Parameters

A single periodontal examiner performed the following oral examination: approximal plaque index (API) [23], bleeding on probing (BoP) [24], periodontal probing depth (PPD), and clinical attachment level (CAL). The instrument used was a periodontal probe (PCP-UNC 15, Hu-Friedy, Chicago, IL, USA).

2.4. Intervention

The hyaluronic acid (HA) adjunctive treatment study group (n = 50) received non-surgical periodontal therapy, including subgingival instrumentation, followed by HA application to the existing pockets, while the control group (n = 50) received only non-surgical periodontal therapy without HA application [25]. The non-surgical instrumentation for both groups took place during one session at baseline and after six weeks, as the HA-based gel was applied to existing pockets in the study group for the second time after six weeks. All patients were followed-up after 12 weeks and, after the trial, patients were referred for either follow-up periodontal care or additional treatment, as needed. Consecutive, supportive periodontal therapy was provided.

2.5. Hyaluronic Acid Gel

The hyaluronic acid used in this clinical trial was a commercially available product, with defined composition and physical properties (Hyadent BG®, BioScience GmbH, Dummer, Germany). The gel was a mixture of 16 mg/mL cross-linked HA and 2 mg/mL non-cross-linked HA; the average molecular weight of the cross-linked HA as well as for the non-cross-linked HA was 1 million Dalton. The HA in this product was obtained by bacterial fermentation using *Streptococcus zooepidermicus*. The cross-linking process, using BDDE (1,4-butanediol diglycidyl ether), was performed in an alkaline pH, which resulted in formation of ether bonds. The degree of cross-linking was in the range of 0% to 20%.

2.6. Safety Monitoring

Oral symptoms were recorded at baseline, after six weeks and after twelve weeks. During the follow-up examination, the patients were asked if they had experienced any diverse events.

2.7. Statistical Methods

Categorical data are presented in absolute and relative frequencies. The differences between categorical variables were tested by the Fisher exact test. Normality of distribution for numerical variables was tested by using the Shapiro–Wilk test. Since the distribution was not normal, nonparametric tests were used, and numerical data are presented with both median and limits of interquartile range. Differences in numerical variables between independent groups were tested by the Mann–Whitney U test, with a 95% confidence interval (CI). Differences in values of continuous variables before and after applied therapy were tested by the Wilcoxon test. Correlation assessment was presented through the Spearman coefficient of correlation. Level of significance was set to alpha = 0.5. In order to obtain the effect size of 0.5 for the determination of the difference in numerical variables between the two measurements, with the level of significance set to 0.05 and the power set to 0.9, the calculated minimum required sample size was 44 subjects per group. Statistical analysis was performed with MedCalc® Statistical Software version 19.6 (MedCalc Software Ltd., Ostend, Belgium (https://www.medcalc.org; accessed on 9 May 2020) and SPSS (IBM Corp. Released 2013. IBM SPSS, Ver. 21.0. Armonk, NY, USA).

3. Results

3.1. Adverse Events

No cases requiring rescue therapy were reported.

3.2. Results

The median age of study participants was 51 years in the control group and 52 years in the HA study group. There were slightly higher values of periodontal probing depths (PPD) in the HA study group before treatment, whereas no significant differences were observed for other parameters (medium PPD 4.2 mm in control group vs. 4.75 mm in the study group, $p = 0.001$). Table 1 presents differences between the clinical parameters of the groups at baseline and after therapy was completed. Statistically significant differences were observed between the two groups for BoP and CAL in favor of the HA study group, but no differences were found for PPD.

In both groups, the observed differences between the parameters tested before and after designated treatment were significant, and revealed the reduction in BoP, CAL, and PPD in both treatment groups (Table 2, Figures A1–A3). However, when the absolute differences between the two treatment protocols regarding reduction in BoP, CAL, and PPD were tested, it was found that all three parameters were significantly more reduced in the HA group (Table 3).

The effects of specific predictors on the variability in BoP, CAL, and PPD were analyzed by a multivariate regression analysis (stepwise method). No significant predictors were found for CAL or PPD values after treatment for either group. However, in the group of patients receiving therapy without the addition of HA, fewer male participants demonstrated bleeding on probing after treatment compared to their female counterparts (19% vs. 23%, respectively). This was statistically significant at $p = 0.04$, R^2adj = 0.588. Regarding the patients' ages, no significant differences were observed, except for the tendency of older participants toward greater PPD values before treatment (Spearman coefficient of correlation ($p = 0.03$).

Table 1. Clinical parameters before and after therapy in the study and control groups.

	Control Group	Study HA Group	Difference † (95% CI)	*p* *
Before therapy				
BoP (%)	31 (22.8–40.3)	33.5 (23.8–42)	0 (−4 to 5)	0.79
CAL (mm)	4 (3–4)	4 (3.5–4)	0 (0–0)	0.90
PPD (mm)	4.25 (4–4.5)	4.75 (4.4–5)	0.25 (0–0.5)	0.001
After therapy				
BoP (%)	20.5 (15–25)	13 (9.5–18.25)	−6 (−10 to −3)	<0.001
CAL (mm)	3 (2–3)	1.63 (1–2)	−1 (−1.25 to −1)	<0.001
PPD (mm)	3.5 (2.8–3.8)	3.5 (2.75–3.75)	0 (−0.25 to 0.25)	0.70

HA—hyaluronic acid; 95% CI—95% confidence interval; * Mann–Whitney U test; † Hodges–Lehmanov median difference.

Table 2. Clinical parameters before and after treatment, within each treatment group.

	Median (Interquartile Range)		Difference † (95% CI)	*p* *
	before Treatment	after Treatment		
Control Group				
BoP (%)	31 (22.8–40.3)	20.5 (15–25)	−12 (−14 to −9.5)	<0.001
CAL (mm)	4 (3–4)	3 (2–3)	−1 (−1.13 to −1)	<0.001
PPD (mm)	4.25 (4–4.5)	3.5 (2.8–3.8)	−1 (−1.13 to −0.88)	<0.001
Study HA Group				
BoP (%)	33.5 (23.8–42)	13 (9.5–18.25)	−18 (−21 to −14.5)	<0.001
CAL (mm)	4 (3.5–4)	1.63 (1–2)	−2.25 (−2.5 to −2)	<0.001
PPD (mm)	4.75 (4.4–5)	3.5 (2.75–3.75)	−1.5 (−1.63 to −1.25)	<0.001

HA—hyaluronic acid; 95% CI—95% confidence interval; * Wilcoxon test; † Hodges–Lehman median difference.

Table 3. Absolute differences before and after therapy between groups.

	Median (Interquartile Range) of Difference before–after Therapy		Difference † (95% CI)	*p* *
	Control Group	Study HA Group		
BoP (%)	−11.5 (−18 to −6)	−17 (−26 to −10)	−6 (−10 to −2)	0.003
CAL (mm)	−1 (−1.25 to −0.5)	−2 (−3 to −2)	−1 (−1.5 to −1)	<0.001
PPD (mm)	−1 (−1.25 to −0.75)	−1.5 (−1.75 to −1)	−0.5 (−0.5 to −0.25)	<0.001

95% CI—95% Confidence interval; * Mann–Whitney U test; † Hodges–Lehmann median difference.

4. Discussion

Non-surgical periodontal therapy is, in the majority of cases, efficacious, and leads to significant improvements in clinical outcomes; however, in some cases, it fails to halt the disease process, which continues to persist. Van Dyke [26] and Salvi and Lang [27] suggest that "resolution of established inflammation takes longer to subside, or may even fail to do so when the inflammation has become chronic, therefore administration of pharmacological or bioactive agents as adjuncts may facilitate resolution or inhibit inflammation". Commonly used adjuncts in periodontal therapy come in the form of disinfectants (such as chlorhexidine, boric acid, and povidone–iodine), low-level laser therapy, herbal medicine, probiotics, host modulators such as statins, bisphosphonate and metformin gels, antibiotics administered either locally or systemically, and even orthodontic therapy. This list would be incomplete without the most natural of them all: hyaluronic acid.

In the field of dentistry, hyaluronic acid was first used in preliminary clinical trials by Pagnacco and Vangelisti in 1997 [28]. In subsequent trials, this biological macromolecule was found to have clinically proven anti-inflammatory, anti-edematous, anti-bacterial, and pro-angiogenetic properties [29], while some authors also discussed its significant antioxidant capacity, achieved through scavenging of reactive oxidative species, called ROS [30,31]. There are numerous, relevant, published studies and a few meta-analyses that demonstrated positive results in patients with gingivitis, chronic periodontitis, implant, and sinus-lift procedures, as well as oral ulcer treatment [31]. Unfortunately, there are very few hyaluronic-acid-based products that have been registered and tested in randomized clinical trials for applications in non-surgical periodontal therapy and surgical therapy; furthermore, there are some investigations that failed to report the exact product used, making it impossible to determine the type and molecular weight of hyaluronic acid. In this trial, a well-researched product with defined molecular properties and established on the global market was used, with previously proven pre-clinical [32,33] and clinical effects [34,35]. This product is also widely available and proven to be safe for both non-surgical and surgical applications in dentistry.

In this single-center, randomized, controlled study, a total of 100 periodontitis patients divided into two groups (experimental and control) were treated with non-surgical periodontal therapy, according to the EFP guidelines, and followed-up for 3 months. According to the recommendations for evaluation of the results obtained by non-surgical periodontal therapy, this follow-up period is deemed as adequate [29]. One of the groups received an adjunct to scaling and root planning (SRP) in the form of hyaluronic acid gel, and the results were evaluated clinically. Clinical parameters (BoP, PPD, and CAL) showed statistically significant improvements at three months after treatment in both groups, proving the efficacy of the SRP concept. However, the experimental group, which also received HA gel applied directly into the periodontal pockets, showed a significantly lower percentage of sites with bleeding on probing (BoP), a marker of inflammation, as well as lower clinical attachment loss (CAL), which is indicative of periodontal reparation and regeneration; furthermore, the group receiving the HA gel showed significantly greater reduction in all three parameters when absolute differences were tested before and after therapy. As for the values of probing depth (PPD), even though PPD values were significantly more reduced in the HA group, no statistically significant differences were demonstrated for the median PPD value after therapy. This may be explained by the difference in median PPD values at baseline, where the experimental group (the one receiving the adjunctive HA therapy) had significantly higher PPD values. Both study groups at follow-up had a median value of 3.5 mm, which, according to the most recent EFP and American Academy of Periodontology guidelines, correlates with Stage I of periodontitis, which marks the minimum severity of the disease. However, it should be noted that the CAL value is preferred in clinical trials as the primary outcome measure over PPD, since it represents a more objective measure of periodontitis progression and activity [36].

Hereby, the presented results are in line with most similar trials, which demonstrated a favorable effect of HA as an adjunct to non-surgical periodontal treatment. Many of these trials aimed at treatment of gingivitis, which does not present with the loss of clinical attachment [37,38]. One recently published meta-analysis found a total of 11 RCTs evaluating the effect of this biological macromolecule on healing after its use in treatment [29]; however, only five of them met the selected inclusion criteria and included the measures of BoP, CAL, and PPD. The calculated weighed mean differences for BoP, PPD, and CAL before and after therapy were all in favor of the HA treatment protocol, which is in line with the results obtained in this investigation. Interestingly, one of the RCTs included in the above-mentioned meta-analysis found no differences in terms of BoP, CAL, or PPD values between the control and experimental groups; however, the sulcus fluid flow rate had reduced to physiological levels faster in the HA group [39]. One of the trials did not use any of the commercially available HA gels used nowadays, but a mix of amino acids and sodium hyaluronate gel of unknown molecular weight and concentration [40]. Of the remaining three RCTs, Eick et al. showed greater PPD reduction compared to our results [41], as well as Johannsen et al., who found almost no CAL gain after 12 weeks [42]; finally, Wan, in his thesis, only found significant differences in terms of BoP, and not for PPD or CAL [43].

It can be deduced from the available scientific evidence that the addition of hyaluronic acid to standard, non-surgical, periodontal therapy definitely has some positive biological effects. One of the recently published in vitro studies demonstrated that HA increased the expression of genes encoding type III collagen and transforming growth factor-β3, and subsequently enhanced pro-proliferative, pro-migratory, and pro-inflammatory factors in fibroblasts [44]. In addition to its bacteriostatic effect, it seems obvious that this biological macromolecule is one of the more promising adjuncts to regenerative therapy and is definitely here to stay.

Even though this investigation demonstrated a significant beneficial effect of hyaluronic acid on periodontal healing and reduction in inflammation after the non-surgical periodontal therapy, we were not able to establish whether this remained true in the long run. The patients were followed-up for three months, and it would be very interesting to observe the long-term clinical effects after six- or even twelve-month intervals. Another limitation of this study is the observed difference in median PPD values between the two groups at baseline—the HA group had deeper periodontal pockets. However, by calculating the absolute difference between the groups before and after therapy, we were able to demonstrate that addition of HA significantly improved all parameters used as measures of periodontal disease activity.

It may also be argued that a split-mouth protocol would have greater strength, since it could eliminate the cross-over effects related to parallel groups. However, in our opinion, application of hyaluronic acid on one side of the mouth inevitably leads to even its slight spread among other oral tissues, since it is carried away and spread by saliva; another observation related to the study design is that even split-mouth trials, such as the one by Rajan et al. [45], found the same beneficial effects of hyaluronic acid, such as the ones presented in this paper. Therefore, it seems that both study designs are valid. The future guidelines on adjuncts to periodontal therapy, which may eventually be drafted by relevant institutions and associations, should have the scope of defining the make-up and exact concentrations of hyaluronic acid gels designated for use in the oral cavity, specifically in periodontology. Only then we will be able to grasp the entire array of effects demonstrated by this quite fascinating biological macromolecule.

5. Conclusions

Within the limits, the hereby presented data from the randomized controlled trial indicated that the addition of hyaluronic acid to periodontal pockets immediately upon completion of the initial (non-surgical) periodontal therapy leads to significant clinical benefits. Those benefits manifest predominantly through a greater gain in clinical attachment

and reduced bleeding on probing, both of which are indicative of reduced inflammation and periodontal regeneration. Hyaluronic acid is an easy-to-handle, safe, biocompatible, non-allergenic, naturally occurring macromolecule with promising clinical effects. However, further long-term studies (of six, twelve, or even more months), possibly with repeated applications of HA at different time intervals, are needed to investigate whether these favorable effects remain over time.

Author Contributions: I.O.-C., conceptualization, methodology, validation, investigation, resources, data curation, writing—original draft, writing—review and editing, project administration, and funding acquisition; K.K., software, validation, formal analysis, and visualization; J.P., validation, resources, writing—original draft, writing—review and editing, and supervision. All authors have read and agreed to the published version of the manuscript.

Funding: This work was supported by statutory grant from Jagiellonian University Medical College (No. K/ZDS/005516).

Institutional Review Board Statement: The study was performed in accordance with the Declaration of Helsinki. All the participants gave informed consent to participate in the study. Official approval from the Jagiellonian University Ethics Committee was obtained (No. 122.6120.132.2015).

Informed Consent Statement: Informed consent was obtained from all subjects involved in the study. Written informed consent has been obtained from the patients to publish this paper.

Data Availability Statement: The data presented in this study are available on request from the corresponding author. The data are not publicly available due to ethical restrictions.

Conflicts of Interest: The authors declare no conflict of interest.

Appendix A

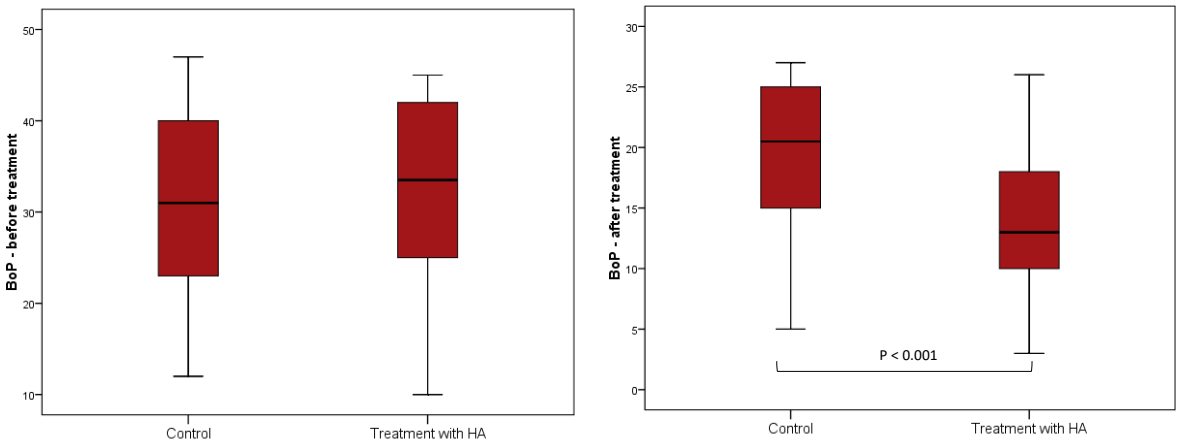

Figure A1. BoP values before (**left**) and after (**right**) treatment in the groups.

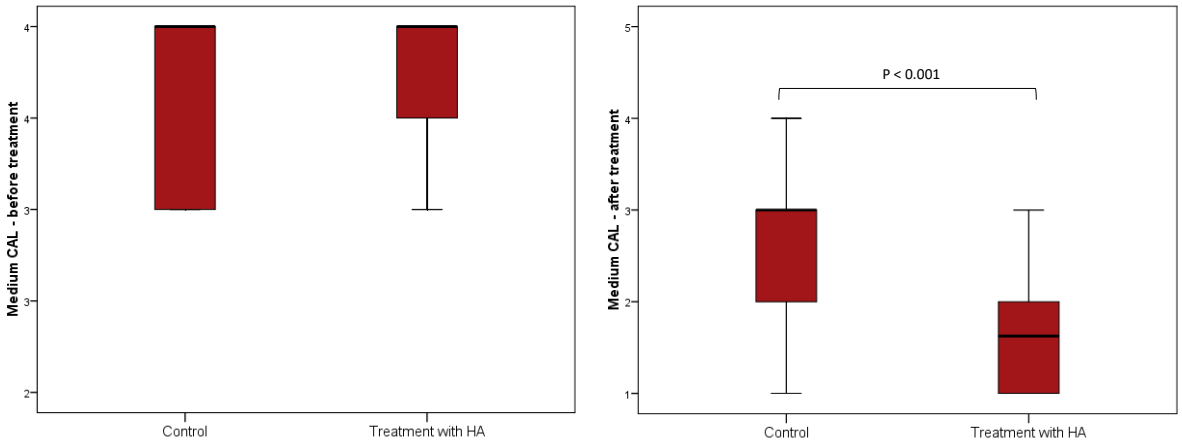

Figure A2. CAL values before (**left**) and after (**right**) treatment in the groups.

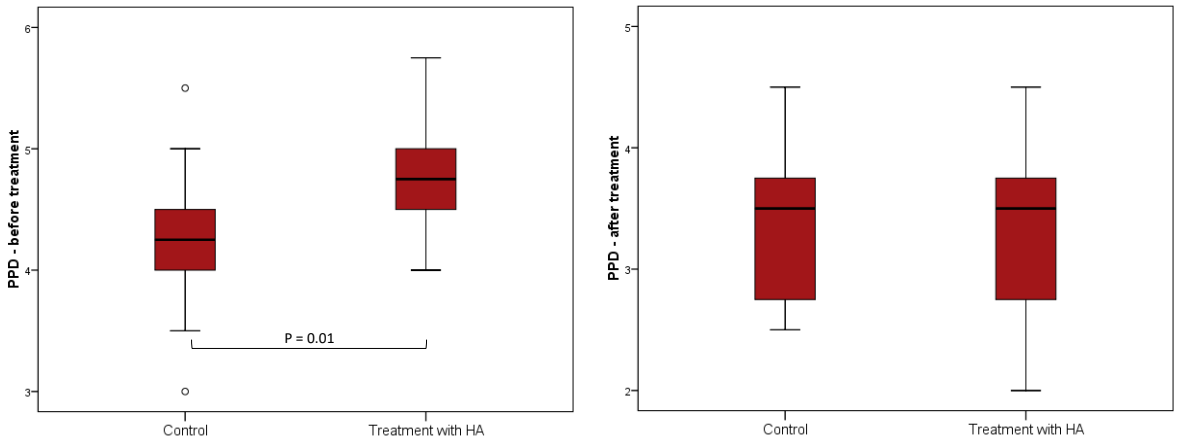

Figure A3. PPD values before (**left**) and after (**right**) treatment in the groups.

References

1. Papapanou, P.N.; Sanz, M.; Buduneli, N.; Dietrich, T.; Feres, M.; Fine, D.H.; Flemmig, T.F.; Garcia, R.; Giannobile, W.V.; Graziani, F.; et al. Periodontitis: Consensus report of workgroup 2 of the 2017 World Workshop on the Classification of Periodontal and Peri-Implant Diseases and Conditions. *J. Clin. Periodontol.* **2018**, *45*, S162–S170. [CrossRef]
2. Monsarrat, P.; Vergnes, J.-N.; Cantagrel, A.; Algans, N.; Cousty, S.; Kemoun, P.; Bertrand, C.; Arrive, E.; Bou, C.; Sedarat, C.; et al. Effect of periodontal treatment on the clinical parameters of patients with rheumatoid arthritis: Study protocol of the randomized, controlled ESPERA trial. *Trials* **2013**, *14*, 253. [CrossRef] [PubMed]
3. Beck, J.; Papapanou, P.N.; Philips, K.; Offenbacher, S. Periodontal Medicine: 100 Years of Progress. *J. Dent. Res.* **2019**, *98*, 1053–1062. [CrossRef] [PubMed]
4. Kumar, P.S. From focal sepsis to periodontal medicine: A century of exploring the role of the oral microbiome in systemic disease. *J. Physiol.* **2016**, *595*, 465–476. [CrossRef] [PubMed]
5. Shaddox, L.M.; Walker, C.B. Treating chronic periodontitis: Current status, challenges, and future directions. *Clin. Cosmet. Investig. Dent.* **2010**, *2*, 79–91. [CrossRef] [PubMed]
6. Slots, J. Periodontitis: Facts, fallacies and the future. *Periodontology* **2017**, *75*, 7–23. [CrossRef]
7. Zhai, P.; Peng, X.; Li, B.; Liu, Y.; Sun, H.; Li, X. The application of hyaluronic acid in bone regeneration. *Int. J. Biol. Macromol.* **2020**, *151*, 1224–1239. [CrossRef]
8. Al-Khateeb, R.; Olszewska-Czyz, I. Biological molecules in dental applications: Hyaluronic acid as a companion biomaterial for diverse dental applications. *Heliyon* **2020**, *6*, e03722. [CrossRef]
9. De Angelis, N.; Hanna, R.; Signore, A.; Amaroli Benedicenti, S. Effectiveness of dual-wavelength (Diodes 980 Nm and 635 Nm) laser approach as a non-surgical modality in the management of periodontally diseased root surface: A pilot study. *Biotechnol. Biotechnol. Equip.* **2018**, *32*, 1575–1582. [CrossRef]
10. Amaroli, A.; Barbieri, R.; Signore, A.; Marchese, A.; Parker, S.; De Angelis, N.; Benedicenti, S. Simultaneous photoablative and photodynamic 810-nm diode laser therapy as an adjunct to non-surgical periodontal treatment: An in-vitro study. *Minerva Stomatol.* **2020**, *69*, 1–7. [CrossRef]

11. Bazmandeh, A.Z.; Mirzaei, E.; Fadaie, M.; Shirian, S.; Ghasemi, Y. Dual spinneret electrospun nanofibrous/gel structure of chitosan-gelatin/chitosan-hyaluronic acid as a wound dressing: In-vitro and in-vivo studies. *Int. J. Biol. Macromol.* **2020**, *162*, 359–373. [CrossRef]
12. Sukumar, S.; Drízhal, I. Hyaluronic Acid and Periodontitis. *Acta Med.* **2007**, *50*, 225–228. [CrossRef]
13. Bukhari, S.N.A.; Roswandi, N.L.; Waqas, M.; Habib, H.; Hussain, F.; Khan, S.; Sohail, M.; Ramli, N.A.; Thu, H.E.; Hussain, Z. Hyaluronic acid, a promising skin rejuvenating biomedicine: A review of recent updates and pre-clinical and clinical investigations on cosmetic and nutricosmetic effects. *Int. J. Biol. Macromol.* **2018**, *120*, 1682–1695. [CrossRef]
14. Bao, Z.; Yu, A.; Shi, H.; Hu, Y.; Jin, B.; Lin, D.; Dai, M.; Lei, L.; Li, X.; Wang, Y. Glycol chitosan/oxidized hyaluronic acid hydrogel film for topical ocular delivery of dexamethasone and levofloxacin. *Int. J. Biol. Macromol.* **2021**, *167*, 659–666. [CrossRef]
15. Cardoso, J.F.; Perasoli, F.B.; Almeida, T.C.; Marques, M.B.D.F.; Toledo, C.R.; Gil, P.O.; Tavares, H.D.S.; Da Paz, M.C.; Mussel, W.D.N.; Magalhães, J.T.; et al. Vancomycin-loaded N,N-dodecyl, methyl-polyethylenimine nanoparticles coated with hyaluronic acid to treat bacterial endophthalmitis: Development, characterization, and ocular biocompatibility. *Int. J. Biol. Macromol.* **2021**, *169*, 330–341. [CrossRef]
16. Pirnazar, P.; Wolinsky, L.; Nachnani, S.; Haake, S.; Pilloni, A.; Bernard, G.W. Bacteriostatic Effects of Hyaluronic Acid. *J. Periodontol.* **1999**, *70*, 370–374. [CrossRef] [PubMed]
17. Agarwal, G.; Agiwal, S.; Srivastava, A. Hyaluronic acid containing scaffolds ameliorate stem cell function for tissue repair and regeneration. *Int. J. Biol. Macromol.* **2020**, *165*, 388–401. [CrossRef] [PubMed]
18. Dahiya, P.; Kamal, R. Hyaluronic Acid: A boon in periodontal therapy. *N. Am. J. Med. Sci.* **2013**, *5*, 309–315. [CrossRef] [PubMed]
19. Pilloni, A.; Zeza, B.; Kuis, D.; Vrazic, D.; Domic, T.; Olszewska-Czyz, I.; Popova, C.; Kotsilkov, K.; Firkova, E.; Dermendzieva, Y.; et al. Treatment of Residual Periodontal Pockets Using a Hyaluronic Acid-Based Gel: A 12 Month Multicenter Randomized Triple-Blinded Clinical Trial. *Antibiotics* **2021**, *10*, 924. [CrossRef]
20. Casale, M.; Moffa, A.; Vella, P.; Sabatino, L.; Capuano, F.; Salvinelli, B.; Lopez, M.A.; Carinci, F.; Salvinelli, F. Hyaluronic acid: Perspectives in dentistry. A systematic review. *Int. J. Immunopathol. Pharmacol.* **2016**, *29*, 572–582. [CrossRef]
21. Urbaniak, G.C.; Plous, S. Research Randomizer (Version 4.0). Available online: http://www.randomizer.org/ (accessed on 9 October 2020).
22. Tonetti, M.S.; Sanz, M. Implementation of the new classification of periodontal diseases: Decision-making algorithms for clinical practice and education. *J. Clin. Periodontol.* **2019**, *46*, 398–405. [CrossRef]
23. Lange, D.E.; Plagmann, H.C.; Eenboom, A.; Promesberger, A. Klinische Bewertungsverahren zur Objektivierung der Mundhygiene [Clinical methods for the objective evaluation of oral hygiene]. *Dtsch Zahnarztl Z.* **1977**, *32*, 44–47.
24. Ainamo, J.; Bay, I. Problems and proposals for recording gingivitis and plaque. *Int. Dent. J.* **1975**, *25*, 229–235. [PubMed]
25. Sanz, M.; Herrera, D.; Kebschull, M.; Chapple, I.; Jepsen, S.; Berglundh, T.; Sculean, A.; Tonetti, M.S.; Aass, A.M.; Aimetti, M.; et al. Treatment of stage I–III periodontitis—The EFP S3 level clinical practice guideline. *J. Clin. Periodontol.* **2020**, *47*, 4–60. [CrossRef] [PubMed]
26. Van Dyke, T.E. Pro-resolving mediators in the regulation of periodontal disease. *Mol. Asp. Med.* **2017**, *58*, 21–36. [CrossRef]
27. Salvi, G.E.; Lang, N.P. The Effects of Non-Steroidal Anti-Inflammatory Drugs (Selective and Non-Selective) on the Treatment of Periodontal Diseases. *Curr. Pharm. Des.* **2005**, *11*, 1757–1769. [CrossRef]
28. Pagnacco, A.; Vangelisti, R.; Erra, C.; Poma, A. Double-blind clinical trial versus placebo of a new sodium-hyaluronate-based gingival gel. *Attual. Ter. Internazionale* **1997**, *15*, 1–7.
29. Eliezer, M.; Imber, J.-C.; Sculean, A.; Pandis, N.; Teich, S. Hyaluronic acid as adjunctive to non-surgical and surgical periodontal therapy: A systematic review and meta-analysis. *Clin. Oral Investig.* **2019**, *23*, 3423–3435. [CrossRef]
30. Waddington, R.J.; Moseley, R.; Embery, G. Periodontal Disease Mechanisms: Reactive oxygen species: A potential role in the pathogenesis of periodontal diseases. *Oral Dis.* **2008**, *6*, 138–151. [CrossRef] [PubMed]
31. Balogh, G.T.; Illés, J.; Székely, Z.; Forrai, E.; Gere, A. Effect of different metal ions on the oxidative damage and antioxidant capacity of hyaluronic acid. *Arch. Biochem. Biophys.* **2003**, *410*, 76–82. [CrossRef]
32. Fujioka-Kobayashi, M.; Schaller, B.; Kobayashi, E.; Hernandez, M.; Zhang, Y.; Miron, R.J. Hyaluronic Acid Gel-Based Scaffolds as Potential Carrier for Growth Factors: An In Vitro Bioassay on Its Osteogenic Potential. *J. Clin. Med.* **2016**, *5*, 112. [CrossRef]
33. Fujioka-Kobayashi, M.; Müller, H.-D.; Mueller, A.; Lussi, A.; Sculean, A.; Schmidlin, P.R.; Miron, R.J. In vitro effects of hyaluronic acid on human periodontal ligament cells. *BMC Oral Health* **2017**, *17*, 1–12. [CrossRef]
34. Pilloni, A.; Schmidlin, P.R.; Sahrmann, P.; Sculean, A.; Rojas, M.A. Effectiveness of adjunctive hyaluronic acid application in coronally advanced flap in Miller class I single gingival recession sites: A randomized controlled clinical trial. *Clin. Oral Investig.* **2018**, *23*, 1133–1141. [CrossRef] [PubMed]
35. Awartani, F.A.; Tatakis, D.N. Interdental papilla loss: Treatment by hyaluronic acid gel injection: A case series. *Clin. Oral Investig.* **2015**, *20*, 1775–1780. [CrossRef] [PubMed]
36. Mdala, I.; Olsen, I.; Haffajee, A.D.; Socransky, S.S.; Thoresen, M.; De Blasio, B.F. Comparing clinical attachment level and pocket depth for predicting periodontal disease progression in healthy sites of patients with chronic periodontitis using multi-state M arkov models. *J. Clin. Periodontol.* **2014**, *41*, 837–845. [CrossRef] [PubMed]
37. Jentsch, H.; Pomowski, R.; Kundt, G.; Göcke, R. Treatment of gingivitis with hyaluronan. *J. Clin. Periodontol.* **2003**, *30*, 159–164. [CrossRef]

38. Pistorius, A.; Martin, M.; Willershausen, B.; Rockmann, P. The clinical application of hyaluronic acid in gingivitis therapy. *Quintessence Int.* **2005**, *36*, 531–538.
39. Xu, Y.; Höfling, K.; Fimmers, R.; Frentzen, M.; Jervøe-Storm, P.M. Clinical and Microbiological Effects of Topical Subgingival Application of Hyaluronic Acid Gel Adjunctive to Scaling and Root Planing in the Treatment of Chronic Periodontitis. *J. Periodontol.* **2004**, *75*, 1114–1118. [CrossRef]
40. Bevilacqua, L.; Eriani, J.; Serroni, I.; Liani, G.; Borelli, V.; Castronovo, G.; Di Lenarda, R. Effectiveness of adjunctive subgingival administration of amino acids and sodium hyaluronate gel on clinical and immunological parameters in the treatment of chronic periodontitis. *Ann. Stomatol.* **2012**, *3*, 75–81.
41. Eick, S.; Renatus, A.; Heinicke, M.; Pfister, W.; Stratul, S.-I.; Jentsch, H. Hyaluronic Acid as an Adjunct After Scaling and Root Planing: A Prospective Randomized Clinical Trial. *J. Periodontol.* **2013**, *84*, 941–949. [CrossRef]
42. Johannsen, A.; Tellefsen, M.; Wikesjö, U.; Johannsen, G. Local Delivery of Hyaluronan as an Adjunct to Scaling and Root Planing in the Treatment of Chronic Periodontitis. *J. Periodontol.* **2009**, *80*, 1493–1497. [CrossRef] [PubMed]
43. Wan, P. *A Clinical Trial of Local Delivery of Hyaluronic Acid Gel as an Adjunct to Non-Surgical Treatment of Chronic Peri-Odontitis*; The University of Hong Kong: Hong Kong, China, 2004.
44. Asparuhova, M.B.; Kiryak, D.; Eliezer, M.; Mihov, D.; Sculean, A. Activity of two hyaluronan preparations on primary human oral fibroblasts. *J. Periodontal Res.* **2018**, *54*, 33–45. [CrossRef] [PubMed]
45. Rajan, P.; Baramappa, R.; Rao, N.M.; Pavaluri, A.K. Hyaluronic Acid as an Adjunct to Scaling and Root Planing in Chronic Periodontitis. A Randomized Clinical Trail. *J. Clin. Diagn. Res.* **2014**, *8*, ZC11–ZC14. [CrossRef] [PubMed]

Clinical Oral Investigations (2021) 25:5331–5340
https://doi.org/10.1007/s00784-021-03841-8

ORIGINAL ARTICLE

Changes in clinical parameters following adjunctive local sodium hypochlorite gel in minimally invasive nonsurgical therapy (MINST) of periodontal pockets: a 6-month randomized controlled clinical trial

Vincenzo Iorio-Siciliano[1] · Luca Ramaglia[1] · Gaetano Isola[2,3] · Andrea Blasi[1] · Giovanni E. Salvi[4] · Anton Sculean[4]

Received: 7 October 2020 / Accepted: 16 February 2021 / Published online: 9 March 2021

Abstract

Background The mechanical disruption and removal of the subgingival biofilm represent the most important step in the treatment of periodontitis. However, in deep periodontal pockets, mechanical removal of the subgingival biofilm is difficult and frequently incomplete. Preliminary findings indicate that the use of amino acid buffered sodium hypochlorite (NaOCl) gel may chemically destroy the bacterial biofilm and facilitate its mechanical removal.

Objectives To clinically evaluate the efficacy of minimally invasive nonsurgical therapy (MINST) of periodontal pockets with or without local application of an amino acid buffered sodium hypochlorite (NaOCl) gel.

Materials and methods Forty untreated patients diagnosed with severe/advanced periodontitis (i.e. stage III/IV) with a slow/moderate rate of progression (i.e. grade A/B) were randomly allocated in two treatment groups. In the test group, the periodontal pockets were treated by means of MINST and NaOCl gel application, while in the control group, treatment consisted of MINST alone. Full-mouth plaque scores (FMPS), full-mouth bleeding scores (FMBS), probing depths (PD), clinical attachment levels (CAL) and gingival recessions (GR) were assessed at baseline and at 6 months following therapy. The primary outcome variable was PD reduction at sites with PD ≥ 5 mm at baseline.

Results At 6 months, statistically significant differences between the two groups were found ($p = 0.001$) in terms of PD and CAL change. No statistically significant differences were found in terms of GR ($p = 0.81$). The number of sites with PD ≥ 5 mm and BOP (+) decreased statistically significantly ($p = 0.001$), i.e. from 85.3 to 2.2% in the test group and from 81.6 to 7.3% in the control group, respectively. Statistically significant differences between test and control groups were recorded at 6 months ($p = 0.001$). MINST + NaOCl compared to MINST alone decreased statistically significantly ($p = 0.001$) the probability of residual PDs ≥ 5 mm with BOP− (14.5% vs 18.3%) and BOP+ (2.2% vs. 7.2%).

Conclusions Within their limits, the present results indicate that (a) the use of MINST may represent a clinically valuable approach for nonsurgical therapy and (b) the application of NaOCl gel in conjunction with MINST may additionally improve the clinical outcomes compared to the use of MINST alone.

Clinical relevance In patients with untreated periodontitis, treatment of deep pockets by means of MINST in conjunction with a NaOCl gel may represent a valuable approach to additionally improve the clinical outcomes obtained with MINST alone

✉ Vincenzo Iorio-Siciliano
enzois@libero.it

[1] Department of Periodontology, School of Dental Medicine, University of Naples Federico II, Via S. Pansini 5, 80131 Naples, Italy

[2] Department of Biomedical, Odontostomatological Sciences and of Morphological and Functional Immages, School of Dentistry, University of Messina, AOU Policlinico "G.Martino", Via C.Valeria 1, 98125 Messina, Italy

[3] Department of General Surgery and Surgical-Medical Specialities, School of Dentistry University of Catania, Via Sofia 78, 95125 Catania, Italy

[4] Department of Periodontology, School of Dental Medicine, University of Bern, Freiburgstrasse 7, CH-3010 Bern, Switzerland

Keywords Periodontitis · Periodontal pockets · Hypochlorite · Biofilm · Bleeding on probing · Nonsurgical periodontal debridement

Introduction

The development and progression of periodontitis depend on the presence of pathogenic microorganisms organized in a supra/subgingival biofilm attached to the dental surface [1, 2]. The main goal of nonsurgical periodontal therapy is to eliminate the periodontal pathogenic biofilm from the tooth surfaces and from the periodontal pockets to reduce probing pocket depths and inflammation (i.e. bleeding on probing), ultimately arresting periodontal disease progression [2, 3]. Today, it is generally accepted that mechanical disruption and removal of the subgingival biofilm using hand and ultrasonic/sonic instruments represent the most important step in the treatment of periodontitis leading, in the great majority of cases, to successful clinical outcomes [2–4]. However, in certain clinical situations, such as the presence of deep periodontal pockets or deep furcation involvements, mechanical removal of the subgingival biofilm is difficult and frequently incomplete [5].

In the last years, the use of mini- and micro-instruments in combination with magnification loupes was suggested to more accurately eliminate the biofilm from deep periodontal pockets [6–8]. Clinical, microbiological and histologic findings appear to indicate that minimally invasive nonsurgical periodontal therapy may be a valuable option for the treatment of deep periodontal pockets [6–8].

Additionally, in the last decades, a number of novel strategies encompassing the use of locally delivered antiseptic and/or anti-inflammatory agents, antibiotics or photodynamic therapy, have been tested to enable a more accurate disruption and removal of the subgingival biofilm and to additionally improve the clinical outcomes and reduce the need for surgery [2, 9–11].

NaOCl has been suggested as a potential agent for the treatment of gingivitis [12] and, later, in the form of irrigation combined with mechanical debridement for the treatment of periodontitis [13].

Recently, a novel formulation consisting of NaOCl 0.95% and amino acids (glutamic acid, leucine, lysine) gel has been introduced to detoxify the root surfaces, to soften the calculus thus facilitating its removal by means of root planing [14, 15].

Findings from an "in vitro" study have shown that this novel NaOCl formulation acts have an antimicrobial effect, in particular against Gram-negative species associated with periodontitis, thus pointing to its potential use as an adjunctive topical antimicrobial in the treatment of periodontitis [14]. Subsequent findings from "in vitro" studies have shown that the application of the amino acid buffered hypochlorite solution had a positive effect on the survival, attachment and spreading of periodontal ligament cells onto root surfaces [15].

However, at present, the data on the potential clinical relevance of a local application of NaOCl used in conjunction with subgingival mechanical instrumentation is still limited [13, 16].

More recently, a novel protocol termed minimally invasive nonsurgical therapy (MINST) has been proposed for the treatment of isolated deep pockets associated with intrabony defects [17, 18]. Treatment of deep periodontal pockets by means of MINST consists of careful scaling and root planing using ultrasonic devices with delicate tips, mini-curettes and operating microscope under local anaesthesia [17, 18]. In a first study, the authors have treated intrabony periodontal defects with either MINST or minimally invasive surgical technique (MIST) [17]. The results at 3 and 6 months have failed to show any differences in terms of the clinical outcomes between the 2 procedures, thus suggesting that MINST may represent a valuable alternative to a surgical approach. An important observation was also the fact that treatment with MINST has led to an additional reduction of treatment chair time compared to MIST. A follow-up evaluation of the same patient population, together with findings made by other groups, has provided additional evidence suggesting that MINST may represent a valuable modality to successfully treat deep periodontal pockets associated with intrabony defects [18–20].

However, at present, according to the best of our knowledge, no data from randomized, controlled clinical studies are available evaluating the efficacy of MINST used with or without local application of an amino acid buffered sodium hypochlorite (NaOCl) gel in patients with untreated periodontitis.

Hence, the aim of the present randomized controlled clinical study was to evaluate the efficacy of minimally invasive nonsurgical debridement (MINST) of periodontal pockets with or without adjunct of amino acid buffered sodium hypochlorite (NaOCl) gel application over a period of 6 months.

Materials and methods

Study design

The study was designed as a double-arm, randomized controlled, superiority clinical trial. All periodontal pockets exhibiting probing depths (PD) of ≥ 5 mm were treated by means of MINST either alone (i.e. control group) or in combination with NaOCl gel application (i.e. test group). The study was conducted from May 2018 until December 2019. The study protocol was approved by the Commission on Research Ethics of the University of Messina (approval N°16/18).

Written informed consent was obtained from subjects and the study was conducted according to the Principles of the Declaration of Helsinki on experimentation involving human subjects. The research protocol was registered on Clinicaltrials.gov registry (registration number NCT04399187). The present trial was conducted according to the CONSORT statement (http://www.consort-statement.org). The null hypothesis of no statistically significant differences in terms of PD reduction between test and control procedure for the treatment of periodontal pockets was tested.

Participants

All subjects enrolled in the study were recruited from the School of Dentistry, University of Messina, Italy. Data were collected in the same research center and then the statistical analysis was performed in the Department of Periodontology, University of Naples Federico II, Italy.

Eligibility criteria for participants

Inclusion criteria:

- Untreated patients diagnosed with severe/advanced periodontitis (i.e. stage III/IV) with slow/moderate rate of progression (i.e. grade A/B) [21]
- Age ≥ 18 years old;
- Patients with at least 10 teeth per arch;
- Presence at least of two teeth with PD ≥ 5 mm per quadrant;
- Single-rooted teeth or multi-rooted teeth without furcation involvement;

Exclusion criteria:

- Patients with systemic diseases;
- Pregnant or lactating;
- Tobacco smokers (> 10 cigarettes/day);
- Previous periodontal treatment in the last 2 years;
- Prolonged antibiotic treatment or anti-inflammatory treatment within 6 months prior to periodontal therapy;
- Furcation involvement;
- Acute periodontal or endodontic abscesses;
- Third molars

Interventions

Clinical procedure

In the first session, all patients received a full-mouth supragingival scaling in order to remove the supragingival biofilm and calculus in combination with oral hygiene instructions and motivation.

After 1 week all clinical parameters were recorded (Fig. 1a) and subjects were randomly assigned to the test or control procedures. The test group was treated as follows:

1) After local anaesthesia, an amino acid–buffered sodium hypochlorite gel (Perisolv®, Regedent AG, Zurich, Switzerland) was applied for 30 s in periodontal pockets with PD ³5 mm using a sterile syringe with a plastic needle. The tip was carefully inserted into the pocket until resistance was reached and was followed by its slow ejection (Fig. 1b). No rinsing was performed after the application of the gel.
2) MINST was performed by means of careful subgingival debridement using ultrasonic scalers with specific thin tips (Instrument PS®EMS Electro Medical System S.A., Nyon, Switzerland) (Fig. 1c) and Gracey micro-curettes (Hu-Friedy®, Chicago, IL, USA) in order to minimize the trauma for the soft tissues (Fig. 1d).
3) Application of amino acid buffered sodium hypochlorite gel and MINST was performed according to the manufacturer's instructions.

In the control group, treatment consisted of MINST alone without gel application.

All treatments were performed using × 4.0 magnification loupes (Univet®, Italy). At the end of the subgingival treatment, in both groups, full-mouth supragingival cleaning by means of a rubber cup and a polishing paste was performed. Patients were instructed to rinse twice daily with 0.12% chlorhexidine digluconate (Curasept ADS® Curaden AG, Kriens, Switzerland) for the first 2 weeks. No antibiotics were prescribed. Patients were recalled on a monthly basis for professional supragingival tooth cleaning and motivation during the entire study period of 6 months when the final evaluation was made.

Outcome measures

The primary outcome variable was the probing depth (PD) reduction, defined as the distance from the gingival margin to the bottom of the pocket.

The secondary outcome variables were full-mouth plaque score (FMPS): percentage of tooth sites revealing the presence of plaque [22]; full-mouth bleeding score (FMBS): percentage of sites with bleeding on probing (BOP) [23]; clinical attachment level (CAL): distance from the cement-enamel junction (CEJ) to the bottom of the pocket and gingival recession (GR): distance from the gingival margin to the CEJ.

All clinical parameters were recorded at 6 sites per tooth by means of a manual periodontal probe (PCP-UNC 15®, Hu-Friedy, Chicago, IL, USA), applying a probing force of 0.2 N.

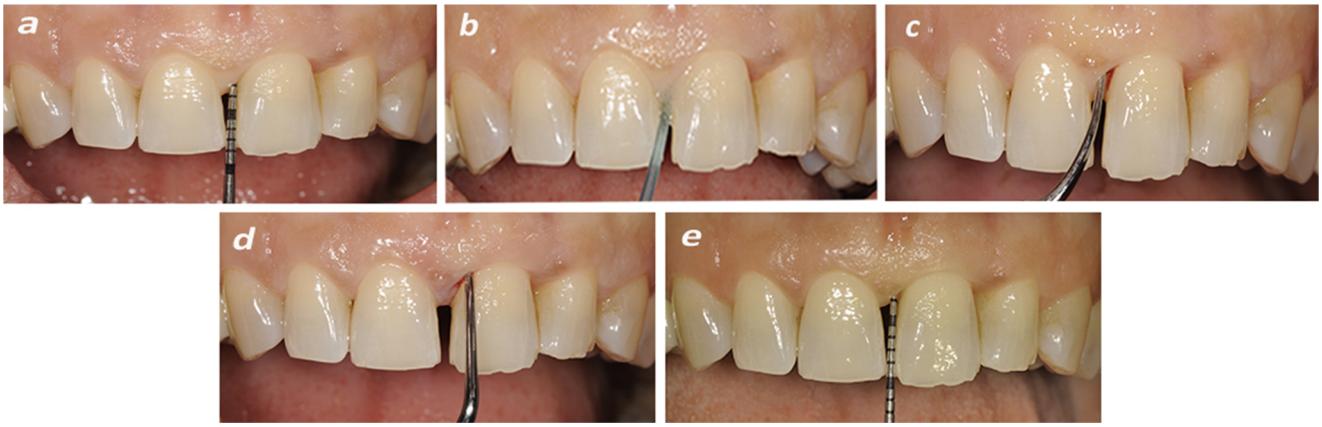

Fig. 1 **a** A probing depth (PD) of 7 mm was recorded at baseline. **b** Prior to mechanical instrumentation the NaOCl gel was applied in the periodontal pocket for 30 s. **c** Subgingival debridement was performed using an ultrasonic scaler with a thin tip. **d** A gently root planning was made by means of Gracey micro-curette. **e** A probing depth of 3 mm was recorded at 6 months post-therapy

All variables were recorded at baseline and after 6 months (Fig. 1e).

Sample size calculation

The present study was designed to test a continuous response variable (i.e. PD) from independent control and experimental subjects with 1 control per experimental subject. In a previous study, using a similar design [24], the response within each subject group was normally distributed with a standard deviation of 0.7 mm. If the true difference in the means of the experimental and control group is 0.9 mm, a sample of 22 patients (11 patients per group) is needed to reject the null hypothesis that the population means of the experimental and control groups are equal with probability (power) 0.8. The type I error probability associated with this test of this null hypothesis is 0.05. In order to compensate for patients' dropouts during the study period, a total of 40 subjects (i.e. 20 test and 20 control subjects) were enrolled in the study.

Randomization

A computerized random number generator was used in order to random assign the subjects to experimental or control procedures. A simple randomization without restrictions was done. The allocation concealment was made associating even numbers to the test procedure and odd number to the control procedure. The cards with numbers were closed in opaque envelopes and treatment allocation was performed at the time of minimally invasive nonsurgical treatment by opening the envelope containing the number.

The random allocation sequence was generated by A.B., while participants were enrolled by I.G. in the School of Dentistry, University of Messina, Italy.

Blinding and calibration

All patients enrolled in the study received periodontal therapy by the same periodontist (VIS). All parameters were recorded at baseline and after 6 months by 2 calibrated and masked examiners (I.G. and A.B.). Examiners attended a single training and calibration session on a total of 20 patients (kappa coefficient = 0.81). The calibration of all parameters was made in the same visit. The calibration meeting was performed at the School of Dentistry, University of Messina, Italy. Patients were not masked in respect to test and control procedures.

Statistical analysis

The data analysis was performed using a commercially available statistical software (NCSS-PASS, NCSS, Kaysville, UT). The patient was considered as the statistical unit; however, an additional site-based analysis was also performed. All variables were expressed in millimetres with the exception of the FMPS and FMBS, which were reported in percentage.

Descriptive statistics (e.g. mean and standard deviation) were used to present the variables (e.g. FMPS, FMBS, PD, CAL and GR). For the statistical analysis, sites with PD ≥ 5 mm at baseline were considered. An unpaired *t*-test was applied to compare the mean age of participant at baseline. A chi-square test was used to compare gender and number of smokers. In addition, also the number and percentages of sites with PD ≥ 5 with BOP positive at baseline and after the 6-month follow-up period were compared using a chi-square test.

In order to avoid pseudo-replication, an average of data proceeding from the same patient was calculated and used for statistical analysis. An intra-group comparison was made with paired *t*-test between FMPS, FMBS, PD, CAL and GR values assessed at baseline and follow-up for both procedures (i.e. MINST + NaOCl gel and MINST alone). An inter-group comparison between test and control procedures was performed with

an independent *t*-test for FMPS, FMBS, PD, CAL and GR at baseline, follow-up and for variations between baseline and follow-up values. In order to compare the frequency distribution of sites with residual PD between test and control groups, the Mantel-Haenszel χ^2 test was used. In addition, a sub-analysis for distribution of treated teeth in each group (i.e. anterior *vs* posterior and maxillary teeth *vs* mandibular teeth) was performed by means of the Mantel-Haenszel χ^2 test.

Cohen's *D* was calculated to assess the effect size in mean differences between the treatment groups for changes in PD, CAL and GR.

A p value < 0.05 was set to accept a statistically significant difference.

Results

Participants and recruitment

Figure 2 illustrates the flow chart of the study. After screening, 40 patients fulfilling the inclusion criteria were recruited. At 6 months, a total of 3 patients were lost (dropouts). Two patients were lost in the test group (subjects moved to another town). In the control group, 1 patient was lost because she was pregnant. Therefore, a total of 37 patients (18 subjects for the test group and 19 for the control group) were available for the final examination (Fig. 2). The study was conducted from May 2018 till December 2019. No complications related to any of the two procedures were recorded. Patient recruitment and treatment started in May 2018 and was completed in December 2018. The last follow-up visit was completed in June 2019. Data analysis was performed in September 2019.

Demographic characteristics

The characteristics of the patient population are presented in Table 1. Six males and 12 females (mean age 53.3 ± 9.8 years; range age 40–67 years) were included in the test group and 10 males and 9 females (48.5 ± 6.5 years; range age 36–63 years) were allocated to the control group. A total of 8 patients were smokers (< 10 cigarettes/day). No statistically significant differences ($p > 0.05$) were observed with respect to mean age, gender and smoking habits between the test and control group (Table 1).

Changes in FMPS and FMBS

Table 2 reports FMPS and FMBS at baseline and after 6-month follow-up. At baseline, FMPS was 47.1 ± 16.5% for the test group and 50.9 ± 12.4% for the control group, respectively. No statistically significant difference was found (p = 0.43) between groups. At a 6-month follow-up, a FMPS of 17.0 ± 4.8% and 17.6 ± 5.7% was recorded for the test and control group, respectively. No statistically significant differences were recorded (p = 0.72) between the test and control group. In both groups, a statistically significant change was found in terms of FMPS between baseline and 6-month follow-up (p = 0.001). At 6 months, a statistically significant improvement in mean FMBS was measured in both groups, i.e. from 39.8 ± 15.1 to 13.3 ± 6.0% in the test and from 43.8 ± 11.5 to 15.2 ± 6.0% in the control (p = 0.001) group, respectively. However, between the two groups, no statistically significant differences were found in terms of FMBS at baseline (p = 0.36) and at the 6-month follow-up (p = 0.35) (Table 2).

Probing depth changes

After 6 months, PD decreased statistically significantly (p = 0.001) from 5.96 ± 1.07 to 3.46 ± 1.08 mm in the test group and from 6.01 ± 1.60 to 4.03 ± 1.74 mm in the control group, respectively. At baseline, no statistically significant differences between the two groups (5.96 ± 1.07 mm vs. 6.01 ± 1.60 mm) were noted (p = 0.50). At 6 months, a statistically significant difference (3.46 ± 1.08 mm vs. 4.03 ± 1.74 mm) was found, favouring the test group (p = 0.001). At 6 months, the comparison between the mean changes between the test group (2.49 ± 0.76 mm) and the control group (1.98 ± 0.80 mm) was statistically significant (p = 0.001) (Table 3). The effect size (Cohen's *D*) of the PD changes from baseline to 6 months between two groups was d = 0.66 (CI 0.55–0.76).

Clinical attachment level changes

Six months after therapy, mean CAL changed from 6.24 ± 1.21 to 3.40 ± 2.16 mm in the test and from 6.41 ± 2.21 to 4.41 ± 3.02 mm in the control group, respectively. In both groups, a statistically significant difference was measured (p = 0.001). The inter-group comparison revealed a statistically not significant difference (p = 0.06) at baseline but yielded a statistically significant difference (p = 0.001) at 6 months (Table 3). The effect size (Cohen's *D*) of the CAL changes from baseline to 6 months between two groups was d = 0.42 (CI 0.32–0.52).

Gingival recession changes

The mean GR increased from 0.47±1.22 to 0.78 ± 1.72 mm in the test group and from 0.50 ± 1.33 to 0.76 ± 1.78 mm in the control group. However, the increase in GR from baseline to 6 months was not statistically significant in any of the 2 groups (p = 0.81). Furthermore, there were no statistically significant differences (p = 0.73) between the two groups at baseline and at 6 months (p = 0.81) (Table 3). The effect size (Cohen's *D*) of the GR changes from baseline to 6 months between two groups was d = 0.04 (CI − 0.06–0.13).

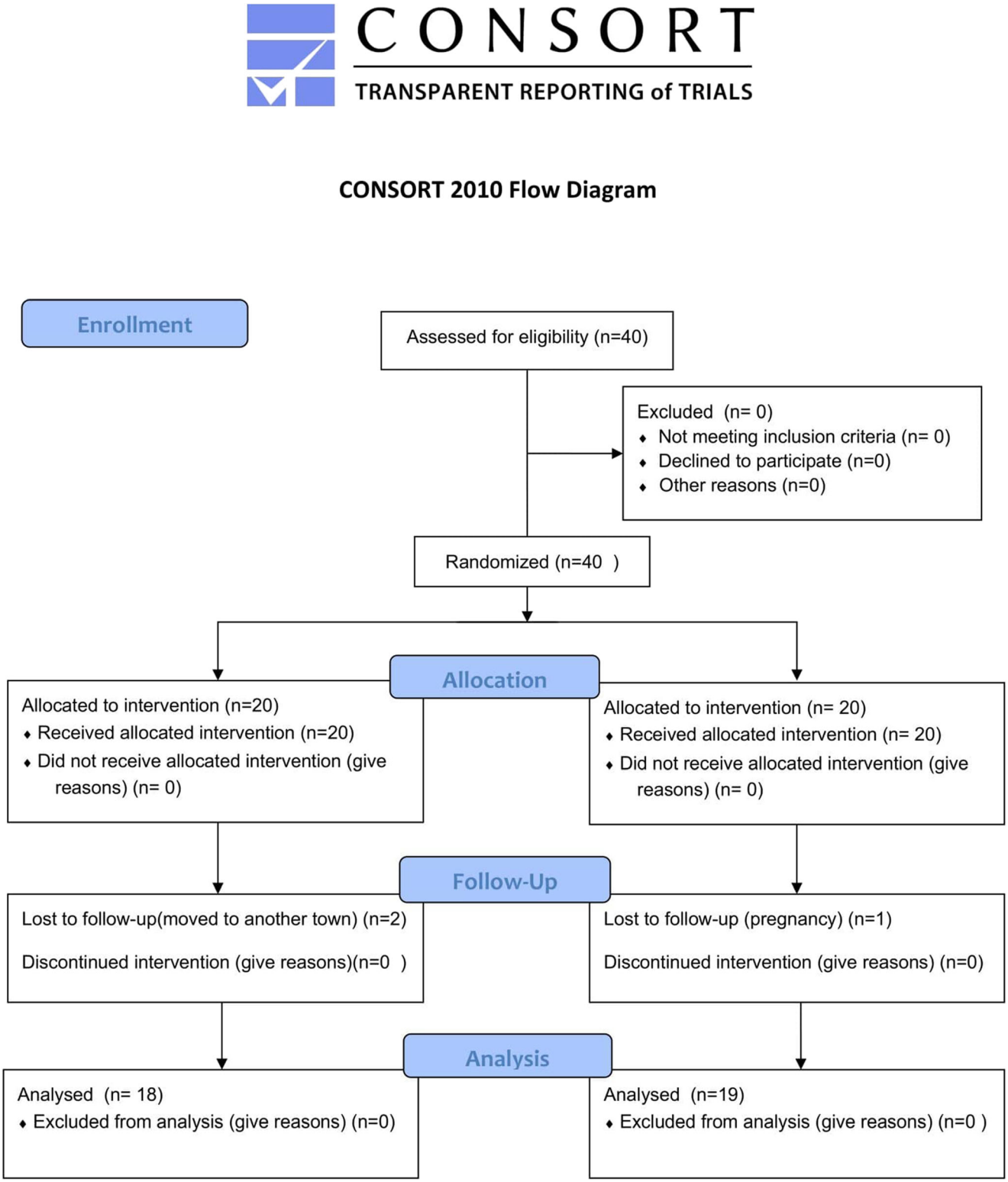

Fig. 2 CONSORT flowchart

Table 1 Patient population at baseline

	Test group (*N* = 18)	Control group (*N* = 19)	Significance (*p*)
Mean age (years)	53.3 ± 9.8	48.5 ± 6.5	0.43*
Range age (years)	40–67	36–63	
Gender (M/F)	6/12	10/9	0.19**
Smokers (*N*/%)	4; 22.2	4; 21.1	0.62**

M, male; *F*, female; *N*, number of patients

*Based on unpaired *t*-test

**Based on chi-square test

Number and percentages of sites with PD ≥ 5 mm with BOP positive

Table 4 summarized the number and percentages of sites with PD ≥ 5 mm with BOP. The number of sites with PD ≥ 5 mm and BOP decreased significantly (p = 0.001) from 763 (85.3%) to 20 (2.2%) for patients treated by means of MINST + NaOCl and from 594 (81.6%) to 53 (7.3%) for patients treated by means of MINST alone after 6-month follow-up. No statistically significant difference was recorded at baseline between the test and control group (p = 0.05). However, at 6 months, the differences between the two groups were statistically significant (p = 0.001) (Table 5).

Frequency distribution of residual PD

Details of the frequency distributions of residual PD changes are illustrated in Table 5. Statistically significant differences were found in terms of residual PD without BOP and for BOP-positive sites in both groups (p = 0.001).

In the test group, 14.5% of sites displayed PD ≥ 5 mm without BOP, while the corresponding values were 18.3% in the control group. The percentage of sites with PD ≥ 5 mm with BOP amounted to 7.2% in patients treated by means of MINST alone with the corresponding value of 2.2% sites with PD = 5 mm with BOP positive in patients treated with MINST + NaOCl. No sites with PD > 5 mm and BOP positive were found in the test group (Table 5).

Table 2 Comparison of FMPS and FMBS at baseline and after 6-month follow-up

	Baseline	6 months	Significance (*p*)
FMPS (%)			
Test group	47.1 ± 16.5	17.0 ± 4.8	0.001**
Control group	50.9 ± 12.4	17.6 ± 5.7	0.001**
Significance (*p*)	0.43*	0.72*	
FMBS (%)			
Test group	39.8 ± 15.1	13.3 ± 6.0	0.001**
Control group	43.8 ± 11.5	15.2 ± 6.0	0.001**
Significance (*p*)	0.36*	0.35*	

FMPS, full-mouth plaque score; *FMBS*, full-mouth bleeding score

*Based on paired *t*-test

**Based on independent *t*-test

Frequency distribution of sites with residual PD with BOP positive (*N*/%) after 6-month follow-up in respect to teeth location

A sub-analysis for the distribution of sites with residual PD with BOP positive is reported in Table 6. In anterior and posterior teeth, statistically significant differences were recorded comparing MINST + NaOCl and MINST alone (p = 0.001). Likewise, a statistically significant difference was found when in maxillary and mandibular sites test and control procedures were compared (p = 0.001) (Table 6).

Discussion

The present randomized controlled clinical trial has evaluated the outcomes obtained at 6 months by means of MINST with and without application of NaOCl in patients with untreated periodontitis exhibiting deep periodontal pockets. Both groups received exactly the same type of mechanical treatment (i.e. MINST), the only difference being the application of NaOCl in the test group prior to mechanical debridement. All pockets exhibiting probing depths (PD) of ≥ 4 mm were treated by MINST, but only pockets with PD ≥ 5 mm were considered for the statistical analysis.

At 6 months, PD decreased statistically significantly in the test group and control group, respectively. A closer analysis of the results revealed that the number of sites with PD ≥ 5 mm exhibiting BOP decreased statistically significantly in both groups, indicating excellent clinical outcomes. The obtained clinical outcomes can, on the one hand, be explained by the use of MINST consisting of careful subgingival debridement by means of ultrasonic scalers with specially designed thin tips and micro-curettes using high-magnification loupes. These findings are supported by results from previous studies,

Table 3 Comparison of probing depth (PD), clinical attachment level (CAL) and gingival recession (GR) at baseline and after the 6-month follow-up period

	Baseline	6 months	Changes	Significance (*p*)
PD (mm)				
Test group	5.96 ± 1.07	3.46 ± 1.08	2.49 ± 0.76	0.001**
Control group	6.01 ± 1.60	4.03 ± 1.74	1.98 ± 0.80	0.001**
Significance (*p*)	0.50*	0.001*	0.001*	
CAL (mm)				
Test group	6.24 ± 1.21	3.40 ± 2.16	2.84 ± 2.09	0.001**
Control group	6.41 ± 2.21	4.41 ± 3.02	2.01 ± 1.83	0.001**
Significance (*p*)	0.06*	0.001*	0.001*	
GR (mm)				
Test group	0.47 ± 1.22	0.78 ± 1.72	0.30 ± 1.16	0.81**
Control group	0.50 ± 1.33	0.76 ± 1.78	0.26 ± 0.97	0.81**
Significance (*p*)	0.73*	0.81*	0.42*	

PD, probing depth; *CAL*, clinical attachment level; *GR*, gingival recession

*Based on paired *t*-test

**Based on independent *t*-test

which have shown that MINST enables a thorough biofilm removal from the root surfaces and the periodontal pockets, reducing to a minimum the trauma of the soft tissues [17–20]. An important finding of previous studies was that at sites exhibiting intrabony defects, the use of MINST yielded similar outcomes to the surgical approach (i.e. MIST), thus pointing to the clinical relevance of this novel nonsurgical treatment modality as an alternative to the more invasive periodontal surgery [17–19].

On the other hand, it is important to be kept in mind that all the patients included in the study exhibited a high level of oral hygiene and received rigorous periodontal maintenance consisting of oral hygiene instructions and supragingival tooth cleaning performed on a monthly basis during the entire study period of 6 months.

These findings are in line with the results of a long-term study evaluating the outcomes of preventive dental treatment in a group of carefully monitored subjects who were motivated to maintain a high standard of oral hygiene and received regular supportive periodontal therapy. Today, there is ample evidence indicating that once probing depths are reduced and periodontal infection is controlled, the incidence of caries and periodontal disease as well as tooth mortality can be reduced to a minimum and kept stable over a long-time period (i.e. 30 years) [25].

An important aspect that needs to be discussed is that despite the fact that at 6 months after therapy, a dramatic reduction in the percentages of sites with PD ≥ 5 mm was measured in both groups; the magnitude of the improvement was statistically significantly higher when NaOCl gel was also applied. These clinical results appear to support the findings from "in vitro" studies which have provided evidence for the antibacterial effect of this novel NaOCl formulation and its positive effects on the survival, attachment and spreading of periodontal ligament cells [14, 15].

The present results are somewhat controversial to those very recently reported by Megally et al. [16]. In that study, a total of 365 sites in 32 patients enrolled in periodontal

Table 4 Number and percentages of sites with PD ≥ 5 with BOP positive at baseline and after the 6-month follow-up period

	Baseline	6 months	Significance (*p*)
Test groups	763/85.3	20/2.2	0.001*
Control groups	594/81.6	53/7.3	0.001*
Significance (*p*)	0.05*	0.001*	

*Based on the chi-square test

Table 5 Frequency distribution of sites with residual PD (*N*/%) with and without BOP positive after 6-month follow-up

	0–4 mm	5 mm	6 mm	7 mm	≥ 8 mm
Residual PD with BOP negative (*N*/%)					
Test group	665/74.3	86/9.6	44/4.9	0/0	0/0
Control group	496/68.1	91/12.5	28/3.8	8/1.0	8/1.0
Significance (*p*)	0.001*				
Residual PD with BOP positive (*N*/%)					
Test group	80/8.9	20/2.2	0/0	0/0	0/0
Control group	44/6.0	30/4.1	2/0.3	1/0.1	20/2.7
Significance (*p*)	0.001*				

PD, probing depth; *BOP*, bleeding on probing; *N*, number of sites

*Based on the Mantel-Haenszel χ^2 test

Table 6 Frequency distribution of sites with residual PD with BOP positive (*N*/%) after 6-month follow-up in respect to teeth location

	0–4 mm	5 mm	6 mm	7 mm	≥ 8 mm
Residual PD with BOP positive (*N*/%)					
Anterior teeth					
Test group	0 (0)	0 (0)	0 (0)	0 (0)	0 (0)
Control group	8 (27.6)	5 (17.2)	1 (3.4)	0 (0)	15 (51.7)
Significance (*p*)	0.001*				
Posterior teeth					
Test group	80 (80.0)	20 (20.0)	0 (0)	0 (0)	0 (0)
Control group	36 (52.9)	25 (36.8)	1 (1.5)	1 (1.5)	5 (3.0)
Significance (*p*)	0.001*				
Maxillary teeth					
Test group	70 (77.8)	20 (22.2)	0 (0)	0 (0)	0 (0)
Control group	33 (47.1)	21 (30.0)	0 (0)	1 (1.4)	15 (21.4)
Significance (*p*)	0.001*				
Mandibular teeth					
Test group	10 (100.0)	0 (0)	0 (0)	0 (0)	0 (0)
Control group	11 (40.7)	9 (33.3)	2 (7.4)	0 (0)	5 (18.5)
Significance (*p*)	0.02*				

PD, probing depth; *BOP*, bleeding on probing; *N*, number of sites
*Based on the Mantel-Haenszel χ^2 test

maintenance and exhibiting PD ≥ 5 mm were treated by means of repeated (i.e. at months 0, 4 and 8) subgingival debridement using ultrasonic tips, alone or with a NaOCl gel. However, at 12 months, the results have failed to reveal statistically significant differences between the 2 groups, suggesting no major advantages following the use of NaOCl gel. The discrepancy between our results and those reported by Megally et al. [16] can be explained by the use of a more accurate debridement approach (i.e. MINST) in conjunction with NaOCl in patients with untreated periodontitis. It has been repeatedly demonstrated that untreated periodontal pockets react more favourable to mechanical instrumentation compared to residual pockets in patients enrolled in maintenance [26]. Furthermore, it may also be speculated that deep pockets in patients with untreated periodontitis exhibit substantially higher amounts of biofilm and calculus, compared to patients with treated periodontitis and enrolled in maintenance. Conversely, in the present patient population, the use of NaOCl formulation might have had a higher potential to exert its antimicrobial and calculus softening properties, compared to those enrolled in the aforementioned study.

A limit of the present study can be the absence of radiographic analysis of treated sites. In a previous study [27], Nibali and co-workers reported a mean of radiographic bone level change of 2.93 mm at sites associated with intrabony defects treated by means MINST. In the present study, the radiographic evaluation was not performed because most parts of the sites with PD ≥ 5 mm were associated with supra-bony defects. In these defects, no or very limited bone gain can be expected after the treatment.

Since the healing capacity and immune response of each individual can significantly vary, the comparison of periodontal tissue response among different patients to the given clinical procedures could represent a limitation of the present study. This could be avoided by assigning test and control procedures within the same dentition. However, it would have been difficult to enrol sites with the same characteristics in terms of probing depth within the same dentition (i.e. sites with PD = 5 mm on the right side and sites with PD = 5 mm on the left side). For these reasons, the investigation was based on the patient and not on site.

Within their limits, the present results indicate that (a) the use of MINST may represent a clinically valuable approach for nonsurgical therapy and (b) the application of NaOCl gel in conjunction with MINST may additionally improve the clinical outcomes compared to the use of MINST alone.

Supplementary Information The online version contains supplementary material available at https://doi.org/10.1007/s00784-021-03841-8.

Funding Open access funding provided by Università degli Studi di Napoli Federico II within the CRUI-CARE Agreement. The authors and their respective institutions funded the study (Department of Periodontology, University of Naples Federico II, Naples, Italy). Regedent AG (Zürich, Switzerland) provided free of charge the materials used in the study.

Declarations

Ethical approval All procedures performed in studies involving human participants were in accordance with the ethical standards of the institutional and/or national research committee (Commission on Research Ethics of the University of Messina (approval N°16/18) and with the 1964 Helsinki declaration and its later amendments or comparable ethical standards.

Informed consent Informed consent was obtained from all individual participants included in the study.

Conflict of interest The authors declare no conflict of interest.

References

1. Sanz M, Beighton D, Curtis MA, Cury JA, Dige I, Dommisch H, Ellwood R, Giacaman RA, Herrera D, Herzberg MC, Könönen E, Marsh PD, Meyle J, Mira A, Molina A, Mombelli A, Quirynen M, Reynolds EC, Shapira L, Zaura E (2017) Role of microbial biofilms in the maintenance oral health and in the development of dental caries and periodontal diseases. Consensus report of group 1 of the Joint EFP/ORCA workshop on the boundaries between caries and periodontal disease. J Clin Periodontol 44(suppl 18):s5–s11. https://doi.org/10.1111/jcpe.12682
2. Lang NP, Salvi GE, Sculean A (2019) Nonsurgical therapy for teeth and implants-When and why? Periodontol 2000 79:15–21. https://doi.org/10.1111/.prd.12240

3. Suvan J, Leira Y, Moreno Sancho FM, Graziani F, Derks J, Tomasi C (2020) Subgingival instrumentation for treatment of periodontitis. A. systematic review. J Clin Periodontol 47(Suppl 22):155–175. https://doi.org/10.1111/jcpe.13245
4. Oda S, Nitta H, Setoguchi T, Izumi Y (2000) Ishikawa I (2004) Current concepts and advances in manual and power-driven instrumentation. Periodontol 36:45–58. https://doi.org/10.1111/j.1600-0775.2004.03674.x
5. Rabbani GM, Ash MM Jr, Caffesse RG (1981) The effectiveness of subgingival scaling and root planing in calculus removal. J Periodontol 52(3):119–123. https://doi.org/10.1902/jop.1981.52.3.119
6. Barbato L, Selvaggi F, Kalemaj Z, Buti J, Bendinelli E, La Marca M, Cairo F (2020) Clinical efficacy of minimally invasive surgical (MIS) and non-surgical (MINST) treatments of periodontal intrabony defect. A systematic review and network meta-analysis of RCT's. Clin Oral Investig 24:1125–1134. https://doi.org/10.1007/s00784-020-03229-0
7. Riberio FV, Casarin RC, Palma MA, Junior FH, Sallum EA, Casati MZ (2013) Clinical and microbiological changes after minimally invasive therapeutic approaches in intrabony defects: a 12-months follow-up. Clin Oral Investig 17:1635–1644. https://doi.org/10.1007/s00784-012-0855-5
8. Wilson TG Jr, Carnio J, Schenk R, Myers G (2008) Absence of histologic signs of chronic inflammation following closed subgingival scaling and root planing using the dental endoscope: human biopsies – a pilot study. J Periodontol 79:2036–2041. https://doi.org/10.1902/jop.2008.080190
9. Eliezer M, Imber JC, Sculean A, Pandis N, Teich S (2019) Hyaluronic acid as adjunctive to non-surgical and surgical periodontal therapy: a systematic review and meta-analysis. Clin Oral Investig 23:3423–3435. https://doi.org/10.1007/s00784-019-03012-w
10. Kalkwarf KL, Tussing GJ, Davis MJ (1982) Histologic evaluation of gingival curettage facilitated by sodium hypochlorite solution. J Periodontol 53:63–70. https://doi.org/10.1902/jop.1982.53.2.63
11. Tan OL, Safii SH, Razali M (2019) Commercial local pharmacotherapeutics and adjunctive agents for nonsurgical treatment of periodontitis: a contemporary review of clinical efficacies and challenges. Antibiotics (Basel) 9(1):11. https://doi.org/10.3390/antibiotics9010011
12. Galván M, Gonzalez S, Cohen CL, Alonaizan FA, Chen CT, Rich SK, Slots J (2014) Periodontal effects of 0.25% sodium hypochlorite twice-weekly oral rinse. A pilot study. J Periodontal Res 49(6):696–702. https://doi.org/10.1111/jre.12151
13. Bizzarro S, Van der Velden U, Loos BG (2016) Local disinfection with sodium hypochlorite as adjunct to basic periodontal therapy: a randomized controlled trial. J Clin Periodontol 43:778–788. https://doi.org/10.1111/jcpe.12578
14. Jurczyk K, Nietzsche S, Ender C, Sculean A, Eick S (2016) In-vitro activity of sodium-hypochlorite gel on bacteria associated with periodontitis. Clin Oral Investig 20:2165–2173. https://doi.org/10.1117/s00784-016-1711-9
15. Schmidlin PR, Fujioka-Kobayashi M, Mueller HD, Sculean A, Lussi A, Miron RJ (2017) Effects of air polishing and an amino acid buffered hypochlorite solution to dentin surfaces and periodontal ligament cell survival, attachment, and spreading. Clin Oral Investig 21(5):1589–1598. https://doi.org/10.1007/s00784-016-1950-9
16. Megally A, Zekeridou A, Cancela J, Giannopoulou C, Mombelli A (2020) Short ultrasonic debridement with adjunctive low-concentrated hypochlorite/amino acid gel during periodontal maintenance. Randomized clinical trial of 12 months. Clin Oral Investig 24:201–209. https://doi.org/10.1007/s00784-019-02949-2
17. Riberio FV, Casarin RC, Palma MA, Junior FH, Sallum EA, Casati MZ (2011) Clinical and patient-centered outcomes after minimally invasive non-surgical or surgical approaches for the treatment of intra-bony defects: a randomized clinical trial. J Periodontol 82:1256–1266. https://doi.org/10.1902/jop.2011.100680
18. Ribeiro FV, Casarin RC, Palma MA, Júnior FH, Sallum EA, Casati MZ (2013) Clinical and microbiological changes after minimally invasive therapeutic approaches in intrabony defects: a 12-month follow-up. Clin Oral Investig 17(7):1635–1644. https://doi.org/10.1007/s00784-012-0855-5
19. Nibali L, Koidou V, Salomone S, Hamborg T, Allaker R, Ezra R, Zou L, Tsakos G, Gkranias N, Donos N (2019) Minimally invasive non-surgical vs. surgical approach for periodontal intrabony defects: a randomised controlled trial. Trials 20(1):461. https://doi.org/10.1186/s13063-019-3544-8
20. Aimetti M, Ferrarotti F, Mariani GM, Romano F (2017) A novel flapless approach versus minimally invasive surgery in periodontal regeneration with enamel matrix derivative proteins: a 24-month randomized controlled clinical trial. Clin Oral Investig 21(1):327–337. https://doi.org/10.1007/s00784-016-1795-2
21. Tonetti MS, Greenwell H, Kornman KS (2018) Staging and grading of periodontitis: framework and proposal of a new classification and case definition. J Periodontol 89(Suppl 1):S159–S172. https://doi.org/10.1002/JPER.18-0006
22. O'Leary TJ, Drake RB, Naylor JE (1972) The plaque control record. J Periodontol 43:38. https://doi.org/10.1902/1972.43.1.38
23. Lang NP, Joss A, Orsanic T, Gusberti F, Siegrist BE (1986) Bleeding on probing. A predictor for the progression of periodontal disease? J Clin Periodontol 13:590–596. https://doi.org/10.1111/j.1600-051x.1986.tb00852.x
24. Isola G, Matarese G, Williams RC, Iorio Siciliano V, Alibrandi A, Cordasco G, Ramaglia L (2018) The effects of a desiccant agent in the treatment of chronic periodontitis: a randomized, controlled clinical trial. Clin Oral Investig 22:791–800. https://doi.org/10.1007/s00784-017-2154-7
25. Axelsson P, Nyström B, Lindhe J (2004) The long-term effect of a plaque control program on tooth mortality, caries and periodontal disease in adults. Results after 30 years of maintenance. J Clin Periodontol 31(9):749–757. https://doi.org/10.1111/j.1600-051X.2004.00563.x
26. Badertsen A, Nilveus R, Egelberg J (1984) Effect of nonsurgical periodontal therapy. III. Single versus repeated instrumentation. J Clin Periodontol 11(2):114–124. https://doi.org/10.1111/j.1600-051x.1984.tb00839.x
27. Nibali L, Pometti D, Chen TT, Tu YK (2015) Minimally invasive non-surgical approach for the treatment of periodontal intrabony defects: a retrospective analysis. J Clin Periodontol 42:853–859. https://doi.org/10.1111/jcpe.12443

Received: 3 February 2020 | Revised: 1 March 2020 | Accepted: 3 March 2020

DOI: 10.1002/cre2.286

ORIGINAL ARTICLE

Clinical and Experimental Dental Research Open Access WILEY

A nonsurgical treatment of peri-implantitis using mechanic, antiseptic and anti-inflammatory treatment: 1 year follow-up

Yaniv Mayer[1,2] | Ofir Ginesin[1,2] | Jacob Horwitz[1,3]

[1]Department of Periodontology, School of Graduate Dentistry, Rambam Health Care Campus, Haifa, Israel

[2]Periocenter Ltd., Haifa, Israel

[3]The Ruth and Bruce Rappaport Faculty of Medicine, Technion, Israel Institute of Technology, Haifa, Israel

Correspondence
Yaniv Mayer, Department of Periodontology, School of Graduate Dentistry, Rambam Health Care Campus, POB 9602, Haifa 31096, Israel.
Email: dr.yaniv.mayer@gmail.com

Abstract

Aims: The study's aim was to assess the clinical outcome 6 and 12 months after a nonsurgical treatment of peri-implantitis per se or in conjunction with a combination of local antiseptic and anti-inflammatory treatment.

Materials and methods: Included were 69 patients with periodontitis, with 106 implants, diagnosed with peri-implantitis. Peri-implantitis was defined as radiographic bone loss ≥3 mm, probing depth (PD) ≥ 6 mm, with bleeding on probing. Group M peri-implantitis was treated with ultrasonic debridement and soft tissue curettage. Group P had additional implant surface treatment with rotatory hand piece composed of chitosan bristle, soft tissue curettage combined with application of 0.95% hypochlorite and 1 mg minocycline HCl.

Results: After 6 months, both groups demonstrated significant reduction of mean plaque index, PD, and clinical attachment level (0.71 ± 0.57, 0.81 ± 0.55; 4.77 ± 0.73 mm, 4.42 ± 0.5 mm; 5.03 ± 0.86 mm, 5.13 ± 0.73 mm; respectively) and bleeding on probing. After 6 and 12 months, group P showed significantly better PD results compared to group M. The bleeding was significantly less in group P after 12 months (15.3% ± 6.2, 25.1% ± 8.2, respectively).

Conclusions: Adjunctive treatment with local antiseptic and anti-inflammatories during mechanical phase was positively associated with inflammation reduction and connective tissue reattachment.

KEYWORDS

anti-inflammatory, chitosan, minocycline, nonsurgical treatment, peri-implantitis, slow release device

1 | INTRODUCTION

Dental implants are valid choice for lost tooth replacement due to the high survival rate; however, biological complications are not rare. The main biological complication is peri-implantitis, a plaque-associated pathological condition that occurs in tissues around dental implants, which is characterized by inflammation in the peri-implant mucosa and loss of supporting bone (Berglundh et al., 2018). Extensive bone loss might require implant explanation. The prevalence of peri-implantitis is significant, as assessed in several meta-analyses: Rakic et al. (2018) reported a rate of 18.5% at patient level and 12.8% at implant level (Rakic et al., 2018); Muñoz, Duque, Giraldo, and Manrique (2018) showed similar results with 17% at patient level and 11% at implant level (Muñoz et al., 2018); while Hashim, Cionca, Combescure, and Mombelli (2018) reported a wider range with 0–62.1% at implant level and 9.1–69% at patient level (Hashim et al., 2018).

Peri-implantitis exhibits greater tissue and bone destruction compared to periodontitis (Carcuac & Berglundh, 2014; Hiyari et al., 2018), and therefore must be treated and followed more intensively. The main goals of peri-implantitis treatment are to resolve inflammation and prevent further bone loss by decontaminating the implant surface. Treatment success is determined by no suppuration or bleeding on probing (BOP), absence of erythema and swelling, no additional bone loss, and pocket depths ≤5 mm (Berglundh et al., 2018). Treatment modalities are comprised surgical and nonsurgical procedures.

Surgical procedures range between flap surgery with or without osseous resection, to regenerative approaches using xenografts, allografts, or alloplastic materials (Keeve et al., 2019; Ramanauskaite, Becker, Juodzbalys, & Schwarz, 2018). Surgical treatments are associated with risks, adverse events, and postsurgical complications. The results of surgical treatment for peri-implantitis are controversial in current literature (Chan, Lin, Suarez, MacEachern, & Wang, 2014; Keeve et al., 2019; Ramanauskaite et al., 2018).

Nonsurgical treatments include debridement using various devices (e.g., manual instruments, ultrasonic/sonic instruments, plastic or carbon tips, air powder, photodynamic therapy), with antimicrobial agents including systemic or local antimicrobial treatment (Estefanía-Fresco, García-de-la-Fuente, Egaña-Fernández-Valderrama, Bravo, & Aguirre-Zorzano, 2019; Heitz-Mayfield & Mombelli, 2014; Machtei, 2014; Suárez-López Del Amo, Yu, & Wang, 2016). Outcomes of current nonsurgical treatments show limited success and low predictability (Lang, Salvi, & Sculean, 2019).

Mechanical debridement using stainless steel instruments on implant surface causes modifications of the implant surface (Keim et al., 2019; Louropoulou, Slot, & Van der Weijden, 2012), and releases titanium (Ti) particles into the surrounding tissue (Suárez-López Del Amo, Garaicoa-Pazmiño, Fretwurst, Castilho, & Squarize, 2018), which might cause further complications (Eger, Sterer, Liron, Kohavi, & Gabet, 2017, Fretwurst, Nelson, Tarnow, Wang, & Giannobile, 2018). This requires the use of instruments to reduce implant damage while maximizing the cleaning effect (de Tapia et al., 2019; Mann, Parmar, Walmsley, & Lea, 2012; Viganò et al., 2019). In an in-vitro study, Keim et al. examined debridement with single device and found air powder abrasion was more efficient than sonic scaler, which in turn was more efficient than curette. Nevertheless, in all cases, unreached areas were visible (Keim et al., 2019). In the same study, air abrasion showed no surface damage, while sonic scaler and curette damaged the implant surface (Keim et al., 2019).

The aim of this retrospective study is to compare the clinical outcome of nonsurgical mechanical treatment of peri-implantitis, as sole treatment with a combination of mechanical, and local antiseptic and anti-inflammatory treatments, 6 and 12 months after therapy.

2 | MATERIALS AND METHODS

2.1 | Ethical statement

This is a retrospective, single-center, clinical trial with a 12-month follow-up. The study was approved by the institutional ethical committee (0213-19-rmb) and conducted according to the principles outlined in the Declaration of Helsinki and Ethical Conduct for Research with Human Beings. Informed consents were obtained from all the subjects who participated in this study. The clinical trial is reported in accordance with Consolidated Standards of Reporting (CONSORT) guidelines.

2.2 | Study population

Subjects presented at our clinic were diagnosed with periodontitis and peri-implantitis and underwent periodontal treatment.

2.3 | Inclusion criteria

Patients with at least one titanium implant that exhibited radiographic bone loss ≥3 mm, probing depth (PD) ≥6 mm, and BOP (Berglundh et al., 2018). Periodontal treatment, including oral hygiene instruction, followed by supra and subgingival mechanical instrumentation.

2.4 | Exclusion criteria

No clinical documentation at 6 and/or 12 months post-treatment; surgery was performed on the relevant sextant.

2.5 | Treatment

Periodontal treatment consisted of supra and subgingival mechanical instrumentation of the root surface with ultrasonic instrumentation after rinsing with 0.12% CHX during 1 min, under the appropriate local anesthesia. Patients were divided according to the treatment of implants with peri-implantitis in two groups: Ultrasonic debridement with fine tips (EMS, Chemin de la Vuarpillière, 31, 1260 Nyon, Switzerland); soft tissue curettage used Teflon-coated curettes (group M), or application of 0.95% hypochlorite with amino acids (Perisolv, RLS global AB, Mölndal, Sweden) were performed. In the group P, before use, the two components were mixed together. The sodium hypochlorite and the amino acids formed short-lived chloramines (N-carboxy anhydride, NCA) in a gel consistency. The gel was syringed to the pocket and filled it until overflowed. After allowing to act for 30 s, the treatment was followed by soft tissue curettage and using rotatory hand piece composed of chitosan bristle (Labrida, Oslo, Norway). The Chitosan bristle was soaked in sterile saline for at least 2 min prior to use. This made the chitosan fibers swell, and thus became soft and flexible, leading to optimal strength. The application of the hypochlorite and the curettage were repeated three times in the session. At the end, an application of 1 mg minocycline HCl (Arestin, OraPharma, NJ) (Figure 1a–e). All patients were informed before the procedure about the two therapy modalities and they had the right to decide which treatment to choose.

All patients were seen at 3-month intervals during 1 year, as part of a routine maintenance periodontal program. Treatment outcomes were evaluated at 6 and 12 months.

2.6 | Clinical outcomes

At baseline, 6 (T1) and 12 (T2) months, the same examiner (Y.M.) recorded the following clinical variables using a manual periodontal probe (PCP-UNC 15; Hu-Friedy, Chicago, IL):

- Plaque index (PI) (Silness & Loe, 1964)
- Peri-implant (PPD), measured from the mucosal margin to the bottom of the probable pocket, and assessed at six sites per implant.
- Clinical attachment loss (CAL), measured from the implant neck to the bottom of the probable pocket, and assessed at six sites per implant.
- BOP assessed in six sites per implant.

2.7 | Radiographic examination

- Bone level (BL) was measured from the implant-abutment connection to the bottom of the bone defect by one examiner (O.G.), at

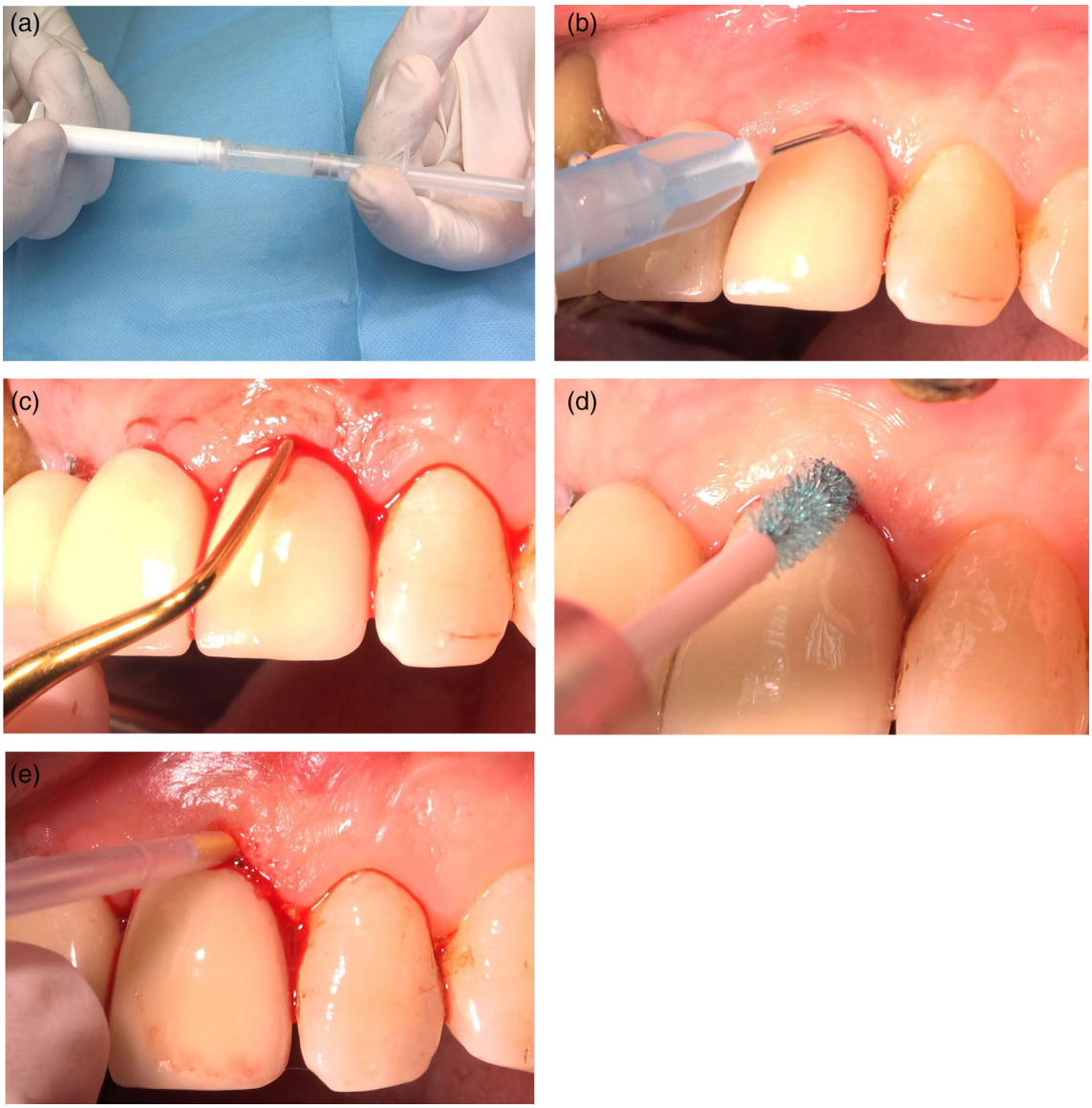

FIGURE 1 (a) Activating the solution by mixture of 0.95% sodium hypochlorite with amino acids, sodium chloride, titanium oxide, and carboxyl methylcellulose. (b) Injection of 0.95% sodium hypochlorite into the sulcus and waiting 30 s for softening the granulation tissue and prepare it for degranulation with curette. (c) Degranulation the tissue without working on the implant surface. (d) Mechanical cleaning of the implant surface with a bristle composed of a fast degrading chitosan attached to an oscillating hand piece. (e) Injection of 1 mg minocycline HCl Microspheres in to the sulcus

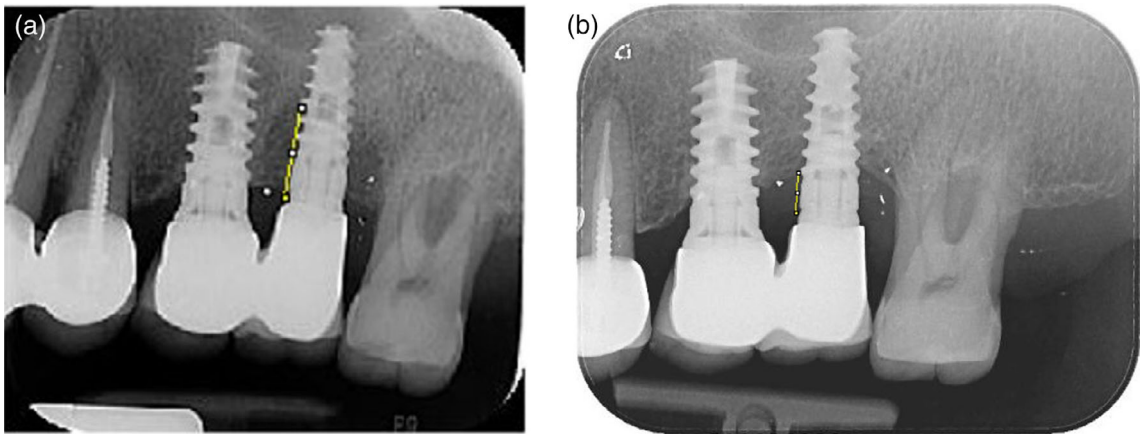

FIGURE 2 (a) Pretreatment peri-apical radiograph. (b) 12 months' post-treatment radiograph (group P)

TABLE 1 Demographic data at baseline

Characteristic	M	P
Number of patients	34	35
Number of implants	52	54
Age ± *SD*	55.3 ± 6	54.2 ± 4
Male/ female	12/22	11/24
Smoker (%)	12%	10%
Implant position		
Maxilla, (%)	46%	48%
Mandible (%)	54%	52%
Type of restoration		
Screw retained (%)	34%	39%
Cemented (%)	66%	61%

Note: Data are presented as mean (*SD*) or percentage.

baseline and T2, using image analysis software (ImageJ software, Java image processing program, National Institutes of Health [NIH], Bethesda) (Figure 2). In each radiograph, the length of the implant provided by the manufacturer was used to calibrate the "apico-coronal" measurements. The distance to the coronal bone was measured at both the mesial and distal aspects of the implant.

2.8 | Statistical analysis

Power calculation was initially performed to determine sample size. Nonsurgical therapy of peri-implantitis can reduce pocket depth 1 mm (average). Additional reduction after using antibacterial methods reach 0.7 mm, Standard values of alpha = 0.05 and power = 80% were used. Power analysis according to these parameters yielded a sample size was of at least 32 in each group.

SPSS version 19.00 software (SPSS Inc., Chicago, IL) was used for all analyses. Primary outcome was changes in PPD at the deepest site at baseline to 6 months, and baseline to 12 months. The main outcome variable (PPD changes) and secondary variables (PI and CAL) were expressed as mean ± *SD*.

Mann–Whitney *U* test was used to compare between groups among time points (time points were not normally distributed). Level of significance was set at $p = .05$.

Independent *t* tests were used to verify differences for radiographic analysis.

3 | RESULTS

Sixty nine patients treated during January 1, 2016–December 31, 2017 for periodontitis (grade 1–3, and stage A–B), who had a total of 106 implants with peri-implantitis, were included. Demographic data at baseline showed no significant differences between the two groups (Table 1).

PI, PPD, and CAL at baseline, and after 6 and 12 months, are summarized in Table 2 (mean ± *SD*). PI, PPD, and CAL decreased significantly after 6 and 12 months, compared with baseline values ($p < .001$) (Table 3). No significant differences were observed after 12 months compared to 6 months for both groups.

Comparison between the two treatments modality groups indicated a significant difference in PPD after 6 and 12 months (Table 4). With regard to PD, after 6 and 12 months group P showed significantly better results compared to group M alone (difference of 0.65 mm between baseline and 6 months and 0.64 mm between baseline and 12 months). No significant differences were found in CAL reduction between the two groups at the two time points. Bleeding was significantly reduced in the two groups after 6 and 12 months. Significantly, fewer sites with bleeding were found in group P during the entire follow-up period.

Peri-apical radiographs pretreatment and 12 months post-treatment were available for limited number of implants (12 in the group P and 15 in the group M). Radiographic analysis of bone level measurements did not yield statistically significance differences between the two treatment modalities (data not shown/data on file).

TABLE 2 Mean clinical parameters measured at baseline, 6 months, and 12 months (mean ± *SD*)

	Baseline			6 months			12 months		
	M	P	*p* value	M	P	*p* value	M	P	*p* value
PI	1.63 ± 0.65	1.51 ± 0.63	0.36	0.71 ± 0.57	0.81 ± 0.55	0.39	0.69 ± 0.5	0.78 ± 0.5	0.38
PD (mm)	6.63 ± 1.10	6.94 ± 1.32	0.19	4.77 ± 0.73	4.42 ± 0.5	**0.006**	4.90 ± 0.66	4.57 ± 0.63	**0.01**
CAL (mm)	6.87 ± 1.18	7 ± 1.38	0.59	5.03 ± 0.86	5.13 ± 0.73	0.56	5.40 ± 0.72	5.33 ± 0.67	0.60
BOP (%)	100	100	0.6	33.2 ± 12.3	21.4 ± 14.2	0.6	25.1 ± 8.2	15.3 ± 6.2	**0.05**

Note: All significant results are in bold.
Abbreviations: BOP, bleeding on probing; CAL, clinical attachment loss; PI, plaque index; PPD, probing depth.

TABLE 3 Statistical significance of periodontal parameters changes among the different time points in the same groups

	Baseline–6 months		Baseline–12 months		6–12 months	
	M	P	M	P	M	P
PI	**<0.001**	**<0.001**	**<0.001**	**<0.001**	NS	NS
PPD	**<0.001**	**<0.001**	**<0.001**	**<0.001**	NS	NS
CAL	**<0.001**	**<0.001**	**<0.001**	**<0.001**	**0.002**	**<0.001**
BOP	**<0.001**	**<0.001**	**<0.001**	**<0.001**	NS	NS

Note: All significant results are in bold.
Abbreviations: BOP, bleeding on probing; CAL, clinical attachment loss; PI, plaque index; PPD, probing depth.

TABLE 4 Differences between group P and M at two time points (Mann Whitney *U* test)

	Baseline–6 months	Baseline–12 months	6–12 months
PI	0.21	0.19	0.90
PPD	**0.02**	**0.019**	0.94
CAL	0.94	0.43	0.47
BOP	**0.001**	**0.001**	0.5

Note: All significant results are in bold.
Abbreviations: BOP, bleeding on probing; CAL, clinical attachment loss; PI, plaque index; PPD, probing depth.

4 | DISCUSSION

This study aimed to compare clinical findings 6 to 12 months after using two nonsurgical methods of treatment for peri-implantitis. We proposed a simple, nonsurgical treatment modality for peri-implantitis that is easily accessible and readily available for most dental practitioners. The findings revealed a positive effect of combined protocol, including nonsurgical mechanical debridement with chitosan brushes in conjunction with local delivery of minocycline microspheres and 0.95% hypochlorite buffered with amino acids; the positive effect was maintained over the 12-month follow-up period. There was a synergistic effect in combining mechanical debridement as sole treatment (improved clinical parameters) with antiseptic and anti-inflammatory treatment that further improved clinical outcome.

Biological rational of combining both materials with mechanical debridement is based on their different healing mechanisms. Hypochlorite buffered with amino acids, accompanied by mechanical debridement, disrupts the biofilm and removes granulation tissue (Roos-Jansåker, Almhöjd, & Jansson, 2017). Minocycline HCl has an antimicrobial effect, improving probing depths and bleeding scores of pathologic peri-implant tissue (Renvert, Lessem, Dahlén, Lindahl, & Svensson, 2006), and has a continuous effect, lasting for several days (Lee, Kweon, Cho, Kim, & Kim, 2018). Thus, initially removing granulation tissue and disrupting the biofilm increases efficiency of the antimicrobial agent. Furthermore, Minocycline HCl was proven to reduce collagenase activity, inhibit the activity of matrix metalloproteinases as well as osteoclast function, and thus prevent further periodontal destruction (Ingman et al., 1993; Vernillo, Ramamurthy, Golub, & Rifkin, 1994). Kivelä-Rajamäki et al. (2003) showed that the antibiotic tetracycline reduced MMP-8 (collagenase-2) in peri-implant sulcular fluid (Kivelä-Rajamäki et al., 2003).

Our results are in accordance with previous studies, although higher reduction in PD and CAL were reached when comparing group M (mechanical debridement only) (Renvert et al., 2006; Renvert, Lessem, Dahlén, Renvert, & Lindahl, 2008). This difference might be due to deeper PD and CAL at baseline examination, compared to previous studies (Renvert et al., 2006, Renvert et al., 2008). The proposed combined treatment yielded greater pocket depth reduction compared to each of the treatments (2.5 mm after 6 months, 2.37 mm after 12 months). Salvi, Persson, Heitz-Mayfield, Frei, and Lang (2007) showed improvement in PD after 6 and 12 months (1.7 and 1.7 mm, respectively) when using minocycline microspheres only (Salvi et al., 2007). Roos-Jansåker et al. (2017) showed PD reduction of 1.75 mm after 3 months, when using hypochlorite buffered with amino acids (Roos-Jansåker et al., 2017). Renvert et al. (2008) used minocycline microspheres in addition to mechanical debridement, compared to mechanical debridement only, and showed relative PD reduction of

0.6 mm after 12 months, supporting the use of minocycline. The results of our current study were similar, showing statistically significant differences in PD after 6 and 12 months (Renvert et al., 2008).

Systemic antibiotics are considered a valid approach to treat peri-implantitis, in addition to mechanical debridement (Lang et al., 2019). Mombelli and Lang (1992) showed positive clinical and microbiological results after using systemic delivery of ornidazole for 10 days, with an average PD reduction of 2.55 mm after 12 months of treatment (Mombelli & Lang, 1992). Nart et al. (2019) showed similar results using Metronidazole 500 mg every 8 hr for 7 days (Nart et al., 2019), with Liñares, Pico, Blanco, and Blanco (2019) demonstrated that adjunctive administration of systemic metronidazole has shown potential effectiveness in terms of PD and radiographic defect reduction (Liñares et al., 2019). Although it might be useful, systemic antibiotic poses some risks including: superinfection (Verdugo, 2017) and antibiotic resistance (Rams, Degener, & van Winkelhoff, 2014). Proposed protocol includes local administration of antibiotics, which reduces the risk of the above mentioned complications and achieves similar clinical results compare to administration of systemic antibiotics (average pocket depth reduction of 2.37 mm in current study).

Chitosan bristle was proved to be a safe and efficient device for debridement of dental implants (Wohlfahrt, Aass, & Koldsland, 2019; Wohlfahrt et al., 2017; Zeza, Wohlfahrt, & Pilloni, 2017). Previous studies on Chitosan bristle's added value include reduced signs of inflammation (Modified Bleeding Index [mBoP] by 1.2) and probing depth (1.15 mm) (Wohlfahrt et al., 2017, Wohlfahrt et al., 2019, Zeza et al., 2017). Chitosan is an antimicrobial that relies on numerous intrinsic and extrinsic factors, such as pH, presence or absence of metal cations, pKa, molecular weight, and degree of deacetylation (Kong, Chen, Xing, & Park, 2010). In particular, Larsen et al. (2017) found that chitosan bristle significantly reduced the amount of a periopathogenic bacteria, *Porphyromonas gingivalis* (Larsen et al., 2017). Another benefit of the chitosan bristle is its ability to reach difficult to negotiate areas, due to its flexibility and long active surface. This makes superfluous any prosthetic changes (e.g., removal of prosthetic work) as most of the prosthetic work in both groups (P, M) was cemented and not screw retained (61 and 66%, respectively).

One of the causes for peri-implantitis is residual cement, particularly in patients with history of periodontitis (Linkevicius, Puisys, Vindasiute, Linkeviciene, & Apse, 2013; Quaranta, Lim, Tang, Perrotti, & Leichter, 2017). Optional reason for the superior results of group P is cement removal, achieved in the suggested protocol in the phase of soft tissue curettage with rotatory hand piece composed of chitosan bristle. This should be further examined in future studies.

CAL did not show significant difference between the groups. This suggests that part of the improvement was due to recession of the soft tissue and part due to re-attachment of connective tissue. Extrapolating the results suggests that 1/3 of pocket reduction was due to connective tissue reattachment and 2/3 to recession formation. This improvement is in agreement with a previous study (Roos-Jansåker et al., 2017).

This study has limitations in terms of the relatively short follow-up period of 12 months; longer follow-up is required to confirm long-term results of the treatment protocol.

Another drawback is that due to the retrospective nature of this study—availability of pretreatment and 12 months' post-treatment radiographs were limited. This fact together with lack of personal stent might influence our ability to fully discover the radiographic changes following the suggested treatment modality. Therefore, future studies will include radiographic follow-up.

5 | CONCLUSIONS

Within the limitations of the present study, additional use of chitosan brush to implant surface decontamination with combined application of 0.95% hypochlorite and 1 mg minocycline HCl as part of peri-implantitis nonsurgical treatment, resulted in statistically significant clinical improvement in terms of reduction of pocket depth after 6 and 12 months.

6 | CLINICAL RELEVANCE

6.1 | Scientific rationale for study

To evaluate the clinical outcome of a nonsurgical treatment of peri-implantitis by mechanical, antiseptic, and anti-inflammatory methods; and compare it to a mechanic treatment alone.

6.2 | Principal findings

Both modalities showed improvement in clinical parameters after 6 and 12 months. Group P demonstrated greater reduction in pocket depth and bleeding.

6.3 | Practical implications

Using antiseptic and anti-inflammatory treatment during the cause related therapy at sites with peri-implantitis can be an alternative for surgery in mild to moderate cases.

CONFLICT OF INTEREST

The authors, therefore, declare no conflict of interests related to the content of this manuscript.

ORCID

Yaniv Mayer https://orcid.org/0000-0001-5500-7961

REFERENCES

Berglundh, T., Armitage, G., Araujo, M. G., Avila-Ortiz, G., Blanco, J., Camargo, P. M., … Zitzmann, N. (2018). Peri-implant diseases and conditions: Consensus report of workgroup 4 of the 2017 world workshop on the classification of periodontal and Peri-implant diseases and

conditions. *Journal of Periodontology*, *89*(Suppl 1), S313–S318. https://doi.org/10.1002/JPER.17-0739

Carcuac, O., & Berglundh, T. (2014). Composition of human peri-implantitis and periodontitis lesions. *Journal of Dental Research*, *93*(11), 1083–1088. https://doi.org/10.1177/0022034514551754

Chan, H. L., Lin, G. H., Suarez, F., MacEachern, M., & Wang, H. L. (2014). Surgical management of peri-implantitis: A systematic review and meta-analysis of treatment outcomes. *Journal of Periodontology*, *85*(8), 1027–1041. https://doi.org/10.1902/jop.2013.130563

de Tapia, B., Valles, C., Amaral, T., Mor, C., Herrera, D., Sanz, M., & Nart, J. (2019). The adjunctive effect of a titanium brush in implant surface decontamination at peri-implantits surgical regenerative interventions: A randomized controlled clinical trial. *Journal of Clinical Periodontology*, *46*, 586–596. https://doi.org/10.1111/jcpe.13095

Eger, M., Sterer, N., Liron, T., Kohavi, D., & Gabet, Y. (2017). Scaling of titanium implants entrains inflammation-induced osteolysis. *Scientific Reports*, *7*, 39612. https://doi.org/10.1038/srep39612

Estefanía-Fresco, R., García-de-la-Fuente, A. M., Egaña-Fernández-Valderrama, A., Bravo, M., & Aguirre-Zorzano, L. A. (2019). One-year results of a nonsurgical treatment protocol for peri-implantitis. A retrospective case series. *Clinical Oral Implants Research*, *30*(7), 702–712. https://doi.org/10.1111/clr.13456

Fretwurst, T., Nelson, K., Tarnow, D. P., Wang, H. L., & Giannobile, W. V. (2018). Is metal particle release associated with Peri-implant bone destruction? An emerging concept. *Journal of Dental Research*, *97*(3), 259–265. https://doi.org/10.1177/0022034517740560

Hashim, D., Cionca, N., Combescure, C., & Mombelli, A. (2018). The diagnosis of peri-implantitis: A systematic review on the predictive value of bleeding on probing. *Clinical Oral Implants Research*, *29*(Suppl 16), 276–293. https://doi.org/10.1111/clr.13127

Heitz-Mayfield, L. J., & Mombelli, A. (2014). The therapy of peri-implantitis: A systematic review. *International Journal of Oral Maxillofacial Implants*, *29*(Suppl), 325–345. https://doi.org/10.11607/jomi.2014suppl.g5.3

Hiyari, S., Wong, R. L., Yaghsezian, A., Naghibi, A., Tetradis, S., Camargo, P. M., & Pirih, F. Q. (2018). Ligature-induced peri-implantitis and periodontitis in mice. *Journal of Clinical Periodontology*, *45*(1), 89–99. https://doi.org/10.1111/jcpe.12817

Ingman, T., Sorsa, T., Suomalainen, K., Halinen, S., Lindy, O., Lauhio, A., … Golub, L. M. (1993). Tetracycline inhibition and the cellular source of collagenase in gingival crevicular fluid in different periodontal diseases. A review article. *Journal of Periodontology*, *64*(2), 82–88. https://doi.org/10.1902/jop.1993.64.2.82

Keeve, P. L., Koo, K. T., Ramanauskaite, A., Romanos, G., Schwarz, F., Sculean, A., & Khoury, F. (2019). Surgical treatment of periimplantitis with non-augmentative techniques. *Implant Dentistry*, *28*(2), 177–186. https://doi.org/10.1097/ID.0000000000000838

Keim, D., Nickles, K., Dannewitz, B., Ratka, C., Eickholz, P., & Petsos, H. (2019). In vitro efficacy of three different implant surface decontamination methods in three different defect configurations. *Clinical Oral Implants Research*, *30*(6), 550–558. https://doi.org/10.1111/clr.13441

Kivelä-Rajamäki, M., Maisi, P., Srinivas, R., Tervahartiala, T., Teronen, O., Husa, V., … Sorsa, T. (2003). Levels and molecular forms of MMP-7 (matrilysin-1) and MMP-8 (collagenase-2) in diseased human peri-implant sulcular fluid. *Journal of Periodontal Research*, *38*(6), 583–590.

Kong, M., Chen, X. G., Xing, K., & Park, H. J. (2010). Antimicrobial properties of chitosan and mode of action: A state of the art review. *International Journal of Food Microbiology*, *144*(1), 51–63. https://doi.org/10.1016/j.ijfoodmicro.2010.09.012

Lang, N. P., Salvi, G. E., & Sculean, A. (2019). Nonsurgical therapy for teeth and implants—When and why? *Periodontology 2000*, *79*(1), 15–21. https://doi.org/10.1111/prd.12240

Larsen, O. I., Enersen, M., Kristoffersen, A. K., Wennerberg, A., Bunæs, D. F., Lie, S. A., & Leknes, K. N. (2017). Antimicrobial effects of three different treatment modalities on dental implant surfaces. *The Journal of Oral Implantology*, *43*(6), 429–436. https://doi.org/10.1563/aaid-joi-D-16-00147

Lee, J. B., Kweon, H. H., Cho, H. J., Kim, C. S., & Kim, Y. T. (2018). Characteristics of local delivery agents for treating peri-implantitis on dental implant surfaces: A preclinical study. *The Journal of Oral Implantology*, *45*, 116–126. https://doi.org/10.1563/aaid-joi-D-17-00261

Liñares, A., Pico, A., Blanco, C., & Blanco, J. (2019). Adjunctive systemic metronidazole to nonsurgical therapy of peri-implantitis with intrabony defects: A retrospective case series study. *International Journal of Oral Maxillofacial Implants*, *34*(5), 1237–1245. https://doi.org/10.11607/jomi.7343

Linkevicius, T., Puisys, A., Vindasiute, E., Linkeviciene, L., & Apse, P. (2013). Does residual cement around implant-supported restorations cause peri-implant disease? A retrospective case analysis. *Clinical Oral Implants Research*, *24*(11), 1179–1184. https://doi.org/10.1111/j.1600-0501.2012.02570.x

Louropoulou, A., Slot, D. E., & Van der Weijden, F. A. (2012). Titanium surface alterations following the use of different mechanical instruments: A systematic review. *Clinical Oral Implants Research*, *23*(6), 643–658. https://doi.org/10.1111/j.1600-0501.2011.02208.x

Machtei, E. E. (2014). Treatment alternatives to negotiate peri-implantitis. *Advances in Medicine*, *2014*, 487903–487913. https://doi.org/10.1155/2014/487903

Mann, M., Parmar, D., Walmsley, A. D., & Lea, S. C. (2012). Effect of plastic-covered ultrasonic scalers on titanium implant surfaces. *Clinical Oral Implants Research*, *23*(1), 76–82. https://doi.org/10.1111/j.1600-0501.2011.02186.x

Mombelli, A., & Lang, N. P. (1992). Antimicrobial treatment of peri-implant infections. *Clinical Oral Implants Research*, *3*(4), 162–168.

Muñoz, V., Duque, A., Giraldo, A., & Manrique, R. (2018). Prevalence of peri-implant disease according to periodontal probing depth and bleeding on probing: A systematic review and meta-analysis. *International Journal of Oral Maxillofacial Implants*, *33*(4), e89–e105. https://doi.org/10.11607/jomi.5940

Nart, J., Pons, R., Valles, C., Esmatges, A., Sanz-Martín, I., & Monje, A. (2019). Non-surgical therapeutic outcomes of peri-implantitis: 12-month results. *Clinical Oral Investigations*, *24*, 675–682. https://doi.org/10.1007/s00784-019-02943-8

Quaranta, A., Lim, Z. W., Tang, J., Perrotti, V., & Leichter, J. (2017). The impact of residual subgingival cement on biological complications around dental implants: A systematic review. *Implant Dentistry*, *26*(3), 465–474. https://doi.org/10.1097/ID.0000000000000593

Rakic, M., Galindo-Moreno, P., Monje, A., Radovanovic, S., Wang, H. L., Cochran, D., … Canullo, L. (2018). How frequent does peri-implantitis occur? A systematic review and meta-analysis. *Clinical Oral Investigations*, *22*(4), 1805–1816. https://doi.org/10.1007/s00784-017-2276-y

Ramanauskaite, A., Becker, K., Juodzbalys, G., & Schwarz, F. (2018). Clinical outcomes following surgical treatment of peri-implantitis at grafted and non-grafted implant sites: A retrospective analysis. *International Journal of Implant Dentistry*, *4*(1), 27. https://doi.org/10.1186/s40729-018-0135-5

Rams, T. E., Degener, J. E., & van Winkelhoff, A. J. (2014). Antibiotic resistance in human peri-implantitis microbiota. *Clinical Oral Implants Research*, *25*(1), 82–90. https://doi.org/10.1111/clr.12160

Renvert, S., Lessem, J., Dahlén, G., Lindahl, C., & Svensson, M. (2006). Topical minocycline microspheres versus topical chlorhexidine gel as an adjunct to mechanical debridement of incipient peri-implant infections: A randomized clinical trial. *Journal of Clinical Periodontology*, *33*(5), 362–369. https://doi.org/10.1111/j.1600-051X.2006.00919.x

Renvert, S., Lessem, J., Dahlén, G., Renvert, H., & Lindahl, C. (2008). Mechanical and repeated antimicrobial therapy using a local drug delivery system in the treatment of peri-implantitis: A randomized clinical trial. *Journal of Periodontology*, *79*(5), 836–844. https://doi.org/10.1902/jop.2008.070347

Roos-Jansåker, A. M., Almhöjd, U. S., & Jansson, H. (2017). Treatment of peri-implantitis: Clinical outcome of chloramine as an adjunctive to non-surgical therapy, a randomized clinical trial. *Clinical Oral Implants Research*, *28*(1), 43–48. https://doi.org/10.1111/clr.12612

Salvi, G. E., Persson, G. R., Heitz-Mayfield, L. J., Frei, M., & Lang, N. P. (2007). Adjunctive local antibiotic therapy in the treatment of peri-implantitis II: Clinical and radiographic outcomes. *Clinical Oral Implants Research*, *18*(3), 281–285. https://doi.org/10.1111/j.1600-0501.2007.01377.x

Silness, J., & Loe, H. (1964). Peridontal disease in pregnancy. II. Correlation between oral hygiene and periodontal condtion. *Acta Odontologica Scandinavica*, *22*, 121–135.

Suárez-López Del Amo, F., Garaicoa-Pazmiño, C., Fretwurst, T., Castilho, R. M., & Squarize, C. H. (2018). Dental implants-associated release of titanium particles: A systematic review. *Clinical Oral Implants Research*, *29*, 1085–1100. https://doi.org/10.1111/clr.13372

Suárez-López Del Amo, F., Yu, S. H., & Wang, H. L. (2016). Non-surgical therapy for peri-implant diseases: A systematic review. *Journal of Oral and Maxillofacial Research*, *7*(3), e13. https://doi.org/10.5037/jomr.2016.7313

Verdugo, F. (2017). Risk of superinfection in peri-implantitis after systemic broad Spectrum antibiotics. *International Journal of Periodontics and Restorative Dentistry*. https://doi.org/10.11607/prd.2546

Vernillo, A. T., Ramamurthy, N. S., Golub, L. M., & Rifkin, B. R. (1994). The nonantimicrobial properties of tetracycline for the treatment of peri-odontal disease. *Current Opinion in Periodontology*, 111–118.

Viganò, P., Apaza Alccayhuaman, K. A., Sakuma, S., Amari, Y., Bengazi, F., & Botticelli, D. (2019). Use of TiBrush for surface decontamination at peri-implantitis sites in dogs: Radiographic and histological outcomes. *Journal of Investigative and Clinical Dentistry*, *10*(1), e12378. https://doi.org/10.1111/jicd.12378

Wohlfahrt, J. C., Aass, A. M., & Koldsland, O. C. (2019). Treatment of peri-implant mucositis with a chitosan brush—A pilot randomized clinical trial. *International Journal of Dental Hygiene*, *17*(2), 170–176. https://doi.org/10.1111/idh.12381

Wohlfahrt, J. C., Evensen, B. J., Zeza, B., Jansson, H., Pilloni, A., Roos-Jansåker, A. M., … Koldsland, O. C. (2017). A novel non-surgical method for mild peri-implantitis—A multicenter consecutive case series. *International Journal of Implant Dentistry*, *3*(1), 38. https://doi.org/10.1186/s40729-017-0098-y

Zeza, B., Wohlfahrt, C., & Pilloni, A. (2017). Chitosan brush for professional removal of plaque in mild peri-implantitis. *Minerva Stomatol*, *66*(4), 163–168. https://doi.org/10.23736/S0026-4970.17.04040-7

How to cite this article: Mayer Y, Ginesin O, Horwitz J. A nonsurgical treatment of peri-implantitis using mechanic, antiseptic and anti-inflammatory treatment: 1 year follow-up. *Clin Exp Dent Res*. 2020;6:478–485. https://doi.org/10.1002/cre2.286

Hyaluronic acid as adjunctive to non-surgical and surgical periodontal therapy: a systematic review and meta-analysis

Meizi Eliezer, Jean-Claude Imber, Anton Sculean, Nikolas Pandis & Sorin Teich

Clinical Oral Investigations

ISSN 1432-6981

Clin Oral Invest
DOI 10.1007/s00784-019-03012-w



Springer

Clinical Oral Investigations
https://doi.org/10.1007/s00784-019-03012-w

REVIEW

Hyaluronic acid as adjunctive to non-surgical and surgical periodontal therapy: a systematic review and meta-analysis

Meizi Eliezer[1] · Jean-Claude Imber[1,2] · Anton Sculean[1] · Nikolas Pandis[3] · Sorin Teich[4]

Received: 24 February 2019 / Accepted: 4 July 2019

Abstract

Objectives To evaluate the potential added benefit of the topical application of hyaluronic acid (HA) on the clinical outcomes following non-surgical or surgical periodontal therapy.

Materials and methods A systematic search was performed in Medline, Embase, Cochrane, Web of Science, Scopus and Grey literature databases. The literature search was preformed according to PRISMA guidelines. The Cochrane risk of bias tool was used in order to assess the methodology of the included trials. Weighted mean differences (WMDs) and 95% confidence intervals (CIs) between the treatment and controls were estimated using the random-effect model for amount of bleeding on probing (BOP), probing depth (PD) reduction and clinical attachment level (CAL) gain. In order to minimize the bias and to perform meta-analysis, only randomized clinical studies (RCTs) were selected.

Results Thirteen RCTs were included: 11 on non-surgical periodontal treatment and two on surgical periodontal treatment. Overall analysis of PD reduction, CAL gain and BOP reduction in non-surgical therapy with adjunctive HA presented WMD of − 0.36 mm (95% CI − 0.54 to − 0.19 mm; $p < 0.0001$), 0.73 mm (95% CI 0.28 to 1.17 mm; $p < 0.0001$) and − 15% (95% CI − 22 to − 8%; $p < 0.001$) respectively, favouring the application of HA. The overall analysis on PD and CAL gain in surgical therapy with adjunctive HA presented WMD of − 0.89 mm (95% CI − 1.42 to − 0.36 mm; $p < 0.0001$) for PD reduction and 0.85 mm (95% CI 0.08 to 1.62 mm; $p < 0.0001$) for CAL gain after 6–24 months favouring the treatment with HA. However, comparison presented considerable heterogeneity between the non-surgical studies and a high risk of bias in general.

Conclusions Within their limits, the present data indicate that the topical application of HA may lead to additional clinical benefits when used as an adjunctive to non-surgical and surgical periodontal therapy. However, due to the high risk of bias and heterogeneity, there is a need for further well-designed RCTs to evaluate this material in various clinical scenarios.

Clinical relevance The adjunctive use of HA may improve the clinical outcomes when used in conjunction with non-surgical and surgical periodontal therapy.

Keywords Hyaluronic acid · Hyaluronan · Periodontitis · Surgical periodontal therapy · Non-surgical periodontal therapy

Introduction

Hyaluronic acid (HA) is a major natural carbohydrate component of the extracellular matrix and can be found in the skin, the joints, the eyes and most other organs and tissues including the periodontium. Furthermore, it is present in body fluids like serum, saliva and gingival crevicular fluid and as a component of the soft and hard tissues [1]. In the periodontium, HA is synthesized by HA synthase enzymes present in various cells including fibroblasts and keratinocytes in the gingival and periodontal ligament, cementoblasts and osteoblasts [2, 3].

There is evidence that HA is bacteriostatic [4, 5], fungostatic [6], anti-inflammatory [7], anti-oedematous [8], osteoinductive [7, 9–11] and pro-angiogenetic [12]. These properties suggest

Meizi Eliezer and Jean-Claude Imber contributed equally to this work.

✉ Anton Sculean
anton.sculean@zmk.unibe.ch

[1] Department of Periodontology, University of Bern, Bern, Switzerland

[2] Department of Periodontology and Operative Dentistry, University of Mainz, Mainz, Germany

[3] Department of Orthodontics and Dentofacial Orthopedics, University of Bern, Bern, Switzerland

[4] Medical University of South Carolina, James B. Edwards College of Dental Medicine, Charleston, South Carolina, USA

Published online: 23 July 2019

HA to be an ideal material for wound healing [13]. In animal studies, HA showed promising results for connective tissue [14, 15] and bone repair [16, 17] and it facilitated re-epithelialization, formed a good elasticity of the connective tissue and increased microvascular density when used on full thickness surgical skin wounds. The use of HA on human skin wounds and of skin ulcers resulted in faster reduction of the wound size when compared with the controls [18, 19].

Since HA is a key molecule in inflammation, granulation tissue formation, epithelium formation and tissue remodelling, it was suggested to play also an important role in periodontal wound healing [16, 20].

The above-mentioned effects (anti-inflammatory, anti-oedematous and antibacterial) have also been shown in non-surgical periodontal therapy [21]. It is anticipated that the anti-inflammatory effect is due to the exogenous HA that acts as a scavenger by draining prostaglandins, metalloproteinases and other bioactive molecule [22]. HA has shown a positive effect on the reduction of plaque and sulcus bleeding index in patients with induced gingivitis [23, 24]. In patients with chronic periodontitis, the additional application of HA to non-surgical periodontal treatment (scaling and root planing) resulted in higher clinical improvements in terms of bleeding on probing (BOP) and probing depth (PD) reduction compared with SRP alone [25]. However, other studies have failed to show statistically significant differences in terms of bacterial profile when HA was applied subgingivally as adjunctive to SRP in chronic periodontitis patients [26].

Interestingly, some clinical reports and randomized clinical trials have shown additional benefits in terms of clinical attachment level (CAL) gain and PD reduction following the adjunctive use of HA during periodontal surgery [27–29].

Most recently, one systematic review [25], however without meta-analysis, concluded that the use of HA adjunctive to SRP and to periodontal surgery yielded positive effects on the clinical outcomes (i.e. PD, CAL, BOP and bone fill). According to the best of our knowledge, at present, no meta-analysis has been published on the effects of HA when applied in the frame on non-surgical and surgical periodontal therapy. Therefore, the aim of this systematic review including meta-analysis was to evaluate the potential clinical effects of HA when used in conjunction with non-surgical and surgical periodontal therapy.

Objectives

This systematic review had the following aims:

1. To evaluate the effect of HA application on clinical parameters in conjunction with non-surgical periodontal therapy.
2. To evaluate the effect of HA application on clinical parameters as adjunctive therapy to periodontal surgery.

The PICOS (Participants, Interventions, Comparisons, Outcomes, Study Designs) research question addressing the research objectives is presented in Table 1 [30].

Materials and methods

Search method and identification of studies

Studies reporting application of HA as adjunctive to periodontal non-surgical and surgical therapies were identified by electronically searching PubMed (NCBI), Embase, Cochrane, Web of Science, Scopus and Grey literature database (www.greynet.org, https://scholar.google.ch/, www.worldcat.org) from the earliest available date through April 2016. The search strategy used was a combination of MeSH terms and/or free text words, depending on the literature database. The key words used for electronic search were "periodontics" (MeSH) OR "periodontal disease" (MeSH) OR "periodontitis" (MeSH) AND "surgical procedures, operative" (MeSH) OR "periodontal therapy" (MeSH) AND "hyaluronic acid" (MeSH) OR "hyaluronan" OR "hyaluronate" (full search strategy: Appendix 1). Hand searching of eligible article references was also performed.

Two authors (J.C.I. and M.E.) selected and evaluated independently the articles during the entire selection process, and any disagreements between authors were resolved after discussion. If information within a study should be missing, the authors would be contacted per email.

Table 1 PICOS (Participants, Interventions, Comparisons, Outcomes, Study Designs)

Participants	Chronic periodontitis patients and healthy adults
Interventions	Application of hyaluronic acid in conjunction with periodontal therapy (either surgical or non-surgical)
Comparisons	Same periodontal procedure (either surgical or non-surgical) without hyaluronic acid
Outcomes	Clinical periodontal parameters (periodontal probing depth, BOP, clinical attachment gain)
Study designs	Randomized control trials in a parallel or split-mouth design

Inclusion criteria

The study inclusion criteria were as follows:

1. Study design—randomized controlled trials (parallel- or split-mouth design).
2. English language.
3. No year restriction.
4. Studies reporting application of HA as adjunctive to non-surgical and surgical periodontal therapy.
5. No combinations with biomaterials (e.g. bone substitute, membranes).
6. Minimum 3-month follow-up period for non-surgical treatment and minimum 6-month follow-up period for surgical treatment.
7. Studies reporting either on PD, CAL or BOP as outcomes.

Type of outcome measurements

The primary outcomes were changes in PD, CAL and BOP reported at different time points.

Data collection

The following data from each study were extracted and entered into an electronic spreadsheet:

Name of the authors, year of publication, total number of participants, total amount of treated sites, months of follow-up, BOP, PD, CAL and study design.

Risk of bias (quality) assessment

The Cochrane risk of bias tool [31] was used in order to assess the methodology of the included trials. Two authors (M.E., J.C.I.) independently assessed risk of bias on the following criteria:

1. Random sequence generation.
2. Allocation concealment.
3. Blinding of participants and the investigator.
4. Blinding of outcome assessments.
5. Incomplete outcome data.
6. Selective outcome reporting.
7. Other bias.

Each relevant domain per trail was judged either as low risk (if all criteria were met), unclear risk (only one criterion was missing) or high risk (two or more criteria were missing). As a proxy to publication bias, a funnel plot and the Egger tests were applied only for non-surgical studies outcome on PD, which was considered in ten trials. For the other outcomes and the surgical studies, publication bias could not be assessed because there were fewer than ten included studies.

Data analysis

The treatment outcomes used in the meta-analysis were changes in PD, CAL and BOP from baseline and at 3 months after periodontal pockets were treated by non-surgical therapy. For surgical therapy, only PD and CAL changes were assessed after a follow-up period of at least 6 months.

A correlation coefficient of 0.5 was used in order to calculate the standard deviations (SDs) of the mean difference of the before and after outcome changes. Weighted mean differences (WMDs) and 95% confidence intervals (CIs) between the treatment and controls were estimated using the random-effect model for the continuous outcome amount of BOP, PD reduction and CAL gain. For studies providing only the interquartile ranges (ICRs), the SD was estimated by dividing the ICR by 1.35 [31].

Results were presented as forest plots with weighted means and 95% CIs. Heterogeneity across studies was evaluated using I^2 statistic ($I^2 \geq 50\%$ denoting substantial heterogeneity). All statistical analyses were conducted using the "metan" family of commands in Stata 14.2 (Stata Corp, College Station, TX, USA). Statistical significance was set at $p < 0.05$.

The alternative research hypothesis of this study was that there are differences in the treatment outcomes between the intervention group (with HA) and the control group (without HA).

Results

Search results

A total of 438 studies were identified in six databases. After elimination of duplicates, 261 studies could be assessed. Two hundred forty-three studies had to be excluded in the process of title and abstract reading. Those studies were case series, written in a language other than English, had not an appropriate follow-up or used a combination with other biomaterials (e.g. membranes, bone substitutes). Eighteen full-text publications were further assessed for eligibility. After full eligibility assessment, five studies and the surgical part of one study were excluded (Table 2) and 13 studies were included in this review (search flow diagram: Fig. 1). Among the included studies, 11 clinical trials reported on the effect of HA in non-surgical therapy (scaling and root planing) in patients with chronic periodontitis [26, 32–41] (Table 3), and two studies reported on the effect of HA as adjunct to surgical periodontal therapy [27, 28] (Table 4). The surgical studies compared either flap surgery alone or flap surgery with HA delivery into intrabony defects.

Table 2 Excluded studies and reason for exclusion

Author	Reason for exclusion
Engström et al. (2001)	Only the surgical part was excluded—using a combination of a membrane and HA
Kaira et al. (2015)	Case report + combination of HA with amnion membrane
Mesa et al. (2002)	Study focused on effect of an HA gel on cell proliferation and inflammation
Pilloni et al. (2011)	Not patients with chronic periodontitis
Sandhu et al. (2015)	Case report + combination of HA with platelet-rich fibrin
Xi et al. (2014)	Language (Chinese)

Results of meta-analyses for non-surgical therapy

CAL gain

Nine studies [26, 32–34, 36, 37, 40, 41] reported data on CAL gain for sites treated with scaling and root planing either with or without the adjuvant use of HA after 3 months. Overall, the WMD was 0.73 mm (95% CI 0.28 to 1.17 mm; $p < 0.0001$), favouring the addition of HA. However, considerable heterogeneity was identified among studies (chi-squared test $p < 0.0001$) (Fig. 2).

PD reduction

Eight studies [26, 32–34, 36–38, 41] reported data on PD reduction for sites treated with the use of HA versus a control group without. The WMD of the eight studies was −0.36 mm (95% CI −0.54 to −0.19 mm; $p < 0.0001$), favouring the treatment with HA. Considerable heterogeneity was identified among studies (chi-squared test $p < 0.0001$) (Fig. 3).

BOP reduction

Five studies [26, 32, 34, 37, 41] reported data on BOP reduction in percentage of sites treated with HA versus a control group. Overall, the WMD was −15% (95% CI −22 to −8%; $p < 0.001$), favouring the treatment. Despite, considerable heterogeneity was identified among studies (chi-squared test $p < 0.0001$) (Fig. 4).

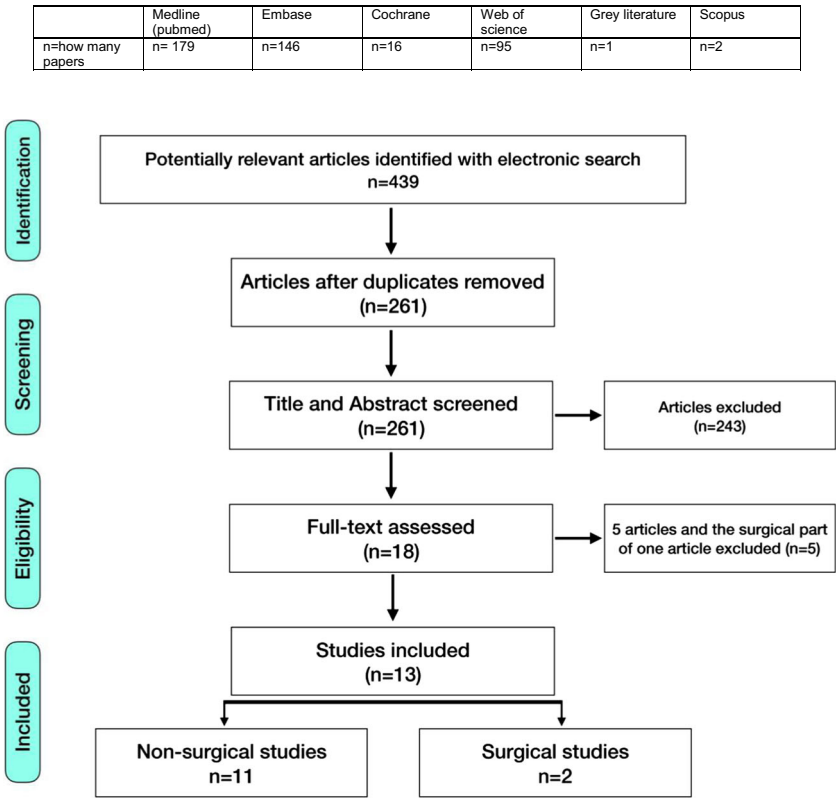

Fig. 1 Flow diagram describing the search and study inclusion process

Table 3 Characteristics of included studies—non-surgical therapy

Author (year)	Study design	Participants Control/test	Clinical parameters Control/test	Intervention	Follow-up	Outcomes	Site and funding
Bevilacqua (2012)	Split mouth	11 individuals	Average BOP (%) 72.7 72.7 Average PD (mm) 6.36 (5.86–6.87) 6.14 (5.7–6.58) Average CAL (mm) 5.91 (5–6.83) 5.91 (5–6.84)	1. SRP + placebo 2. SRP + HA	45 days 90 days	PD, CAL, BOP, PI	University, industry
Chauhan (2013)	Parallel groups	40 individuals 20/20	Average CAL (mm) 6.10 ± 0.38 6.13 ± 0.54 Average PD (mm) 5.93 ± 0.6 5.90 ± 0.27	1. SRP 2. SRP + HA	3 months	PD, CAL, GI, PI	University, industry
Eick (2013)	Parallel groups	34 individuals 17/17	Average PD (mm) 4.1 ± 0.4 mm 4.2 ± 0.4 mm Average BOP (%) 18.8 ± 11.1 mm 16.3 ± 8.7 mm Average CAL (mm) 5.7 ± 0.6 mm 5.5 ± 0.9 mm	1. SRP 2. SRP + HA + 2*d HA rinsing for 2 weeks	3 + 6 months	BOP, PI, CAL, PD	University, industry
Engström (2001)	Split mouth	9 individuals	Average PD (mm) 6.8 ± 1.5 6.4 ± 1.3	1. SRP 2. SRP + HA (3×)	2 weeks 1 month 3 months 6 months	BOP, PI, PD	University, industry
Gontiya and Galgali (2012)	Parallel groups	26 individuals 13/13	Average PD (mm) 6.42 ± 0.44 6.57 ± 0.45 Average CAL (mm) 8.56 ± 0.41 8.91 ± 0.41	1. SRP 2. SRP + HA (4×)	12 weeks	PD, CAL (RAL), PD	University
Johannsen (2009)	Split mouth	12 individuals	Average BOP (%) 58 (26) 74.5 (45.7) (IQR) Average CAL (mm) 4.5 (4.2–4.7) 4.4 (4.1–4.8) Average PD (mm) 4.2 (3.6–4.7) 4.2 (3.7–4.7)	1. SRP 2. SRP + HA (2×)	12 weeks	BOP, PI, CAL, PD	University, industry

Table 3 (continued)

Author (year)	Study design	Participants Control/test	Clinical parameters Control/test	Intervention	Follow-up	Outcomes	Site and funding
Koshal (2012)	Split mouth	52 individuals	Average PD (mm) 3.90 ± 0.93 3.82 ± 0.78	1. SRP + placebo 2. SRP + HA	3 months	GI, PD	University, industry
Polepalle (2015)	Split mouth	18 Individuals	Average PD (mm) 5.21 ± 0.54 4.99 ± 0.34 Average CAL (mm) 5.41 ± 0.65 5.40 ± 0.71	1. SRP 2. SRP + HA (2×)	12 weeks	GI, PI, PD, CAL	University
Rajan (2014)	Split mouth	33 individuals	Average PD (mm) 6.09 ± 1.26 6.33 ± 0.99 Average CAL (mm) 9.12 ± 1.67 10.18 ± 2.08	1. SRP 2. SRP + HA (2×)	4 weeks 12 weeks	GI, PI, PD, CAL	University
Wan (2004)	Parallel groups	56 individuals 28/28	Average BOP (%) 67.4% ± 21.2 71.3% ± 16.8 Average PD (mm) 2.5 ± 0.7 2.4 ± 0.5 Average PAL (mm) 12.7 ± 2.6 12.3 ± 2.2	1. SRP + placebo 2. SRP + HA (2×)	1 month 3 months	BOP, PI, PD, CAL (PAL)	University, industry
Xu (2004)	Split mouth	20 individuals	Average PD (mm) 5.2 ± 1.62 5.3 ± 1.61 Average CAL (mm) 5.4 ± 1.97 5.5 ± 1.79 Average BOP (mm) 72% 78%	1. SRP 2. SRP + HA (6×)	6 weeks 12 weeks	BOP, CAL, PD	Grant (German Academic Exchange Service), university

BOP bleeding on probing, *PD* probing depth, *CAL* clinical attachment level, *PI* plaque index, *HA* hyaluronic acid, *SRP* scaling and root planing, *GI* gingival index, *RAL* relative attachment level, *PAL* probing attachment level, *IQR* interquartile range

Table 4 Characteristics of included studies—surgical therapy

Author (year)	Study design	Participants Control/test	Clinical parameters Control/test	Intervention	Follow-up	Outcomes	Site and funding
Briguglio (2013)	Parallel groups	40 individuals 20/20	Average PD 8.0 ± 0.7 8.6 ± 1.5 Average CAL 8.3 ± 1.2 7.2 ± 1.5	1. IBD + EDTA 2. IBD + EDTA + HA	12 months 24 months	PD, CAL, BOP, PI	University
Fawzy El-Sayed (2012)	Split mouth	14 individuals 2 teeth per site	Average CAL 5.50 (5.00/8.00) 5.50 (2.00/7.00) (IQR) Average PD 5.00 (5.00/6.00) 5.00 (5.00/6.00) (IQR)	1. IBD 2. IBD + HA	3 months 6 months	CAL, GR, PD, GI, PI	Funded by the first author

BOP bleeding on probing, *PD* probing depth, *CAL* clinical attachment level, *PI* plaque index, *GI* gingival index, *HA* hyaluronic acid, *GR* gingival recessions, *IBD* intrabony defect, *EDTA* ethylenediaminetetraacetic acid, *IQR* interquartile range

Results of meta-analyses for surgical therapy

CAL gain

Two studies reported data on CAL gain for sites treated with HA versus a control group at 6 months and 24 months [27, 28]. The WMD was 0.85 mm (95% CI 0.08 to 1.62 mm; $p < 0.0001$), favouring the treatment. A low heterogeneity among studies was observed (chi-squared test $p = 0.822$) (Fig. 5).

PD reduction

Two studies [27, 28] reported data on PD reduction for sites treated with HA versus a control group at 6 months and 24 months. Overall, the WMD was − 0.89 mm (95% CI − 1.42 to − 0.36 mm; $p < 0.0001$), favouring the adjunctive use of HA. Furthermore, the comparison presented low heterogeneity among the two studies (chi-squared test $p = 0.714$) (Fig. 6).

BOP reduction

BOP was not measured in the included studies. Therefore, there are no results for BOP reduction in surgical therapy.

Results of risk of bias assessment

Results of the risk of bias assessment for the included RCTs are summarized in Table 5. Only three studies were

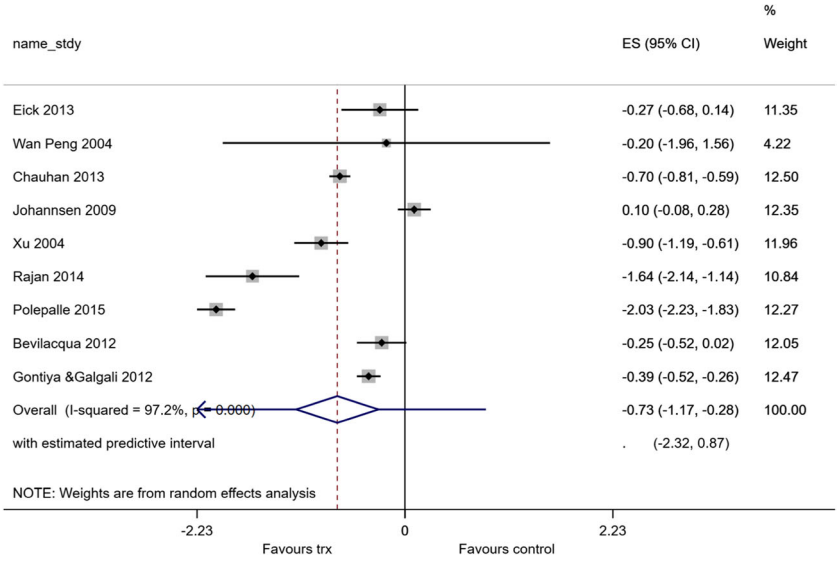

Fig. 2 Forest plots for CAL gain following non-surgical therapy after 3 months

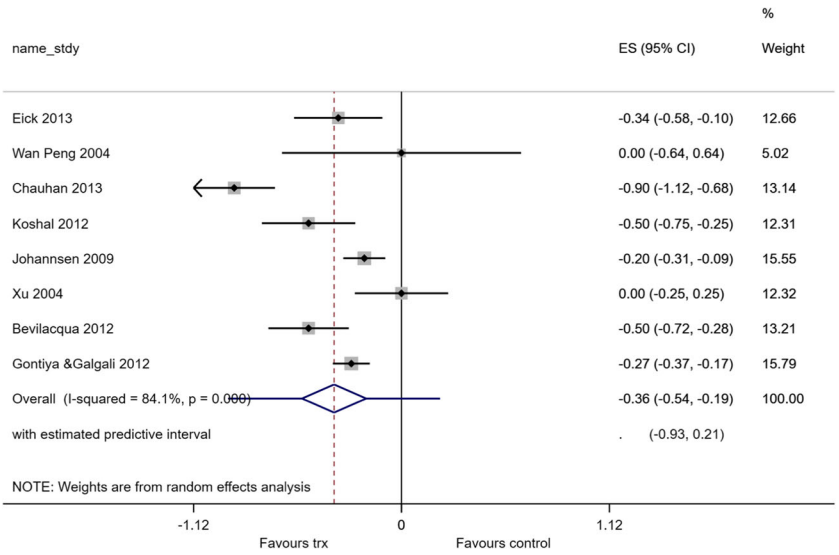

Fig. 3 Forest plot for PD reduction following non-surgical therapy after 3 months

assessed at low risk of bias while 11 studies were determined to be at high risk.

Publication bias

The Egger test was not significant suggesting that there was no evidence for small study effects. The funnel plot is asymmetric; however, it is difficult to assess whether this is due to publication bias as a number of reasons could be the reason for this asymmetry [42] (Fig. 1).

Discussion

The present systematic review including meta-analysis has evaluated the potential additional effects of local application of HA on the clinical outcomes of non-surgical and surgical periodontal therapy.

Thirteen RCTs fulfilled the inclusion criteria with adequate follow-up (3 months for non-surgical treatment and more than 6 months for surgical treatment).

Eleven RCTs have evaluated the effectiveness of HA adjunctively to non-surgical treatment on chronic periodontitis patients. Six out of the 11 studies were performed in a split-mouth design and five in a parallel group design. The application frequency of the different HA-containing products differed between the studies from one application during scaling and root planing to a repeated application during scaling and root planing and additional weekly applications up to 6 weeks.

The meta-analysis revealed that non-surgical treatment with adjunctive HA resulted in additional PD reduction (mean − 0.36 mm), CAL gain (mean 0.73 mm) and BOP reduction (mean − 15%) compared with conventional scaling and root

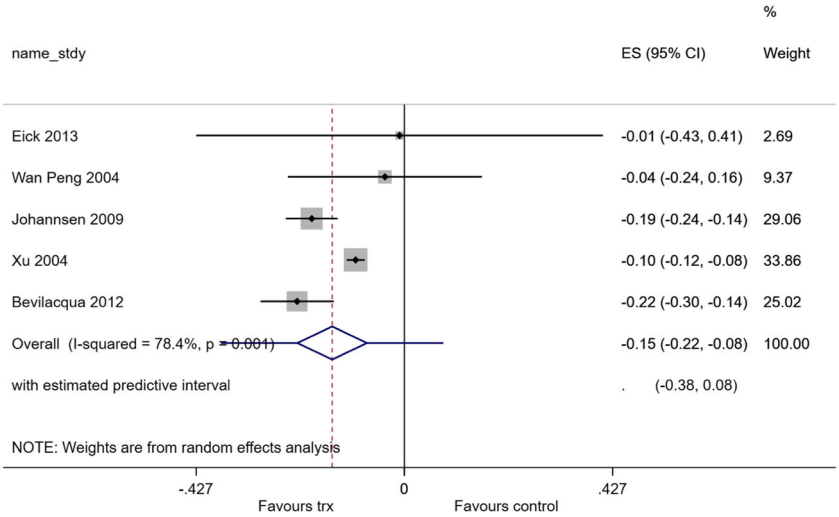

Fig. 4 Forest plot for BOP reduction following non-surgical therapy after 3 months

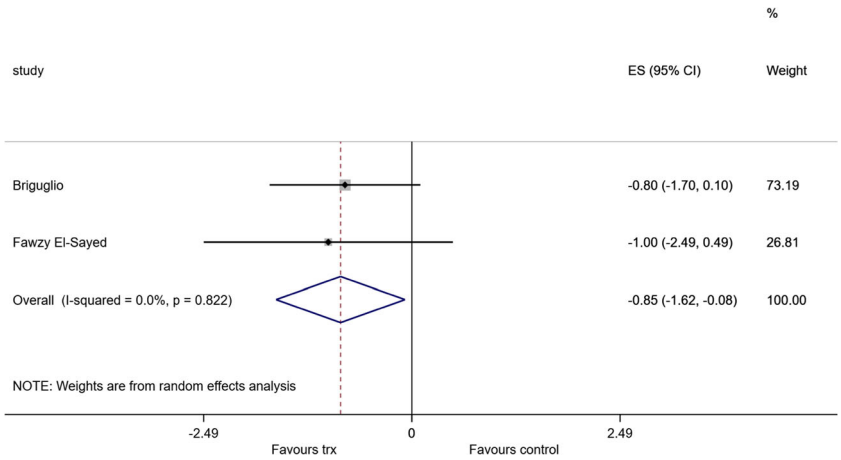

Fig. 5 Forest plot for CAL gain following surgical therapy after 6–24 months

planing after 3 months. If we are looking at results of a recently published systematic review [43] about additional CAL gain with different adjuncts compared with scaling and root planing alone (0.35 mm with systemic antimicrobials, PDT diode laser 0.53 mm, chlorhexidine chips 0.40 mm), HA could represent a suitable alternative to the most frequently used adjuvants. Nevertheless, there was an overall high risk of bias and a high heterogeneity among the studies.

The heterogeneity among the studies may be attributed to differences in the treatment protocol and the different types of products used. All the products contained high molecular weight HA with a concentration from 0.2 to 0.8%. It needs to be kept in mind that the most appropriate protocol, product and concentration for the clinical application of HA are still unknown. Moreover, in the included studies, there are different time points and different number of applications. Additionally, it is still unknown which formulation of HA (i.e. cross-linked or non-cross-linked) will give the best clinical result [44].

Two RCTs have evaluated the effectiveness of HA as an adjunctive to surgical treatment (open flap debridement (OFD)) in chronic periodontitis patients. One study was conducted as a split-mouth study and one with a parallel group design. In both studies, intrabony defects were treated with either OFD + HA (test) or OFD (control). The results have shown that after 6–24 months, the adjunctive application of HA yielded statistically significantly higher clinical improvements evidenced by PD reduction and CAL gain compared with OFD alone thus suggesting that HA has an added beneficial effect when used as an adjunct to periodontal surgery [27, 28]. It is generally accepted that angular bony defects, when left untreated, will worsen/progress over time, eventually leading to tooth loss [45]. The results of the present meta-analysis indicate that the use of HA in conjunction with OFD may provide an added clinical benefit evidenced by a further reduction in PD and gain of CAL gain in intrabony defects compared with OFD alone.

The added clinical improvements shown in the present meta-analysis are in line with the results from several preclinical and clinical studies. A case series of surgical periodontal therapy in conjunction with HA and autologous bone revealed good clinical outcome without the use of a membrane [46]. Furthermore, another case series showing promising results in intrabony defect treated with HA in conjunction with OFD

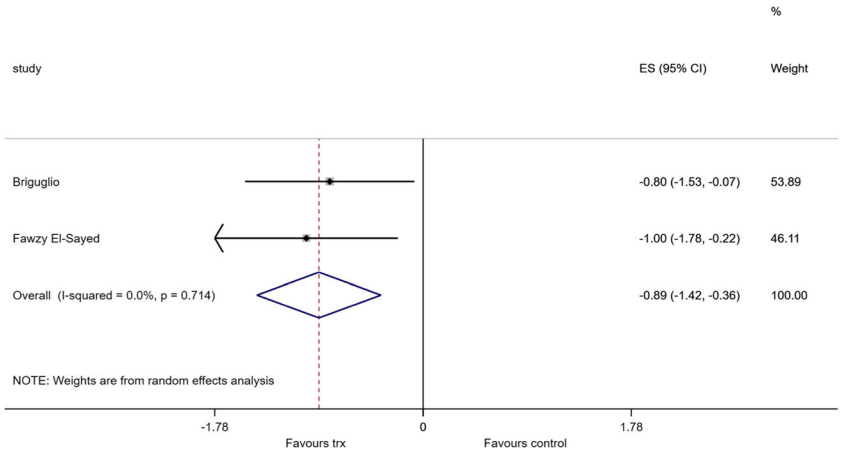

Fig. 6 Forest plot for PD reduction following surgical therapy after 6–24 months

Table 5 Results of quality assessment

	Random sequence generation (selection bias)	Allocation concealment (selection bias)	Blinding of participants and personnel (performance bias)	Blinding of outcome assessments (detection bias)	Incomplete outcome data (attrition bias)	Selective outcome reporting (reporting bias)	Other bias	General risk assessment
Bevilacqua (2012)	+	+	+	+	+	+	+	Low
Chauhan (2013)	+	+	−	?	+	+	−	High
Eick (2013)	+	+	−	+	−	+	?	High
Engström (2012)	+	+	−	+	−	+	?	High
Gontiya and Galgali (2012)	+	+	?	?	+	+	?	High
Johannsen (2009)	+	+	−	?	+	+	?	High
Polepalle (2015)	+	+	−	?	+	+	?	High
Rajan (2014)	+	?	+	+	?	?	?	High
Wan (2004)	+	+	+	+	+	+	+	Low
Xu (2004)	+	+	−	−	+	+	?	High
Kohal (2012)	+	−	+	−	+	+	?	High
Briguglio (2013)	+	+	+	+	+	+	+	Low
Fawzy El-Sayed (2012)	+	+	−	?	+	+	?	High

'+' = low risk; '?' = unclear risk; '-' = high risk

[29]. HA has shown to increase osteoblast activity by stimulating differentiation and migration of mesenchymal cells [6] and accelerate bone formation in a rabbit model [47]. Kim et al. reported that HA improved wound healing and bone formation in hemisectioned-performed extraction sockets with communication to periodontal lesions in a canine model [48].

Taken together, the positive outcomes reported in preclinical and clinical studies corroborate the results of the present meta-analysis and lend additional support to the capacity of HA to improve wound healing. Findings from medical field have shown that HA possesses a number of properties that are relevant in wound healing such as stabilizing the blot clot, lowering the inflammatory response, helping in neovascularization and angiogenesis and accelerating fibroblast migration and wound closure [49, 50].

The above-mentioned positive biologic effects of HA are also supported by the results of a recently published preclinical (i.e. in vitro) study which have demonstrated that HA enhanced expression of genes encoding type III collagen and transforming growth factor-β3, characteristic of scarless wound healing [44]. The application of HAs upregulated the expression of genes encoding proproliferative, pro-migratory and pro-inflammatory factors in palatal and gingival fibroblasts while in palatal but not gingival fibroblasts, an indirect effect of HA on the expression of matrix metalloproteinases 2 and 3 was detected. Taken together, these preclinical data provide further support on the effects of HA to enhance the proliferative, migratory and wound-healing properties of cell types involved in periodontal wound healing/regeneration.

When discussing the role of HA on wound healing, it needs to be also pointed to the findings of a preclinical study in dogs, which have failed to show an advantage of using HA in periodontal surgery [51]. Following the application of HA in surgically created class III furcation defects, the histological analysis did not reveal any substantial formation of root cementum, periodontal ligament and bone. However, these negative findings are most likely due to the low regenerative potential of class III furcation defects [52].

It has also to be realized that the present systematic review and meta-analysis has a number of limitations, and therefore, the results need to be interpreted with caution. First of all, there is a significant heterogeneity

between the studies evaluating HA in non-surgical periodontal therapy due to study design, treatment time points, products and outcome assessments. Second, out of 13 RCTs evaluating the effects of HA in conjunction with surgical periodontal therapy, only two studies fulfilled the inclusion criteria (i.e. 11 had a high risk or unclear risk of bias), and thus, there is a need for well-designed, controlled clinical studies evaluating this material in conjunction with periodontal surgery.

Obviously, due to an overall high risk of bias and heterogeneity among the studies, there is a need for future well-designed RCTs to justify the benefits of using HA for non-surgical periodontal treatment. Last but not least, an appropriate protocol and the most adequate formulation of HA for clinical applications need to be tested and further evaluated.

Conclusion

Within their limits, the present data indicate that the topical application of HA may lead to additional clinical benefits when used as an adjunctive to non-surgical and surgical periodontal therapy. However, due to the high risk of bias and heterogeneity, there is a need for further well-designed RCTs to evaluate this material in various clinical scenarios.

Funding The work was supported by the authors' own institutions.

Compliance with ethical standards

Conflict of interest The authors declare that they have no conflict of interest.

Ethical approval This article does not contain any studies with human participants or animals performed by any of the authors.

Informed consent For this type of study (e.g. systematic review and meta-analysis), formal consent is not required.

Appendix 1 Full searching strategy

((“periodontics” [MeSH Terms] OR “periodontics” [All Fields] OR “periodontology” [All Fields]) OR (“periodontitis” [MeSH Terms] OR “periodontitis” [All Fields]) OR (“periodontal diseases” [MeSH Terms] OR “periodontal” [All Fields] AND “diseases” [All Fields]) OR “periodontal diseases” [All Fields] OR (“periodontal” [All Fields] AND “disease” [All Fields]) OR (“periodontal disease” [All Fields] OR “periodontal pocket” [MeSH Terms]) OR (“periodontal” [All Fields] AND “pocket” [All Fields]) OR (“periodontal pocket” [All Fields]) OR (furcation [All Fields] AND (“therapy” [Subheading] OR “therapy” [All Fields] OR “therapeutics” [MeSH Terms] OR “therapeutics” [All Fields])) OR (intrabony [All Fields] AND defect [All Fields]) OR (infrabony [All Fields] AND defect [All Fields]) OR (intraosseous [All Fields] AND defect [All Fields]) OR (periodontal [All Fields] AND (“surgery” [Subheading] OR “surgery” [All Fields] OR “surgical procedures, operative” [MeSH Terms] OR (“surgical” [All Fields] AND “procedures” [All Fields] AND “operative” [All Fields]) OR “operative surgical procedures” [All Fields] OR “surgery” [All Fields] OR “general surgery” [MeSH Terms] OR (“general” [All Fields] AND “surgery” [All Fields]) OR “general surgery” [All Fields])) OR (periodontal [All Fields] AND (“therapy” [Subheading] OR “therapy” [All Fields] OR “therapeutics” [MeSH Terms] OR “therapeutics” [All Fields])) OR (periodontal [All Fields] AND (“regeneration” [MeSH Terms] OR “regeneration” [All Fields]))) AND (hyaluron [All Fields] OR (“hyaluronic acid” [MeSH Terms] OR (“hyaluronic” [All Fields] AND “acid” [All Fields]) OR “hyaluronic acid” [All Fields]) OR (“hyaluronic acid” [MeSH Terms] OR (“hyaluronic” [All Fields] AND “acid” [All Fields]) OR “hyaluronic acid” [All Fields] OR “hyaluronan” [All Fields]) OR (“hyaluronic acid” [MeSH Terms] OR (“hyaluronic” [All Fields] AND “acid” [All Fields]) OR “hyaluronic acid” [All Fields] OR “hyaluronate” [All Fields]))

References

1. Fraser JR, Laurent TC, Laurent UB (1997) Hyaluronan: its nature, distribution, functions and turnover. J Intern Med 242(1):27–33
2. Ijuin C, Ohno S, Tanimoto K, Honda K, Tanne K (2001) Regulation of hyaluronan synthase gene expression in human periodontal ligament cells by tumour necrosis factor-alpha, interleukin-1beta and interferon-gamma. Arch Oral Biol 46(8):767–772
3. Laurent TC (1998) The chemistry, biology, and medical applications of hyaluronan and its derivatives, Wenner-Gren international series, vol 72. Portland Press, London
4. Carlson GA, Dragoo JL, Samimi B, Bruckner DA, Bernard GW, Hedrick M, Benhaim P (2004) Bacteriostatic properties of biomatrices against common orthopaedic pathogens. Biochem Biophys Res Commun 321(2):472–478. https://doi.org/10.1016/j.bbrc.2004.06.165
5. Pirnazar P, Wolinsky L, Nachnani S, Haake S, Pilloni A, Bernard GW (1999) Bacteriostatic effects of hyaluronic acid. J Periodontol 70(4):370–374. https://doi.org/10.1902/jop.1999.70.4.370
6. Kang JH, Kim YY, Chang JY, Kho HS (2011) Influences of hyaluronic acid on the anticandidal activities of lysozyme and the peroxidase system. Oral Dis 17(6):577–583. https://doi.org/10.1111/j.1601-0825.2011.01807.x
7. Sasaki T, Watanabe C (1995) Stimulation of osteoinduction in bone wound healing by high-molecular hyaluronic acid. Bone 16(1):9–15
8. Dahiya P, Kamal R (2013) Hyaluronic acid: a boon in periodontal therapy. N Am J Med Sci 5(5):309–315. https://doi.org/10.4103/1947-2714.112473
9. de Brito BB, Mendes Brazao MA, de Campos ML, Casati MZ, Sallum EA, Sallum AW (2012) Association of hyaluronic acid with a collagen scaffold may improve bone healing in critical-size bone

defects. Clin Oral Implants Res 23(8):938–942. https://doi.org/10.1111/j.1600-0501.2011.02234.x
10. Kawano M, Ariyoshi W, Iwanaga K, Okinaga T, Habu M, Yoshioka I, Tominaga K, Nishihara T (2011) Mechanism involved in enhancement of osteoblast differentiation by hyaluronic acid. Biochem Biophys Res Commun 405(4):575–580. https://doi.org/10.1016/j.bbrc.2011.01.071
11. Mendes RM, Silva GA, Lima MF, Calliari MV, Almeida AP, Alves JB, Ferreira AJ (2008) Sodium hyaluronate accelerates the healing process in tooth sockets of rats. Arch Oral Biol 53(12):1155–1162. https://doi.org/10.1016/j.archoralbio.2008.07.001
12. Deed R, Rooney P, Kumar P, Norton JD, Smith J, Freemont AJ, Kumar S (1997) Early-response gene signalling is induced by angiogenic oligosaccharides of hyaluronan in endothelial cells. Inhibition by non-angiogenic, high-molecular-weight hyaluronan. Int J Cancer 71(2):251–256
13. Croce MA, Dyne K, Boraldi F, Quaglino D Jr, Cetta G, Tiozzo R, Pasquali Ronchetti I (2001) Hyaluronan affects protein and collagen synthesis by in vitro human skin fibroblasts. Tissue Cell 33(4):326–331. https://doi.org/10.1054/tice.2001.0180
14. Oryan A, Moshiri A, Meimandi Parizi AH, Raayat Jahromi A (2012) Repeated administration of exogenous sodium-hyaluronate improved tendon healing in an in vivo transection model. J Tissue Viability 21(3):88–102. https://doi.org/10.1016/j.jtv.2012.06.002
15. Tuncay I, Ozbek H, Atik B, Ozen S, Akpinar F (2002) Effects of hyaluronic acid on postoperative adhesion of tendo calcaneus surgery: an experimental study in rats. J Foot Ankle Surg 41(2):104–108
16. Chen WY, Abatangelo G (1999) Functions of hyaluronan in wound repair. 7(2):79–89
17. Zanchetta P, Lagarde N, Uguen A, Marcorelles P (2012) Mixture of hyaluronic acid, chondroitin 6 sulphate and dermatan sulphate used to completely regenerate bone in rat critical size defect model. J Craniomaxillofac Surg 40(8):783–787. https://doi.org/10.1016/j.jcms.2012.02.011
18. Juhasz I, Zoltan P, Erdei I (2012) Treatment of partial thickness burns with Zn-hyaluronan: lessons of a clinical pilot study. Ann Burns Fire Disasters 25(2):82–85
19. Humbert P, Mikosinki J, Benchikhi H, Allaert FA (2013) Efficacy and safety of a gauze pad containing hyaluronic acid in treatment of leg ulcers of venous or mixed origin: a double-blind, randomised, controlled trial. Int Wound J 10(2):159–166. https://doi.org/10.1111/j.1742-481X.2012.00957.x
20. Bertolami CN, Messadi DV (1994) The role of proteoglycans in hard and soft tissue repair. Crit Rev Oral Biol Med 5(3–4):311–337
21. Pagnacco A, Vangelisti R, Erra C, Poma A (1997) Double blind clinical trial Vs. placebo of a new sodium hyaluronate-based gingival gel. Attual Ter In 15(1)
22. Bansal J, Kedige SD, Anand S (2010) Hyaluronic acid: a promising mediator for periodontal regeneration. Indian J Dent Res 21(4):575–578. https://doi.org/10.4103/0970-9290.74232
23. Jentsch H, Pomowski R, Kundt G, Gocke R (2003) Treatment of gingivitis with hyaluronan. J Clin Periodontol 30(2):159–164
24. Pistorius A, Martin M, Willershausen B, Rockmann P (2005) The clinical application of hyaluronic acid in gingivitis therapy. Quintessence Int 36(7–8):531–538
25. Bertl K, Bruckmann C, Isberg PE, Klinge B, Gotfredsen K, Stavropoulos A (2015) Hyaluronan in non-surgical and surgical periodontal therapy: a systematic review. J Clin Periodontol 42(3):236–246. https://doi.org/10.1111/jcpe.12371
26. Xu Y, Hofling K, Fimmers R, Frentzen M, Jervoe-Storm PM (2004) Clinical and microbiological effects of topical subgingival application of hyaluronic acid gel adjunctive to scaling and root planing in the treatment of chronic periodontitis. J Periodontol 75(8):1114–1118. https://doi.org/10.1902/jop.2004.75.8.1114
27. Briguglio F, Briguglio E, Briguglio R, Cafiero C, Isola G (2013) Treatment of infrabony periodontal defects using a resorbable biopolymer of hyaluronic acid: a randomized clinical trial. Quintessence Int 44(3):231–240. https://doi.org/10.3290/j.qi.a29054
28. Fawzy El-Sayed KM, Dahaba MA, Aboul-Ela S, Darhous MS (2012) Local application of hyaluronan gel in conjunction with periodontal surgery: a randomized controlled trial. Clin Oral Investig 16(4):1229–1236. https://doi.org/10.1007/s00784-011-0630-z
29. Vanden Bogaerde L (2009) Treatment of infrabony periodontal defects with esterified hyaluronic acid: clinical report of 19 consecutive lesions. Int J Periodontics Restorative Dent 29(3):315–323
30. Moher D, Liberati A, Tetzlaff J, Altman DG (2009) Preferred reporting items for systematic reviews and meta-analyses: the PRISMA statement. Ann Intern Med 151(4):264–269 w264
31. Higgins JPT, Altman DG, Sterne JAC (2011) Chapter 8: assessing risk of bias in included studies. Cochrane handbook for systematic reviews of interventions Version 5.1.0 [updated March 2011]. Available from http://www.cochrane-handbook.org/
32. Bevilacqua L, Eriani J, Serroni I, Liani G, Borelli V, Castronovo G, Di Lenarda R (2012) Effectiveness of adjunctive subgingival administration of amino acids and sodium hyaluronate gel on clinical and immunological parameters in the treatment of chronic periodontitis. Ann Stomatol 3(2):75–81
33. Chauhan A, Bains V, Gupta V, Singh G, Patil S (2013) Comparative analysis of hyaluronan gel and xanthan-based chlorhexidine gel, as adjunct to scaling and root planing with scaling and root planing alone in the treatment of chronic periodontitis: a preliminary study. Contemp Clin Dent 4(1):54–61. https://doi.org/10.4103/0976-237x.111619
34. Eick S, Renatus A, Heinicke M, Pfister W, Stratul SI, Jentsch H (2013) Hyaluronic acid as an adjunct after scaling and root planing: a prospective randomized clinical trial. J Periodontol 84(7):941–949. https://doi.org/10.1902/jop.2012.120269
35. Engström PE, Shi XQ, Tronje G, Larsson A, Welander U, Frithiof L, Engstrom GN (2001) The effect of hyaluronan on bone and soft tissue and immune response in wound healing. J Periodontol 72(9):1192–1200. https://doi.org/10.1902/jop.2000.72.9.1192
36. Gontiya G, Galgali S (2012) Effect of hyaluronan on periodontitis: a clinical and histological study. J Indian Soc Periodontol 16(2):184–192. https://doi.org/10.4103/0972-124x.99260
37. Johannsen A, Tellefsen M, Wikesjo U, Johannsen G (2009) Local delivery of hyaluronan as an adjunct to scaling and root planing in the treatment of chronic periodontitis. J Periodontol 80(9):1493–1497. https://doi.org/10.1902/jop.2009.090128
38. Koshal A, Bolt R, Galgut P (2012) A comparison in postoperative healing of sites receiving non-surgical debridement augmented with and without a single application of hyaluronan 0.8% gel. Dental Tribune MEA 10(5):8-9-13
39. Polepalle T, Srinivas M, Swamy N, Aluru S, Chakrapani S, Chowdary B (2015) Local delivery of hyaluronan 0.8% as an adjunct to scaling and root planing in the treatment of chronic periodontitis: a clinical and microbiological study. J Indian Soc Periodontol 19(1):37–42. https://doi.org/10.4103/0972-124x.145807
40. Rajan P, Baramappa R, Rao NM, Pavaluri AK, P I, Rahaman SMU (2014) Hyaluronic acid as an adjunct to scaling and root Planing in chronic periodontitis. A randomized clinical trial. J Clin Diagn Res 8(12):ZC11–ZC14. https://doi.org/10.7860/JCDR/2014/8848.5237
41. Wan P (2004) A clinical trial of local delivery of hyaluronic acid gel as an adjunct to non-surgical treatment of chronic periodontitis. The University of Hong Kong, Pokfulam
42. Sterne JA, Sutton AJ, Ioannidis JP, Terrin N, Jones DR, Lau J, Carpenter J, Rucker G, Harbord RM, Schmid CH, Tetzlaff J, Deeks JJ, Peters J, Macaskill P, Schwarzer G, Duval S, Altman

DG, Moher D, Higgins JP (2011) Recommendations for examining and interpreting funnel plot asymmetry in meta-analyses of randomised controlled trials. BMJ 343:d4002. https://doi.org/10.1136/bmj.d4002

43. Smiley CJ, Tracy SL, Abt E, Michalowicz BS, John MT, Gunsolley J, Cobb CM, Rossmann J, Harrel SK, Forrest JL, Hujoel PP, Noraian KW, Greenwell H, Frantsve-Hawley J, Estrich C (1939) Hanson N (2015) evidence-based clinical practice guideline on the nonsurgical treatment of chronic periodontitis by means of scaling and root planing with or without adjuncts. J Am Dent Assoc 146(7): 525–535. https://doi.org/10.1016/j.adaj.2015.01.026
44. Asparuhova MB, Kiryak D, Eliezer M, Mihov D, Sculean A (2018) Activity of two hyaluronan preparations on primary human oral fibroblasts. J Periodontal Res 54:33–45. https://doi.org/10.1111/jre.12602
45. Papapanou PN, Wennstrom JL (1991) The angular bony defect as indicator of further alveolar bone loss. J Clin Periodontol 18(5): 317–322
46. Ballini A, Cantore S, Capodiferro S, Grassi R (2009) Esterified hyaluronic acid and autologous bone in the surgical correction of the infra-bone defects. Int J Med Sci:6–71. https://doi.org/10.7150/ijms.6.65
47. Aslan M, Simsek G, Dayi E (2006) The effect of hyaluronic acid-supplemented bone graft in bone healing: experimental study in rabbits. J Biomater Appl 20(3):209–220. https://doi.org/10.1177/0885328206051047
48. Kim JJ, Song HY, Ben Amara H, Kyung-Rim K, Koo KT (2016) Hyaluronic acid improves bone formation in extraction sockets with chronic pathology: a pilot study in dogs. J Periodontol 87:1–13. https://doi.org/10.1902/jop.2016.150707
49. Aya KL, Stern R (2014) Hyaluronan in wound healing: rediscovering a major player. Wound Repair Regen 22(5):579–593. https://doi.org/10.1111/wrr.12214
50. Salbach J, Rachner TD, Rauner M, Hempel U, Anderegg U, Franz S, Simon JC, Hofbauer LC (2012) Regenerative potential of glycosaminoglycans for skin and bone. J Mol Med (Berl) 90(6):625–635. https://doi.org/10.1007/s00109-011-0843-2
51. Takeda K, Sakai N, Shiba H, Nagahara T, Fujita T, Kajiya M, Iwata T, Matsuda S, Kawahara K, Kawaguchi H, Kurihara H (2011) Characteristics of high-molecular-weight hyaluronic acid as a brain-derived neurotrophic factor scaffold in periodontal tissue regeneration. Tissue Eng A 17(7–8):955–967. https://doi.org/10.1089/ten.TEA.2010.0070
52. Laugisch O, Cosgarea R, Nikou G, Nikolidakis D, Donos N, Salvi GE, Stavropoulos A, Jepsen S, Sculean A (2019) Histologic evidence of periodontal regeneration in furcation defects: a systematic review. Clin Oral Investig 23(7):2861–2906. https://doi.org/10.1007/s00784-019-02964-3

Treatment of periodontal and peri-implant inflammation

Dr Vincenzo Iorio-Siciliano, Italy

Literature

The elimination of biofilm is the key factor in the treatment of periodontal and peri-implant inflammation. Periodontitis, peri-implant mucositis, and peri-implantitis represent bacterial inflammation with comparable symptoms. The clinical signs for all three are similar and include positive bleeding on probing, redness, oedematous tissue, suppuration and probing pocket depths of more than 4 mm. The cause of these similarly progressing infections is bacterial plaque, a biofilm rich of pathogenic bacteria. As a consequence, effective elimination of this biofilm is a fundamental prerequisite for the successful treatment of these diseases.

Treatment possibilities

Various methods (e.g. curettes, ultrasound, airflow) are available for the mechanical removal of biofilm. Complete elimination of the biofilm, however, is not always achievable by mechanical debridement alone.

PERISOLV® (REGEDENT) is a new antibacterial cleaning gel based on chloramines, which can be used in addition to mechanical cleaning in the treatment of periodontitis, peri-implant mucositis and peri-implantitis. The gel penetrates and softens the biofilm and, owing to its antiseptic properties, eliminates the pathogenic bacteria after only a few seconds.[1,2]

PERISOLV® is a two-component preparation consisting of a 0.95 % sodium hypochlorite (NaOCl) and an amino acid solution. Before use, the two components are mixed. The sodium hypochlorite and the amino acids form short-lived chloramines (N-carboxy anhydride, NCA) as antibacterial and anti-inflammatory active ingredients. PERISOLV® thus has an antimicrobial effect while also softening the concrements on the tooth or implant surface. This favours a less abrasive mechanical debridement of the root surface.[3]

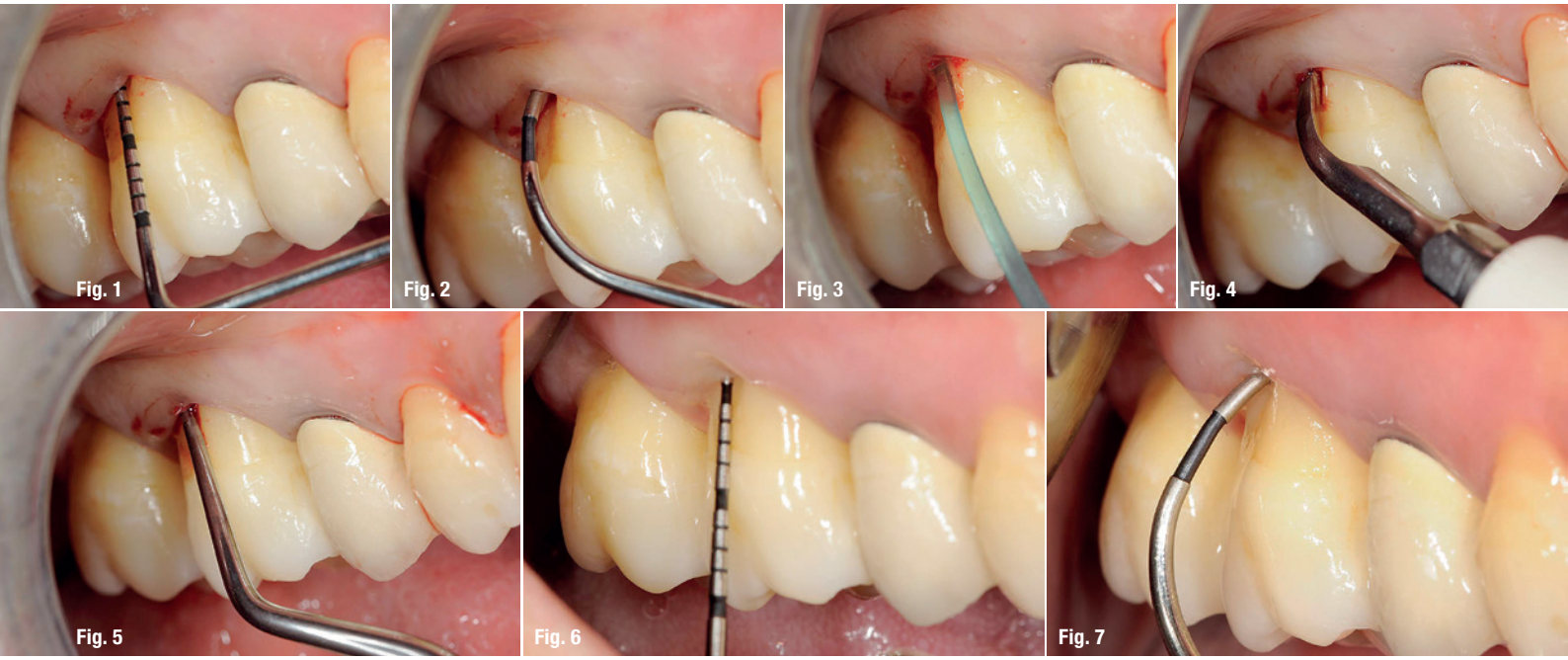

Fig. 1: A pocket depth of 5 mm with bleeding on probing was noted. **Fig. 2:** A Class II furcation defect was recorded. **Fig. 3:** PERISOLV® was applied into the furcation defect. **Fig. 4:** Subgingival scaling was performed. **Fig. 5:** Root planing was done. **Fig. 6:** A pocket depth of 4 mm at the buccal site was reported at the six-month follow-up. **Fig. 7:** The Class II furcation defect was reduced to a Class I furcation defect.

Chloramines are physiological compounds that play an essential role in the natural human immune system.[4–6] PERISOLV® thus has a pronounced antimicrobial activity[1] also against bacteria in biofilms on implant surfaces.[7] Its degranulating effect improves the efficiency of tooth root and implant surface cleaning (Figs. 1–7).[7–9]

Antimicrobial activity

The antimicrobial properties of NCA are well studied. NCA causes a significant inactivation of bacteria,[10–13] fungi,[12, 14, 15] viruses[16–18] and protozoa[19]. Even when exposed to sublethal concentrations of chloramines for pathogenic bacteria, a positive effect is observed. Chlorination of the bacterial cell membrane produces a postantibiotic effect (retardation of growth). As a result, bacterial inactivation is promoted by the body's immune system.[13, 20–22]

PERISOLV® shows significant antibacterial activity, which is pronounced even at rather low concentration.[2] It has further shown markedly higher inactivation rates than chlorhexidine and hydrogen peroxide for the periodontal pathogenic organisms *Porphyromonas gingivalis*, *Prevotella intermedia*, *Aggregatibacter actinomycetemcomitans* and *Fusobacterium nucleatum*. This superior effectiveness at low concentration is of great relevance for application in the tooth pocket. In this case, especially in periodontally infected pockets, a high sulcular fluid rate prevails, and this can cause rapid dilution of topically applied antiseptics/antibiotics.[23]

An *in vitro* study at the University of Bern in Switzerland has shown that the specific composition of the preparation increases the inactivation efficacy on an established biofilm compared with standard disinfectants.[1] In this study, the antimicrobial activity of PERISOLV®, its components and chlorhexidine was investigated on bacterial strains associated with periodontal disease. The effect of the antiseptics on individual bacteria and on an established biofilm consisting of six kinds of bacteria was examined. PERISOLV® showed a greater inactivation rate on the biofilm than the chlorhexidine solution did (Figs. 8–11).

The activity of PERISOLV® was found to be different for Gram-positive and Gram-negative bacteria. Gram-negative bacteria were inactivated even at a low PERISOLV® concentration. This selective inhibition could benefit Gram-positive bacteria, which have a greater association with periodontal health.[24] For example, if these bacteria are eliminated, their physiological role in the regulation of blood pressure could be disturbed.[25]

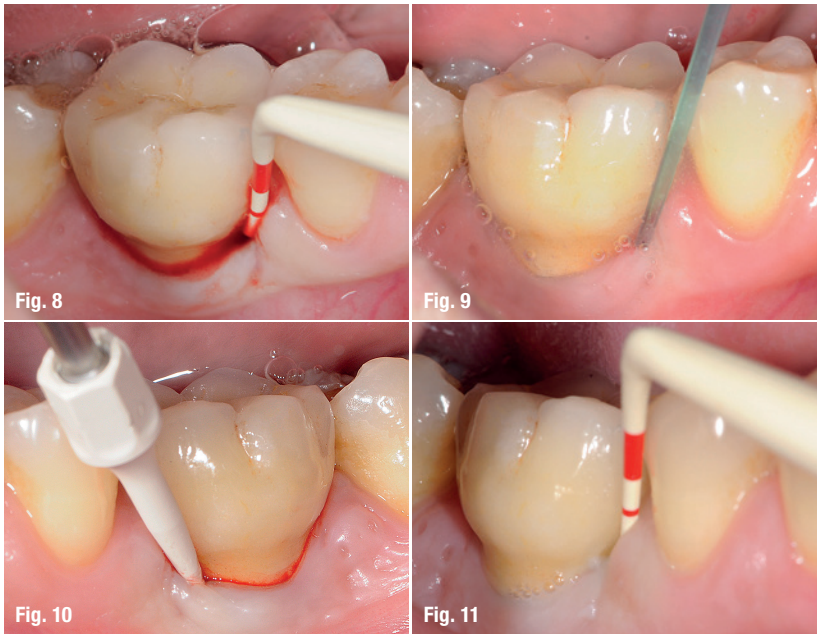

Fig. 8: Clinical situation of the peri-implant mucositis site. Implant with probing depth ≤ 5 mm and bleeding on probing. **Fig. 9:** Application of PERISOLV® before the non-surgical therapy. **Fig. 10:** After an exposure time of 30 seconds, the biofilm was removed non-surgically using an ultrasonic device with a PEEK tip. **Fig. 11:** Situation six months after therapy. Probing depth of ≤ 4 mm and no bleeding on probing.

Conclusion

The adjuvant use of PERISOLV® for the decontamination of inflamed periodontal and peri-implant sites is indicated because the slightly alkaline gel softens the extracellular matrix of the biofilm (proteins and polysaccharides), allowing better penetration by the chloramines, which effectively eliminate pathogens. In addition, the immediate inactivation effect of PERISOLV® could prevent bacteria from entering the blood stream during mechanical treatment.

All figures: © Vincenzo Iorio-Siciliano

about

Dr Vincenzo Iorio-Siciliano is a professor of periodontology at the University of Catanzaro, Italy, adjunct professor of periodontology and implantology at the University Federico II in Naples, Italy and also works as visiting scientist at the department of periodontology at the University of Bern, Switzerland.

contact

REGEDENT AG
Zollikerstr. 144
8008 Zurich, Switzerland
Tel.: +41 44 7003777
info@regedent.com
www.regedent.com

Clin Oral Invest
DOI 10.1007/s00784-016-1950-9

ORIGINAL ARTICLE

Effects of air polishing and an amino acid buffered hypochlorite solution to dentin surfaces and periodontal ligament cell survival, attachment, and spreading

Patrick R. Schmidlin[1,2] · Masako Fujioka-Kobayashi[3,4] · Heinz-Dieter Mueller[2] · Anton Sculean[5] · Adrian Lussi[2] · Richard J. Miron[2,6]

Received: 5 January 2016 / Accepted: 30 August 2016

Abstract
Objectives The aim of this study is to examine morphological changes of dentin surfaces following air polishing or amino acid buffered hypochlorite solution application and to assess their influence on periodontal ligament (PDL) cell survival, attachment, and spreading to dentin discs in vitro.
Materials and methods Bovine dentin discs were treated with either (i) Classic, (ii) Plus, or (iii) Perio powder (EMS). Furthermore, Perisolv® a hypochlorite solution buffered with various amino acids was investigated. Untreated dentin discs served as controls. Morphological changes to dentin discs were assessed using scanning electron microscopy (SEM). Human PDL cells were seeded onto the respectively treated discs, and samples were then investigated for PDL cell survival, attachment, and spreading using a live/dead assay, adhesion assay, and SEM imaging, respectively.
Results Both control and Perisolv®-rinsed dentin discs demonstrated smooth surfaces at low and high magnifications. The Classic powders demonstrated the thickest coating followed by the Powder Plus. The Perio powder demonstrated marked alterations of dentin discs by revealing the potential to open dentinal tubules even before rinsing. Seeding of PDL cells demonstrated an almost 100 % survival rate on all samples demonstrating very high biocompatibility for all materials. Significantly higher PDL cell numbers were observed on samples treated with the Perio powder and the Perisolv® solution (approximately 40 % more cells; $p < 0.05$). SEM imaging revealed the potential for PDL cells to attach and spread on all surfaces.
Conclusion The results from the present study demonstrate that cell survival and spreading of PDL cells on root surfaces is possible following either air polishing or application with Perisolv®. Future in vitro and animal testing is necessary to further characterize the beneficial effects of either system in a clinical setting.
Clinical relevance The use of air polishing or application with Perisolv amino acid buffered hypochlorite solution was effective in treating root surfaces and allowed for near 100 % PDL cell survival, attachment, and spreading onto all root surfaces.

Keywords Periodontal regeneration · Powder spraying · Air-Flow · Dentin discs · Dentinal tubules

✉ Richard J. Miron
rmiron@nova.edu

1 Clinic of Preventive Dentistry, Periodontology and Cariology, Center of Dental Medicine, University of Zurich, Zurich, Switzerland

2 Department of Preventive, Restorative and Pediatric Dentistry, School of Dental Medicine, University of Bern, Bern, Switzerland

3 Department of Cranio-Maxillofacial Surgery, Bern University Hospital, Inselspital, Bern, Switzerland

4 Department of Oral Surgery, Clinical Dentistry, Institute of Biomedical Sciences, Tokushima University Graduate School, Tokushima, Japan

5 Department of Periodontology, School of Dental Medicine, University of Bern, Bern, Switzerland

6 Department of Periodontology, College of Dental Medicine, Nova Southeastern University, Fort Lauderdale, FL, USA

Introduction

Periodontitis is a widespread inflammatory disease of the tooth-supporting soft and hard tissues, which is modulated by the host [1]. Biofilms are regarded as the primary etiologic factor for both disease initiation and progression [2]. Therefore, any cause-related periodontal therapy is based on the strict removal of the pathogenic microbial challenge and the successful prevention of their re-establishment [3].

Published online: 05 September 2016

Clinically, this is achieved traditionally by mechanical debridement using scalers, curettes, and/or ultrasonic instruments along with proper oral hygiene instructions [4, 5].

The preservation and creation of a biocompatible tooth surface during this periodontal therapeutic approach is crucial for successful tissue integration [6]. This is, however, particularly difficult when the surfaces display distinct morphological features, which are difficult to reach and to clean [7]. As a consequence, the overall aimed therapeutic goals are difficult to achieve and it is well documented that the deeper the initial periodontal lesions are, the less effective mechanical debridement may be [8–10].

A number of instruments have been developed and recommended over the years to assist clinicians in removing bacteria and their deposits in severely affected sites. Most of the classical mechanical instruments including curettes and ultrasonic instruments—despite being effective in hard deposit removal—often cause more excessive removal of cementum and/or dentin than is necessary [11]. Because past studies have documented that biofilm, rather than calculus, is the main culprit in triggering periodontal inflammation [12], other strategies of investigation include methods that eliminate or inactivate the purported periodontal pathogens in the biofilm. As a consequence, systemically and locally applied antibacterial agents (i.e., chemical agents) were used, which notably always bear the risk of bacterial resistance, tolerance, or other side effects [13]. Therefore, alternatives have been introduced to the market to serve as adjuncts during instrumentation in removing or—at least—reducing or modifying bacterial biofilms. The use of lasers and antimicrobial photodynamic therapy (tPDT) has also been the subject of much study recently [14, 15]. While the results of these studies have been inconclusive, the background theory of mechanism remains interesting: selective, light-induced elimination/reduction of microorganisms, with minimal damage to host tissues. As an alternative, but based on mechanical principles, glycine powders using small and soft amino acid particles have been developed for air abrasion, which can be applied in specially designed power jet devices directly on the root surfaces. They have become a real alternative with good clinical and microbiological outcomes and were shown to exhibit less abrasive effects on teeth as compared to hand or ultrasonic scaling or powder jet devices employing classical bicarbonate powder [16–21].

Another chemical line of investigation has recently opened up, with a new gel that was designed to detoxify and clean periodontal pockets. The active ingredients of this gel contain sodium hypochlorite (0.95 %) and amino acids (glutamic acid, leucine, lysine). Based on studies using a similar formulation for the removal of carious dentin lesions [22, 23], this further development now aims to extend the use of this gel mixture for subgingival use by disrupting bacterial biofilms and dissolving degenerated tissues [24]. These effects are purportedly achieved through the chemical reaction of sodium hypochlorite with the amino acids to form N-monochloroamino acids, which while capable of dissolving degenerated tissue, also minimize the detrimental effects of the hypochlorite on sound dentin and healthy soft tissues [25, 26].

Since the spraying of periodontal pockets using a variety of prophylactic powders has recently been introduced as a means to condition tooth root surfaces, little is known regarding its effect on alterations of root surface morphology or the potential cell repopulation thereafter. This also holds true for the application of the buffered hypochlorite gel. Because the regeneration of periodontal tissues relies on a biocompatible dentin surface with minimal surface alterations, the aim of the present study was to examine morphological changes of dentin surfaces following Air-Flow powder or gel application and to assess the influence on PDL cell survival, attachment, and spreading to dentin discs in vitro.

Materials and methods

Dentin disc preparation, cell source, and reagents

Bovine roots of freshly extracted teeth were separated from their crown and the approximate area was first ground flat and polished using water-cooled silicon carbide paper (Stuers, Erkrat, Germany) up to P4000 grit and discs with a diameter of 6.0 mm and a thickness of 1.5–1.6 mm to fit directly into 96-well in vitro culture plates. Dentin discs were prepared using a diamond-coated trephine under constant water-cooling. The discs were then stored in the dark in tap water at a temperature of 4 °C until the experiment started.

Air-Flow® powders (1) Classic, (2) Plus, and (3) Perio were kindly provided by Electro Medical Systems (EMS, Nyon, Switzerland). Perisolv®—composed of hypochlorite (NaOCl) solution buffered with different amino acids—was provided by Regedent (Zurich, Switzerland).

For dentin disc preparations, discs were air sprayed with each powder for 10 s per disc followed by 10 s of rinsing. Perisolv® dentin discs were rinsed with Perisolv® for 10 s followed by rinsing.

Primary human PDL cells were obtained from the middle third portion of three teeth extracted from healthy patients with no signs of periodontal disease extracted for orthodontic reasons as previously described [27, 28]. For ethical approval, informed written consent was obtained from all patients. Primary human PDL cells were detached from the tissue culture plastic using trypsin solution. Cells used for experimental seeding were from passages 4–6. Cells were cultured in a humidified atmosphere at 37 °C



Fig. 1 SEM images of control dentin slices at low (×100), medium (×400), and high (×1600) magnification. Smooth surfaces were observed at low magnifications with slight variations observed at high magnification (×1600)

in growth medium consisting of DMEM (Gibco, Life technologies, Carlsbad, CA), 10 % fetal bovine serum (FBS; Gibco), and 1 % antibiotics (Gibco). For in vitro experiments, cells were seeded with HA in 96-well culture plates at a density of 5000 cells per well for all experiments including cell attachment, cell survival (live/dead assay), and morphological variation as qualitatively assessed via SEM.

Scanning electron microscopy

Dentin discs from samples including (1) control, (2) Powder Classic, (3) Powder Plus, (4) Powder Perio, and (5) Perisolv® rinsing were fixed in 1 % glutaraldehyde and 1 % formaldehyde for 2 days for scanning electron microscopy (SEM). Following serial dehydration with ethanol,

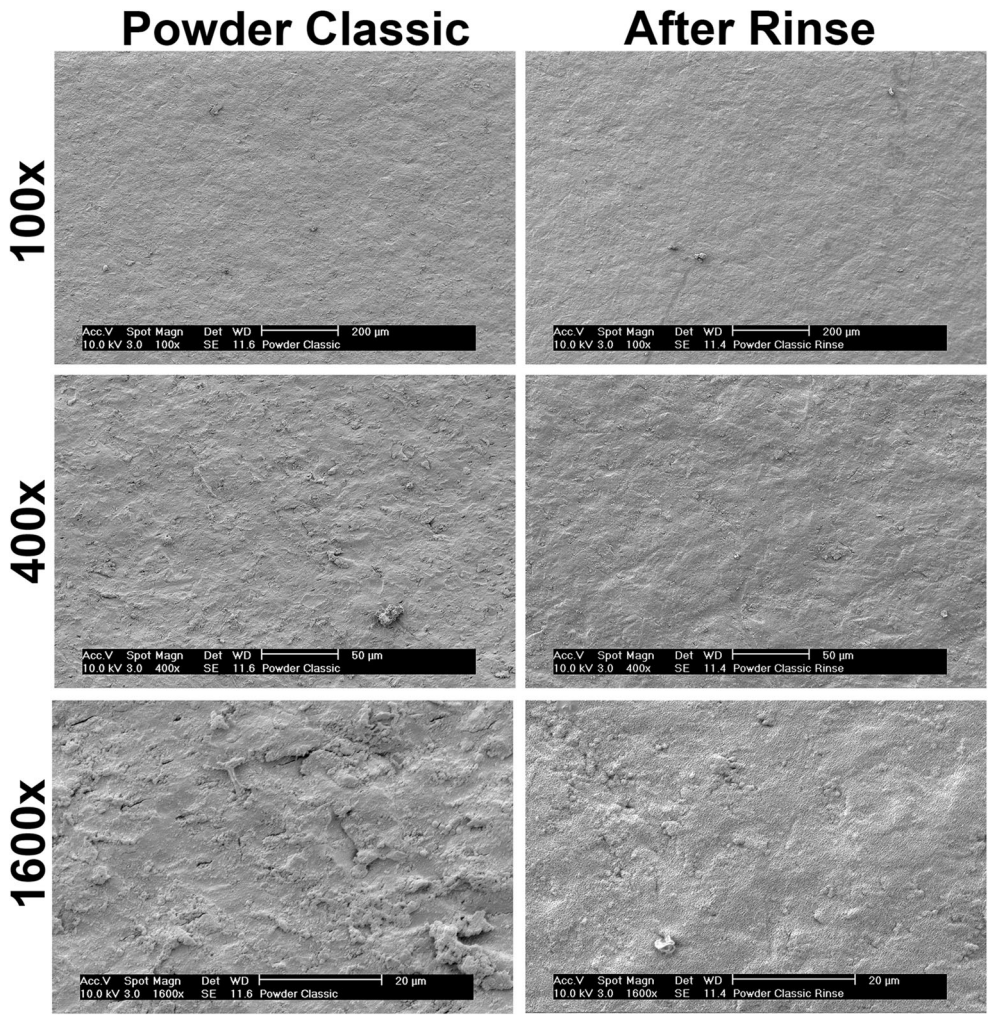

Fig. 2 SEM images of dentin discs Air-Flow sprayed for 10 s with Powder Classic before and after 10 s of rinsing with saline solution at various magnifications. A thin layer of collected powder was observed on dentin discs before and after rinsing



Fig. 3 SEM images of dentin discs Air-Flow sprayed for 10 s with Powder Plus before and after 10 s of rinsing with saline solution at various magnifications. Similarly to Powder Classic, a thin layer of powder was observed on dentin surfaces following spraying

samples were critical point dried (Type M.9202 Critical Point Dryer, Roth & Co. Hatfield, PA, USA) and allowed to dry overnight as previously described [29, 30]. The following day, samples were sputter-coated using a Balzers Union Sputtering Device (DCM-010, Balzers, Liechtenstein) with 10 nm of gold and analyzed microscopically using a Philips XL30 FEG scanning electron microscope to determine surface variations between samples. Furthermore, primary human PDL cells seeded onto dentin discs with each treatment modality were also investigated for PDL cell surface spreading in response to the various Air-Flow powders and Perisolv® rinsing.

Cell viability

Primary human PDL cells were seeded in 96-well plates at a density of 5000 cells per well onto dentin discs including (1) control, (2) Powder Classic, (3) Powder Plus, (4) Powder Perio, and (5) Perisolv®. PDL cells were evaluated using a live-dead staining assay according to the manufacturer's protocol (Enzo Life Sciences AG; Lausen, Switzerland) as previously described [31]. Experiments were performed in triplicate with three fluorescent images taken per experimental condition with a fluorescent microscope (OLYMPUS BX51, Tokyo, Japan).

Adhesion assay

Primary human PDL cells were seeded in 96-well plates at a density of 5000 cells per well onto dentin slices either (1) control, (2) Powder Classic, (3) Powder Plus, (4) Powder Perio, and (5) Perisolv®. PDL cells were quantified using fluorescent imaging (from live/dead assay) at 8 h for cell numbers as previously described [32]. At desired time point of 8 h, cells were washed with phosphate-buffered solution (PBS), fixed with 4 % formaldehyde solution



Fig. 4 SEM images of dentin discs Air-Flow sprayed for 10 s with Powder Perio before and after 10 s of rinsing with saline solution at various magnifications. Interestingly, Air-Flow spray with Powder Perio revealed the opening of dentinal tubules both before and after rinsing

(Grogg-Chemie AG, Stettlen, Switzerland) for 5 min, and mounted with VECTASHILD containing DAPI (Vector, Burlingame, CA). Fluorescent images were quantified with a fluorescent microscope. Experiments were performed in triplicate with five images captured per group. Data were analyzed for statistical significance using one-way analysis of variance with Tukey's test (*, p values <0.05 was considered significant).

Results

Surfaces characteristics of dentin slices with or without air polishing or Perisolv® rinsing

Morphological changes to dentin slices were first visualized using SEM imaging (Figs. 1, 2, 3, 4, and 5). First, uncoated control dentin slices demonstrated smooth surfaces at low magnification and demonstrated only slight irregularities at high magnification (Fig. 1). Thereafter, dentin discs were Air-Flow sprayed for 10 s with various powders and visualized before and after rinsing with saline (Figs. 2, 3, and 4). The Classic powder demonstrated the additional layer of powder following Air-Flow, and even after rinsing with saline, fine particles were still observed at high magnification (Fig. 2). A similar observation was observed for Powder Plus however to a lesser extent (Fig. 3). Following rinsing, the dentin surfaces revealed surfaces with many additional micro-rough patterns as a result from the Air-Flow spraying (Fig. 3). Interestingly, dentin discs that were sprayed with Powder Perio demonstrated very profound changes to dentin discs (Fig. 4). It was found that spraying surfaces with Powder Perio revealed the open of dentinal tubules both before and after rinsing (Fig. 4). Lastly, the use of Perisolv® rinsing did not affect surface morphology of dentin discs (Fig. 5).



Fig. 5 SEM images of dentin discs that were rinsed with Perisolv® for 10 s at various magnifications. No change in surface morphology was observed when compared to control dentin discs

PDL cell survival, attachment, and spreading

Each of the modifications to dentin discs was then investigated for their effect on PDL cell survival, attachment, and spreading of PDL cells (Figs. 6, 7, and 8). It was first observed that cell survival was near 100 % for all samples (Fig. 6, green cells label live cells versus red cells label dead cells). Thereafter, cell numbers were quantified using DAPI staining at 8 h to investigate the total number of attached cells following each of the treatment groups (Fig. 7). It was found that significantly more cells attached to dentin discs having been Air-Flow sprayed with Perio Powder or rinsed with Perisolv® (Fig. 7). Investigation of cell spreading and cell attachment via SEM imaging did not reveal any discernable differences between treatment groups at 8 h (Fig. 8).

Discussion

Successful periodontal regeneration requires adequate infection control and implies afterwards migration, adhesion, and proliferation of periodontal progenitor and mesenchymal stem cells located in the periodontal ligament [33, 34]. In this context, we focused on biological effects after modern non-destructive root surface cleaning procedures like air polishing or amino acid buffered hypochlorite solution application and determined their influence on PDL cell survival, attachment, and spreading to dentin discs in vitro. This study showed that the Classic and Plus powders demonstrated some coating effects, whereas the Perio powder opened the dentinal tubules even before rinsing. Seeding of PDL cells, however, showed an almost 100 % survival rate on all samples demonstrating very high biocompatibility for all materials despite the smear remnants. Nevertheless, significantly higher cell numbers were observed on samples treated with the Perio powder and the Perisolv® solution, which was corroborated by SEM.

A shortcoming of the present study was that treatments were performed on clean dentin surfaces and that the samples were polished. This comparative screening study, however, primarily focused on material-induced surface changes and the potential influence of the applied materials and their remnants. Therefore, we did not try to imitate the clinical situation in the first instance. Hägi and co-workers assessed air polishing with erythritol with and without chlorhexidine (Plus powder in this study) using a specially designed nozzle for subgingival application and showed that this treatment caused no substance loss and resulted in a smooth surface with nearly no residual biofilm, which also promoted the reattachment of PDL fibroblasts [35]. However, it must be noted that a onefold treatment of the specimens was not sufficient, and that the bacteria had to be additionally killed by UV. And still, the remaining bacterial compounds (e.g., lipopolysaccharides (LPS)) have interfered with PDL fibroblast orientation. In that study, only a fivefold treatment was, however, sufficient to enable a so-called contaminant free and biocompatible surface.

Schwarz and co-workers studied the influence of different air-abrasive powders, glycine, and sodium bicarbonate particles, on cell viability as well [36]. In contrast to the present study, contaminated titanium discs were studied and

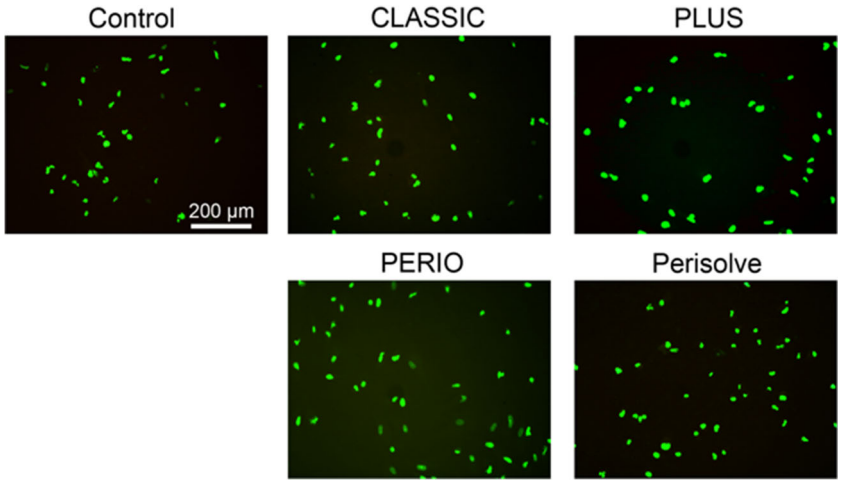

Fig. 6 Live/dead staining of primary human primary PDL cells on control, Powder Classic, Powder Plus, Powder Perio, and Perisolv® dentin discs. For cell viability, live-dead staining was done with viable cell appearing in *green* and dead cells in *red*. The results from these experiments demonstrated that all treatment modalities are highly biocompatible with little to no cell death observed. 13

osteoblastic osteosarcoma cell attachment was measured using a mitochondrial activity assay. Whereas both powders removed almost completely the biofilm, the luminescent cell viability test revealed better cell growth on samples treated with the Classic powder when compared to the Perio powder, which is in contrast to the present study and may be explained at least in part by the different substrates and methods used. The rough titanium surface may have been more efficiently cleaned by the sodium bicarbonate powder, which is characterized by harder particles of a bigger size, which may display an advantage when cleaning this kind of more complex surface structures [36]. On smooth dentin surfaces, in contrast, biofilms are to be removed, whereas the tooth surface preferably remains intact. With bicarbonate powder, considerable

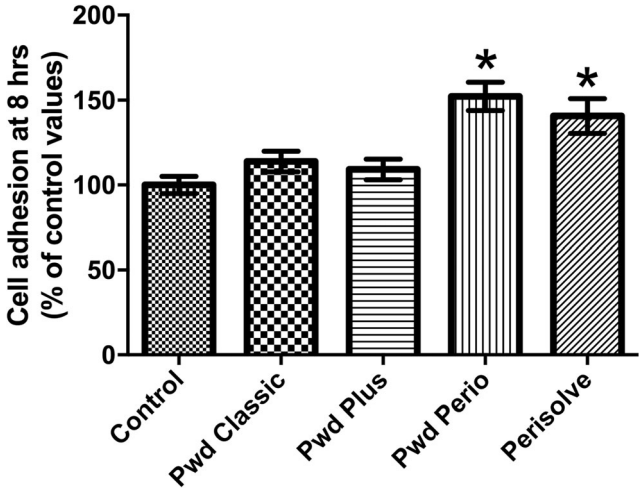

Fig. 7 Cell number of primary human PDL cells seeded on control, Powder Classic, Powder Plus, Powder Perio, and Perisolv® dentin discs. A significant increase in cell numbers was observed on Powder Perio and Perisolv® dentin discs when compared to control samples (*asterisk* denotes significant difference when compared to control samples, $p < 0.05$)

substance defects are associated even after short application times of 5 s, whereas glycine powder shows significantly less defect formation. The latter shows no detectable substance loss within the first 5 s [21] and only moderate superficial defects after 20 s of application time. Again, the laboratory condition may differ from the clinical situation in terms that cementum may cover the roots. Both tooth substances differ slightly in their chemical and histologic composition, i.e., that dentin is more mineralized, whereas cementum contains a bigger organic component and more water. This fact should also be taken into consideration when interpreting the current results. Cell attachment may vary as well on cementum. But to obtain samples with intact cementum is (i) difficult, and (ii) we used machined surfaces because this more reflects the clinical reality. However, flat surfaces had to be used under the current laboratory conditions to perform our experiments as planned. In addition, periodontally affected roots were pretreated in most cases. This inflicts partial removal of intact cementum and flattening in due course of the debridement procedures and the root material is abraded in order to ensure a clean and smooth surface. This is necessary—as mentioned above—to obtain a biocompatible surface. But atraumatic surface treatments are still warranted.

Based on studies using a similar formulation for the removal of carious dentin lesions, this further development of the gel mixture for use subgingivally has been reported in a case study treating 15 patients and a total of 158 residual pockets (non-responding sites persisting beyond the normal healing time of 6–12 months) [22, 23]. The manufacturer's claim is that the gel aids in hard deposit removal (reduced friction during instrumentation, softening of calculus), disruption of biofilm, and dissolving the generated tissue and therefore facilitating its removal from the periodontal pocket by scaling and root planning and aids in the healing process through its antibacterial properties [24].



Fig. 8 SEM images of primary human PDL cells seeded on control, Powder Classic, Powder Plus, Powder Perio, and Perisolv® dentin discs. No discernable differences could be observed with respect to cell shape or spreading following surface modifications between groups

Therefore, no harmful side effects have been reported in over its 15-year use for caries removal, and none are to be expected with its use in the treatment of periodontal pockets. However, laboratory or clinical data regarding the latter indication are still scarce. Therefore, this study was justified and the results corroborated some assumptions within the limitations of the present investigation. One other reported limitation of the present study was the time course investigation culturing primary human PDL cells onto dentin surfaces. While we report that all treatment modalities were able to re-establish periodontal cell repopulation, future investigation with longer time points is of interest to further determine the ability for each treatment modality to influence PDL cell proliferation and mineralization. Furthermore, numerous cell types are in contact with dentin/cementum surfaces including gingival fibroblasts and epithelial cells. Future research investigating the various cell types found in contact with dentin and cementum surfaces are needed to evaluate the potential of each air polishing or amino acid buffered hypochlorite solution technique on cell behavior of gingival fibroblasts and epithelial cells.

In summary, the present study demonstrated that cell survival and repopulation of root surfaces is possible following either air polishing or application with Perisolv®. Additional in vitro and animal testing is necessary to further characterize the beneficial effects of either system in clinical setting. Potential side effects when applying these techniques and materials should also be taken into consideration, when it comes to the opening of dentinal tubules and related consequences, especially when treating sensitive areas and patients.

Acknowledgments The authors thank Catherine Solioz for her careful technical assistance in helping with the experiments.

Compliance with ethical standards

Conflict of interest The authors declare that they have no conflicts of interest.

Funding This work was funded by Regedent who also supplied the HA carriers utilized in the present manuscript.

Ethical approval This article does not contain any studies with identifiable human participants or animals. An IRB was therefore not required.

Informed consent For this type of study, signed informed consent was obtained for PDL cell isolation.

References

1. Kornman KS, Page RC, Tonetti MS (2000) The host response to the microbial challenge in periodontitis: assembling the players. Periodontol 1997(14):33–53
2. Teughels W, Van Assche N, Sliepen I, Quirynen M (2006) Effect of material characteristics and/or surface topography on biofilm development. Clin Oral Implants Res 17(Suppl 2):68–81
3. Darby I (2009) Non-surgical management of periodontal disease. Aust Dent J 54(Suppl 1):S86–S95
4. Greenstein G (2000) Nonsurgical periodontal therapy in 2000: a literature review. Journal of the American Dental Association (1939) 131:1580–1592
5. Sanz M, Teughels W (2008) Innovations in non-surgical periodontal therapy: consensus report of the sixth European workshop on periodontology. J Clin Periodontol 35:3–7
6. Blomlof J, Jansson L, Blomlof L, Lindskog S (1996) Root surface etching at neutral pH promotes periodontal healing. J Clin Periodontol 23:50–55
7. Schmidlin PR, Hauri D, Krahenmann MA, Puhan MA, Attin T. [Residual pocket depth after periodontal regenerative procedures. Clinical relevance and interpretation of meta-analyses data]. Schweizer Monatsschrift fur Zahnmedizin = Revue mensuelle suisse d'odonto-stomatologie = Rivista mensile svizzera di odontologia e stomatologia/SSO. 2009;119:224–31.
8. Rabbani GM, Ash MM Jr, Caffesse RG (1981) The effectiveness of subgingival scaling and root planing in calculus removal. J Periodontol 52:119–123
9. Sherman PR, Hutchens LH Jr, Jewson LG, Moriarty JM, Greco GW, McFall WT Jr (1990) The effectiveness of subgingival scaling and root planning. I. Clinical detection of residual calculus. J Periodontol 61:3–8
10. Sherman PR, Hutchens LH Jr, Jewson LG (1990) The effectiveness of subgingival scaling and root planing. II. Clinical responses related to residual calculus. J Periodontol 61:9–15
11. Schmidlin PR, Beuchat M, Busslinger A, Lehmann B, Lutz F (2001) Tooth substance loss resulting from mechanical, sonic and ultrasonic root instrumentation assessed by liquid scintillation. J Clin Periodontol 28:1058–1066
12. Hajishengallis G (2015) Periodontitis: from microbial immune subversion to systemic inflammation. Nat Rev Immunol 15:30–44
13. Ciancio SG. Antiseptics and antibiotics as chemotherapeutic agents for periodontitis management. Compendium of continuing education in dentistry (Jamesburg, NJ: 1995). 2000;21:59–62, 4, 6 passim; quiz 78.
14. Chondros P, Nikolidakis D, Christodoulides N, Rossler R, Gutknecht N, Sculean A (2009) Photodynamic therapy as adjunct to non-surgical periodontal treatment in patients on periodontal maintenance: a randomized controlled clinical trial. Lasers Med Sci 24:681–688
15. Aoki A, Mizutani K, Schwarz F, Sculean A, Yukna RA, Takasaki AA, et al. (2000) Periodontal and peri-implant wound healing following laser therapy. Periodontol 2015(68):217–269
16. Petersilka GJ, Bell M, Haberlein I, Mehl A, Hickel R, Flemmig TF (2003) In vitro evaluation of novel low abrasive air polishing powders. J Clin Periodontol 30:9–13
17. Petersilka GJ, Bell M, Mehl A, Hickel R, Flemmig TF (2003) Root defects following air polishing. J Clin Periodontol 30:165–170
18. Petersilka GJ, Steinmann D, Haberlein I, Heinecke A, Flemmig TF (2003) Subgingival plaque removal in buccal and lingual sites using a novel low abrasive air-polishing powder. J Clin Periodontol 30: 328–333
19. Petersilka GJ, Tunkel J, Barakos K, Heinecke A, Haberlein I, Flemmig TF (2003) Subgingival plaque removal at interdental sites using a low-abrasive air polishing powder. J Periodontol 74:307–311
20. Moene R, Decaillet F, Andersen E, Mombelli A (2010) Subgingival plaque removal using a new air-polishing device. J Periodontol 81: 79–88
21. Sahrmann P, Ronay V, Schmidlin PR, Attin T, Paque F (2014) Three-dimensional defect evaluation of air polishing on extracted human roots. J Periodontol 85:1107–1114
22. Nadanovsky P, Cohen Carneiro F, de Mello F S (2001) Removal of caries using only hand instruments: a comparison of mechanical and chemo-mechanical methods. Caries Res 35:384–389
23. Marcinkiewicz J, Kontny E (2014) Taurine and inflammatory diseases. Amino Acids 46:7–20
24. Draghincescu RI. In vitro antibacterial effect of the Carisolv®-2 system. 2004.
25. Hosoya Y, Shinkawa H, Marshall GW (2005) Influence of Carisolv on resin adhesion for two different adhesive systems to sound human primary dentin and young permanent dentin. J Dent 33: 283–291
26. Beeley JA, Yip HK, Stevenson AG (2000) Chemochemical caries removal: a review of the techniques and latest developments. Br Dent J 188:427–430
27. Miron RJ, Bosshardt DD, Hedbom E, Zhang Y, Haenni B, Buser D, et al. (2012) Adsorption of enamel matrix proteins to a bovine-derived bone grafting material and its regulation of cell adhesion, proliferation, and differentiation. J Periodontol 83:936–947
28. Miron RJ, Caluseru OM, Guillemette V, Zhang Y, Gemperli AC, Chandad F, et al. (2013) Influence of enamel matrix derivative on cells at different maturation stages of differentiation. PLoS One 8: e71008
29. Miron RJ, Gruber R, Hedbom E, Saulacic N, Zhang Y, Sculean A, et al. (2013) Impact of bone harvesting techniques on cell viability and the release of growth factors of autografts. Clin Implant Dent Relat Res 15:481–489
30. Miron RJ, Hedbom E, Saulacic N, Zhang Y, Sculean A, Bosshardt DD, et al. (2011) Osteogenic potential of autogenous bone grafts harvested with four different surgical techniques. J Dent Res 90: 1428–1433
31. Sawada K, Caballe-Serrano J, Bosshardt DD, Schaller B, Miron RJ, Buser D, et al. Antiseptic solutions modulate the paracrine-like activity of bone chips: differential impact of chlorhexidine and sodium hypochlorite. J Clin Periodontol. 2015.
32. Miron RJ, Oates CJ, Molenberg A, Dard M, Hamilton DW (2010) The effect of enamel matrix proteins on the spreading, proliferation

and differentiation of osteoblasts cultured on titanium surfaces. Biomaterials 31:449–460
33. Nyman S, Lindhe J, Karring T, Rylander H (1982) New attachment following surgical treatment of human periodontal disease. J Clin Periodontol 9:290–296
34. Melcher AH (1976) On the repair potential of periodontal tissues. J Periodontol 47:256–260
35. Hagi TT, Klemensberger S, Bereiter R, Nietzsche S, Cosgarea R, Flury S, et al. (2015) A biofilm pocket model to evaluate different non-surgical periodontal treatment modalities in terms of biofilm removal and reformation. Surface Alterations and Attachment of Periodontal Ligament Fibroblasts PLoS One 10:e0131056
36. Schwarz F, Ferrari D, Popovski K, Hartig B, Becker J (2009) Influence of different air-abrasive powders on cell viability at biologically contaminated titanium dental implants surfaces. J Biomed Mater Res B Appl Biomater 88: 83–91

Basic evaluation of an antimicrobial gel for peri-implantitis treatment

Authors: Dr Georg Bach & Christian Müller, Germany

Introduction

Early complications, which have been regarded as the major dread in the initial phase of oral implantology, have become a rare phenomenon for a fairly long time. Reasons for this positive development can be found in significant improvements of the implant surfaces, improved insertion techniques as well as in new ways to improve the prospective implant site.

Nevertheless, with the enormously increased number of inserted implants, a significant increase of late complications has meanwhile been recorded.[1,4,12] These complications typically manifest themselves many years after installation of the superstructure by means of peri-implant bone loss around artificial tooth pillars.[17,20,21,25] Often associated with an insufficient or declining oral hygiene of the patient, these peri-implant lesions lead to the loss of the artificial tooth pillar and the corresponding suprastructure in case they are not treated.[5,11,13,14] Many authors regard the development of peri-implantitis therapies as one of the current key challenges of implantology.[15,18-20,26]

Cleaning and disinfection of the exposed implant areas represents an undeniable requirement. For the latter step the term "decontamination" has been generally established.[3,16] For decontamination, various methods are indicated for their suitability.[3,6,8,16,21-24] The aim of this study was to evaluate the suitability of using an antimicrobial gel for peri-implantitis treatment in an *in-vitro* experiment.

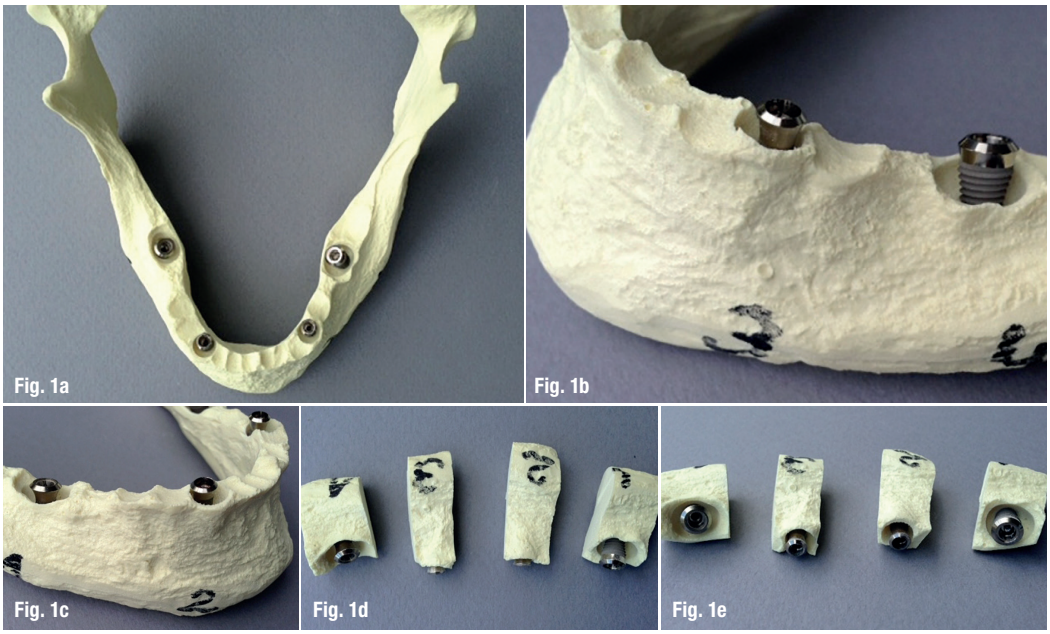

Figs. 1a–e: Peri-implant defect—Simulated model: Crater-shaped defects were prepared in plastic jaws typically used for insertion exercises. Brand-new implants were placed in the middle of these defects in a way that at least three threads were exposed **(a–c)**. The jaws were divided into smaller units **(d & e)** and autoclaved before conducting phase II examinations (bacterial cultivation—Perisolv application—Microbiological diagnostics etc.) in order to allow better fit into the furnace as well as in vials containing culture medium.



Figs. 2a–f: SEM analysis: Brand-new, sterile implants were inoculated and incubated with a microbial suspension. **Figure 2a** shows a scanning electron micrograph of this starting material. **Figure 2b** shows the bacterial turf on an implant thus processed. After Perisolv application, many areas showed a detached bacterial coating, the implant surface is virtually free from bacterial turf **(c & d)**. These "exposed spots" feature an unchanged implant structure **(e & f)**, therefore Perisolv application does not alter the implant surface per se.

Material and Methods

Two test phases were performed:

a) Phase I: Decontamination procedure of brand-new sterile implants, which have been inoculated with bacteria and subsequently coated with antimicrobial gel.

b) Phase II: Decontamination procedure of brand-new sterile implants placed in a plastic jaw with simulated bone defects after subsequent inoculation with bacteria and final exposure to antimicrobial gel.

Phase I: Decontamination procedure to implants inoculated with bacteria

To evaluate general suitability of the decontamination process, brand-new ITI implants (Institut Straumann AG, Basel, Switzerland) were microbiologically processed and analysed at the Institute for Medical Diagnostics Bioscientia (Freiburg, Germany).

Implant contamination—microbial procedure:

The implants were exposed and inoculated with a bacterial suspension (overnight cultures of *MRSA ATCC 33591*):

By means of sterile forceps, the implants were placed in 10 ml peptone yeast extract broth each. The tubes were incubated for 48 h at 36 °C and 5–10 % CO_2. After 48 h of incubation, the liquid was removed by means of vacuum filtration and the implant was transferred back to the initial container with sterile forceps for immediate further processing. Exclusively, implants with a medium bacterial growth were used for further examinations, implants with low or very low bacterial growth were excluded. Two test series were conducted with four implants each.

Decontamination procedure with contaminated whole implant bodies:

After completion of the microbiological work, three out of four implants were confronted with antimicrobial gel for two min in the sense of a decontamination procedure and immediately transferred to the Institute for microbiological analysis. One implant served as positive control, without conduction of the decontamination procedure.

- Antimicrobial Gel: An antimicrobial gel known for its application in periodontology was used (PERISOLV, REGEDENT AG, Zurich, Switzerland). It is typically used for adjuvant cleaning and decontamination of the outer tooth root area and the surrounding tissue.[10] Furthermore, in the literature the gel is described to feature a softening effect towards degenerative tissue before debridement of periodontal pockets.[9] According to the manufacturer, the gel does not affect healthy tissue[9] and, however, features an antimicrobial effect.[2,7]
- Gel composition: The gel contains amino acids (glutamic acid, leucine and lysine), carboxymethyl cellulose, titanium dioxide as well as ultra pure water and features a pH value below 10. The transparent liquid represents a 0.95 % sodium hypochlorite solution and is admixed immediately before the application. After mixing hypochlorite and amino acids, so-called Chloramines (NCA), a short-lived active substance class, are formed. These substances are part of the body's own immune system.[9]
- Gel Preparation: The set (gel and liquid) is stored in the refrigerator. One hour prior to planned application, the set is removed from the refrigerator to allow the contents of the kit to warm up to room temperature. Both components (gel and liquid) are arranged in separate syringes and are connected by means of screwing (Luer-lock connection). Both components were thoroughly mixed by moving the stamps back and forth 10–15 times. The activated and operational gel was finally left in the transparent syringe. A non-invasive/blunt application tip is attached and the implants are coated with the gel.

Table 1: Results of Phase I.

	Bacterial growth on implant	Implant 1	Implant 2	Implant 3	Implant 4 control
A:	MRSA	–	–	–	+ + +
B:	MRSA	–	+	–	+ + +

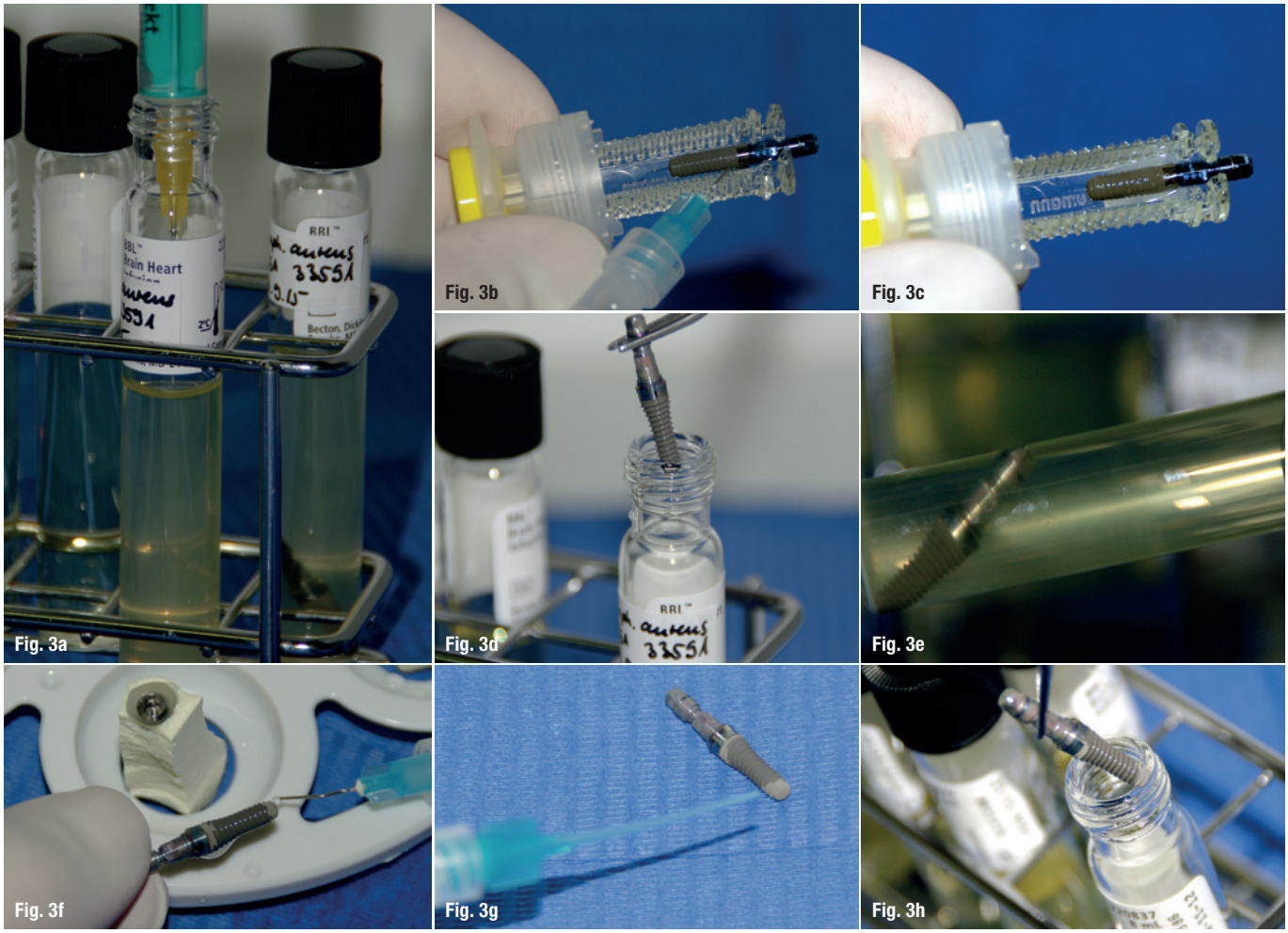

Figs. 3a–h: Phase I: Brand-new, sterile implants were used for the study. Implants supposed for SEM evaluation were initially kept in their original containers. The MRSA bacterial suspension was drawn in a sterile, disposable syringe **(a)** and applied directly on the respective implant in its original container **(b & c)**. Subsequently, the shipment for immediate SEM analysis was carried out. Implants supposed for microbiological testing were removed from their containers and placed directly into the MRSA bacterial suspension **(d & e)**. After a one-minute inoculation period, the implants were removed and coated with Perisolv gel **(f & g)**. After the exposure time specified by the manufacturer, the implants were introduced into the tube containing the nutrient medium and sent to the microbiological examination **(h)**.

Implant preparation for microbial investigations

Immediately after application of the gel, the implants were introduced into tubes with a sterile nutrient solution and sent to the Institute for microbiological analysis. The samples were processed in the Microbiological Institute by means of conventional (plate) cultivation.

Scanning electron microscopic studies of the implants

Some of the implants were investigated by scanning electron microscopy (Institut Straumann AG).

Results of Phase I—Decontamination procedure with contaminated whole implant bodies (Tab. 1)

Scanning electron microscopic studies

In some areas, where Perisolv had been applied, the "bacterial turf" on the implants was interrupted or rather dissolved/removed. Underlying areas, freed from bacterial turf, displayed an intact, unaltered implant structure. For implants only confronted with Perisolv without previous inoculation, no gel-induced change of the implant surface were observed. In summary, SEM analysis after treatment with the gel revealed no change of implant surface as and a partial dissolution of the inoculated bacterial layer.

Microbiology

Phase I investigations revealed bacterial inactivation in the highest degree, remaining MRSA bacteria were detected in one test item of series B1 only.

Summary of Phase I—Decontamination procedure with contaminated whole implant bodies

The investigated gel is capable to induce a pronounced destruction of pathological bacteria present on implant surfaces without altering this implant surface structure.

Phase II: Testing the effect of the antimicrobial gel on contaminated implants placed in a plastic jaw with a simulated peri-implant tissue defect

After the first test phase to evaluate the principle suitability of the gel application, a second test phase was conducted.

Table 2: Results of Phase II.

	Bacterial DNA in simulated bone defect	Unit 1	Unit 2	Unit 3	Unit 4 Control
A:	MRSA	++	+	++	+++
B:	MRSA	–	++	+	+++

Preparation of simulated peri-implant defects

Implants (Institut Straumann AG) were placed in a plastic jaw, which was prepared with standardised crater-shaped (peri-implant) defects prior to implant placement. The implants were placed in the centre of these defects by means of allowing the upper three threads not to be sunk into the plastic. Thus, a defect situation simulating a typical manifested peri-implantitis was generated. For better further processing, the jaws were sawed into small implant/plastic jaw units. These implant/plastic jaw units were steam sterilised (autoclaved).

Implant contamination

Afterwards, the exposed implant surfaces were contaminated with a bacterial suspension. The circumferential defects were completely filled with the bacterial suspension as well. Two test series were conducted with four implant/plastic jaw units each.

Microbiological procedure:

The bacterial suspension (*MRSA ATCC 33591*–ATCP strain) was prepared and suspended in BHI broth. The bacterial count of this "stock suspension" represented approx. 10^8–10^9 bacteria/mL. To inoculate the implant/plastic jaw units, each 100 µl of the cultured MRSA stock suspension were pipetted into one simulated bone defect. This corresponds to approx. 10^7–10^8 bacteria/100 µl respectively.

Decontamination procedure with simulated peri-implant defects

Perisolv gel was administered into three of four simulated bone defects (details s. Chapter "Phase I"). The gel was allowed to operate for two minutes. One implant/plastic jaw unit served as a positive control, where no decontamination was performed.

Implant preparation for microbial investigations

The units were subsequently placed into 10 mL of BHI broth (Brain Heart Infusion Glucose), each by means of a sterile forceps. The implant/plastic jaw units were placed in a culture oven. To establish a humid environment, a small Erlenmeyer flask filled with sterile distilled water was added into the pot. The units were incubated under aerobic conditions at 36 °C.

After two days of incubation, the simulated bone defect of unit 1 was dry, whereas bone defects of units 2–6 were still slightly humid. The remaining liquid from these units was removed by means of a pipet.

The implant/plastic jaw units were introduced in tubes with a sterile nutrient solution and forwarded to the Institute Bioscentia for microbiological analysis. The samples were processed by means of conventional (plate) cultivation.

Results of Phase II (table 2)

Remaining MRSA bacteria were detected in five of six decontaminated implant/plastic jaw units as well as in the control unit. This finding can be categorised as "significant" in three out of five units and as "distinct" in the other two out of five units. In addition, a bacillus species was detected in one unit. This can be regarded as an environmental contaminant.

Figs. 4a–i: Phase II: Brand-new, sterile implants were placed in simulated bone defects in a plastic jaw. These implant/plastic jaw units were autoclaved. Afterwards, a MRSA solution was introduced into the simulated peri-implantitis defects **(a–c)**. Afterwards, the units were incubated in a special oven and a proof for the presence of "massive" MRSA bacteria was performed. At this time, the Perisolv gel was applied **(d–f)**. After the exposure time specified by the manufacturer, the samples were placed directly into a BHI broth **(g & h)** and the samples were passed for further microbiological examination **(i)**.


Fig. 4a


Fig. 4b


Fig. 4c


Fig. 4d

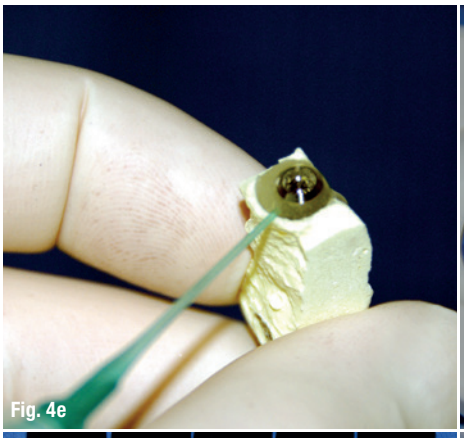
Fig. 4e


Fig. 4f

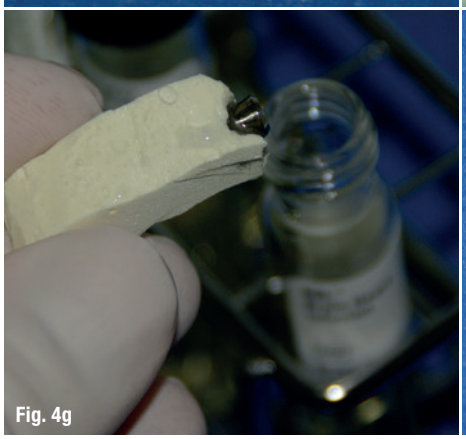
Fig. 4g


Fig. 4h


Fig. 4i

Breeding trial after decontamination

It was possible to recultivate bacteria sporadically after decontamination and simple drying.

Preliminary Summary

Compared to other decontamination procedures, the application of the antimicrobial gel Perisolv achieved satisfactory decontamination results from a microbiological point of view in both *in-vitro* study phases. In all samples, a significant reduction of the bacterial count was observed. However, a bacterial elimination only was achieved in the first study phase, but not in the second phase.

SEM images of the implants that have undergone the procedure described above, pointed out that the antimicrobial gel did not induce any changes to the implant surface and that it has certain potency for dissolving the (inoculated) bacterial turf.

As a limitation to the evaluated results, it should be clearly stated that the presented investigation was performed in an *in-vitro* environment with a "non-human milieu" and without a real inflammatory component. Thus, our results about the basic applicability of the presented method can be regarded as a first approach, but in no case a clear statement about the definitive decontamination efficacy of the tested methods can be done.

Acknowledgement

In particular, we want to thank Dr Brodner (Institute Bioscientia, Freiburg, Germany) and Institut Straumann AG (Basel, Switzerland) for their valuable support in the microbiological testing phase and in the preparation of scanning electron images. We want to thank Straumann Germany GmbH for providing the plastic jaws and the implants. Without their elaborate and valuable work, this study would not have been possible._

Contact

Dr Georg Bach
Rathausgasse 36
79098 Freiburg im Breisgau
Germany
doc.bach@t-online.de
www.herrmann-bach.de